



PATIENT PRESENTING CLINICAL SIGNS

Tori Nel History of vomiting last few days 2/6 murmur found on exam Ab scan 53 images Echo 51 images 104 total Ab scan Jejunum thickened muscularis layer and submucosal layer, no obvious lymphadenopathy. Bladder some hyperechoic flecks in lumen Pancreas hypoechoic patch in body and proximal left limb Suspect IBD food intolerance and chronic pancreatitis

Feline

Abnormal PE/Chem/CBC/UA Results: Non diagnostic. T 4 normal

BREED

ULTRASONOGRAPHIC EXAMINATION OF THE HEART & ABDOMEN

Sphynx

SEX

Spayed Female

AGE

11

WEIGHT

4 kg

INTERPRETED BY

Eric Lindquist, DMV

DABVP, Cert. IVUSS

FELINE CARDIAC PARAMETERS	BODY WEIGHT (kg)	HR (BPM)	IVSd (cm)	LVIDd (cm)	LVWd (cm)	FS (%)	EF (%)
NORMAL PARAMETER	-----	150-240	0.3-0.6	1.0-2.1	0.25-0.6	35-67	80-100
PATIENT		176	0.54	0.9	0.7	70	96
FELINE CARDIAC PARAMETERS	LA/AO (Boon)	LA/AO HEART BASE (Sisson)	LA 2D 4-chamber long axis AS to FW (Sisson) (cm)	LVOT VEL. (m/s)	RVOT VEL. (m/s)	IVRT (m/)	
NORMAL PARAMETER	<1.5	0.88-1.79	0.7-1.7	<1.6	<1.3	40-60	
PATIENT		1.2	1.6		1.21	NM	
Adapted from June Boon, Veterinary Echocardiography, 1998 Sisson D et al. JVIM 1991; 5: 232, Jacobs et al. Am J Vet Res 1985; 46:1705							

IMAGING PERFORMED BY

Dr. Belan

HOSPITAL NAME

Alpine 24/7 AH

REFERRING VET

Dr. Kyono

INVOICE

44252

DATE

7/21/23

EPSS = 0.1

Cardiac Presentation

The echocardiogram in this patient demonstrated normal **left atrial** size based on 3 separate LA measurements. The **mitral** valve was mildly thickened. Apposition was adequate. Mild amount of **left ventricular** remodeling noted in this patient, yet contractility and thicknesses were adequate and not alarming. The **left ventricular outflow** tract demonstrated normal laminar flow and subjective structural integrity. The **right atrium** and auricle revealed normal size, structure and content. No evidence of masses was noted or chamber overload. **Tricuspid** valvular assessment demonstrated adequate linear morphology and kinetics. The **right ventricle** was of normal size (1/3 diameter of LV), chordae structure, myocardial echogenicity and thickness. **Pulmonic** tract assessment revealed normal valve structure, laminar flow, and diameter (approx. 1:1 pa/ao ratio). No visible **pericardial** or free pleura fluid was noted or extra cardiac pathology in the visible planes. The cranial **mediastinum and pericardial regions** were free of masses in the visible window.



PATIENT *Urinary System*

Tori Nel The **urinary bladder**, trigone, and pelvic urethra presented normal thicknesses and normal tone. The ureters were not visible which is normal. No uroliths or sediment were visualized and anechoic urine was present. No evidence of inflammatory or neoplastic changes were noted. Ureteral papillae were normal.

SPECIES

Feline

The **kidneys** revealed normal size and structure, corticomedullary definition and ratio for this age. The cortices presented largely uniform texture with normal echogenic relationship to liver and spleen. Medullary structure differed distinctly from the cortex and no evidence of pelvic dilation was present.

BREED

Sphynx

The capsules were acceptably uniform without significant irregularities. The right kidney measured 3.6 cm. The left kidney measured 3.63 cm.

SEX

Spayed Female

Adrenal Glands

Both **adrenal glands** were visualized and recognized as having normal shape, size, position and echogenicity for this breed. The phrenic vasculature, glandular echogenicity and detail were unremarkable. Capsule, cortex, and medullary definition were normal for this age patient. The right adrenal gland measured 0.48 cm. The left adrenal gland measured 0.43 cm.

AGE

11

WEIGHT

4 kg

Spleen

The **spleen** measured 0.86 cm in width and was folded upon itself caudally. It presented a smooth homogeneous parenchyma hyperechoic to liver and renal cortical parenchyma. The capsule was smooth without noticeable expansion or deviation from within the spleen or adjacent pathology. The splenic vasculature demonstrated normal volume without signs of congestion or thrombosis. No sonographic evidence of acute or chronic inflammatory, neoplastic, or infarctual changes were noted.

INTERPRETED BY

Eric Lindquist, DMV

DABVP, Cert. IVUSS

Liver

The **liver** images submitted revealed subjectively normal liver size, contour, and structure. Parenchymal echogenicity was naturally coarse and hypoechoic to the spleen. Vascular and biliary tracts were of normal volume with no evidence of congestion. The gallbladder presented acceptably thin walls with primarily anechoic content. The cystic and common bile ducts were normal. No pathological hepatic lymphadenopathy was evident. No overt structural evidence of inflammatory, infiltrative or regenerative pathology was evident.

IMAGING PERFORMED BY

Dr. Belan

HOSPITAL NAME

Alpine 24/7 AH

Gastrointestinal

REFERRING VET

Dr. Kyono

The **gastrointestinal** presentation revealed mild uniform prominence of the gastric mucosa as well as areas of "ropey" small intestinal wall with slight disruption of the normal 1:3 muscularis/mucosal ratio. The intestinal submucosa was slightly irregular, thickened and hyperechoic suggestive of low grade, chronic disease. No concerning lymphadenopathy was visible. No evidence of obstruction was present. Chronic inflammatory bowel disease is likely with a low possibility of an early neoplastic event such as lymphoma. Full thickness tissue biopsies via open laparotomy, ideally guided by intraoperative ultrasound in order to obtain the most representative mural sample, would be necessary to rule out this possibility.

INVOICE

44252

DATE

7/21/23

Pancreas

The base and limbs of the **pancreas** were observed to be largely isoechoic to surrounding omental fat. Some parenchymal remodeling, however, with mild deviation from curvilinear normalcy was observed.



PATIENT

Tori Nel

Pancreatic duct and capsular irregularities were present consistent with age related changes. If pain upon imaging (+ Murphy sign) was present or if the patient is focally painful in subxyphoid palpation then low-grade smoldering chronic pancreatitis should be suspected.

SPECIES

Feline

ULTRASONOGRAPHIC FINDINGS

BREED

Sphynx

- Minor diffuse intestinal thickening – inflammatory bowel type present.
- Prominent pancreatitis, history of pancreatitis likely
- Essentially normal echocardiogram with myocardial remodeling, no evidence of significant disease

SEX

Spayed Female

INTERPRETATION OF THE FINDINGS & FURTHER RECOMMENDATIONS

No neoplastic criteria met. Subxyphoid palpation is recommended to assess for pain or discomfort associated with the pancreas.

AGE

11

Likely flow murmur. Flow murmurs can be caused by volume shifts, anemia, excitable/tachycardic state, DRVOTO (Dynamic Right Ventricular Outflow Obstruction), or even simple stethoscope pressure upon clinical exam. These flow murmurs are typically benign and may develop often later in life theoretically owing to age related clinically insignificant changes of the heart. If the patient is recently clinical for anorexia, weight loss or metabolic disturbances, an abdominal sonogram and full workup may be appropriate to assess underlying clinical systemic causes of a newly developed flow murmur.

WEIGHT

4 kg

INTERPRETED BY

Eric Lindquist, DMV
DABVP, Cert. IVUSS

IMAGING PERFORMED BY

Dr. Belan

HOSPITAL NAME

Alpine 24/7 AH

REFERRING VET

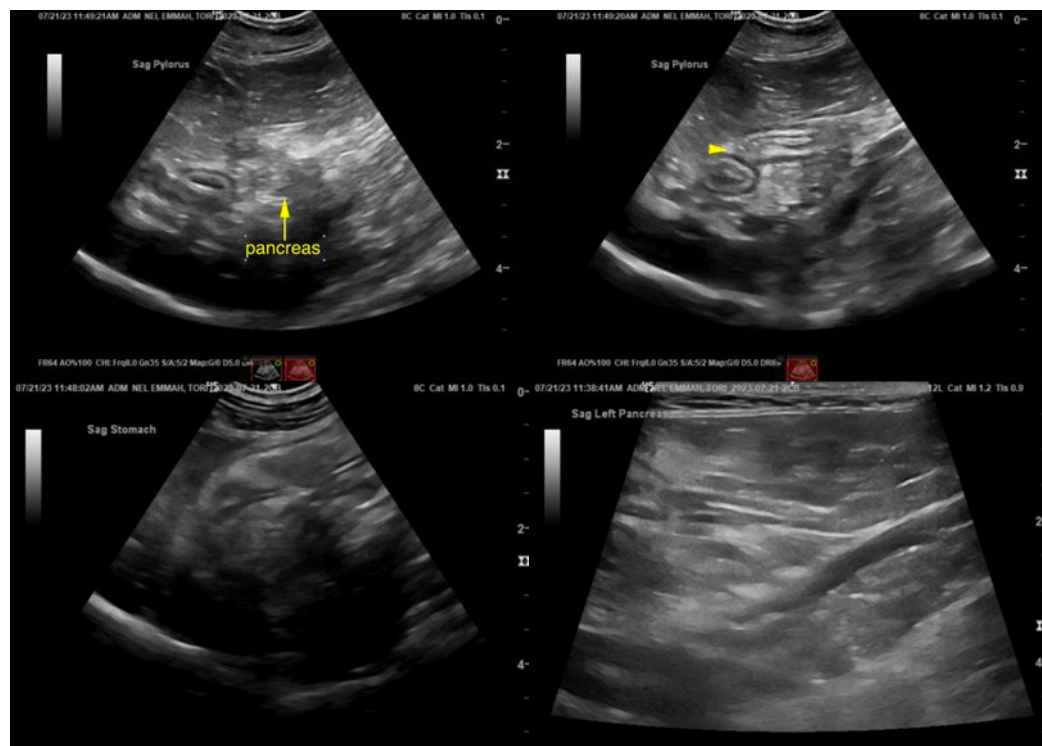
Dr. Kyono

INVOICE

44252

DATE

7/21/23





PATIENT

Tori Nel

SPECIES

Feline

BREED

Sphynx

SEX

Spayed Female

AGE

11

WEIGHT

4 kg

INTERPRETED BY

Eric Lindquist, DMV
DABVP, Cert. IVUSS

IMAGING PERFORMED BY

Dr. Belan

HOSPITAL NAME

Alpine 24/7 AH

REFERRING VET

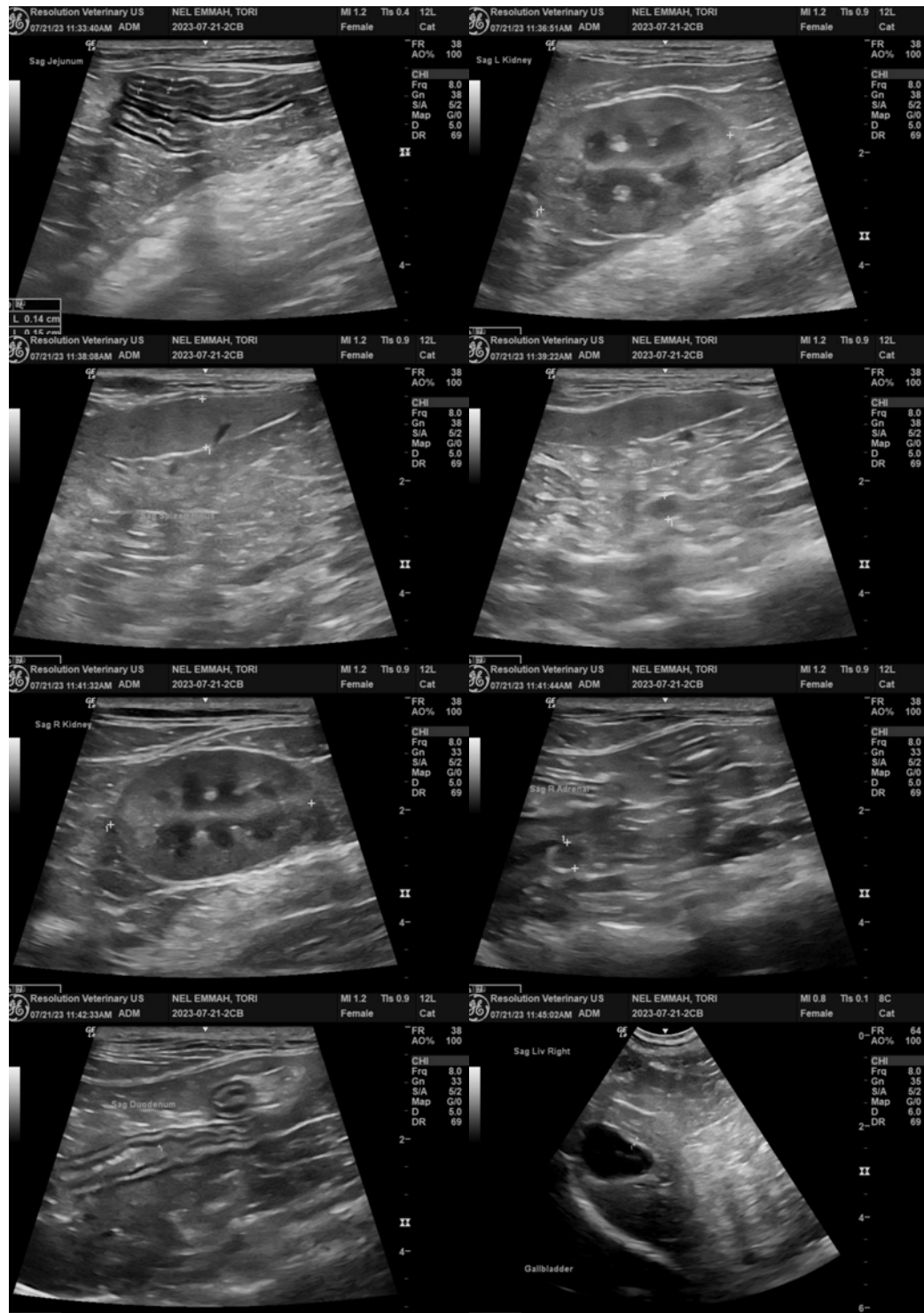
Dr. Kyono

INVOICE

44252

DATE

7/21/23





PATIENT

Tori Nel

SPECIES

Feline

BREED

Sphynx

SEX

Spayed Female

AGE

11

WEIGHT

4 kg

INTERPRETED BY

Eric Lindquist, DMV

DABVP, Cert. IVUSS

IMAGING PERFORMED BY

Dr. Belan

HOSPITAL NAME

Alpine 24/7 AH

REFERRING VET

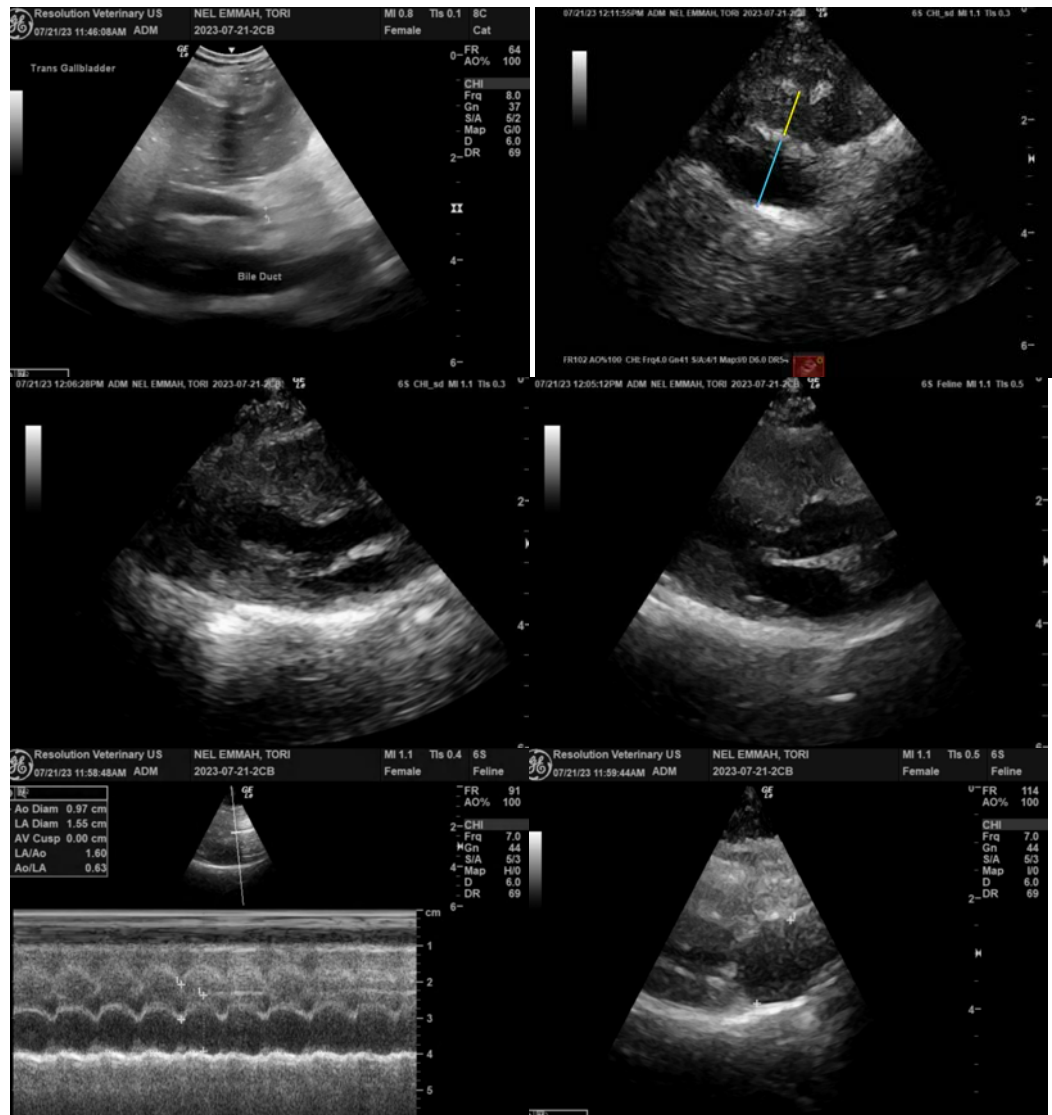
Dr. Kyono

INVOICE

44252

DATE

7/21/23





PATIENT

Tori Nel

SPECIES

Feline

BREED

Sphynx

SEX

Spayed Female

AGE

11

WEIGHT

4 kg

INTERPRETED BY

Eric Lindquist, DMV
DABVP, Cert. IVUSS

IMAGING PERFORMED BY

Dr. Belan

HOSPITAL NAME

Alpine 24/7 AH

REFERRING VET

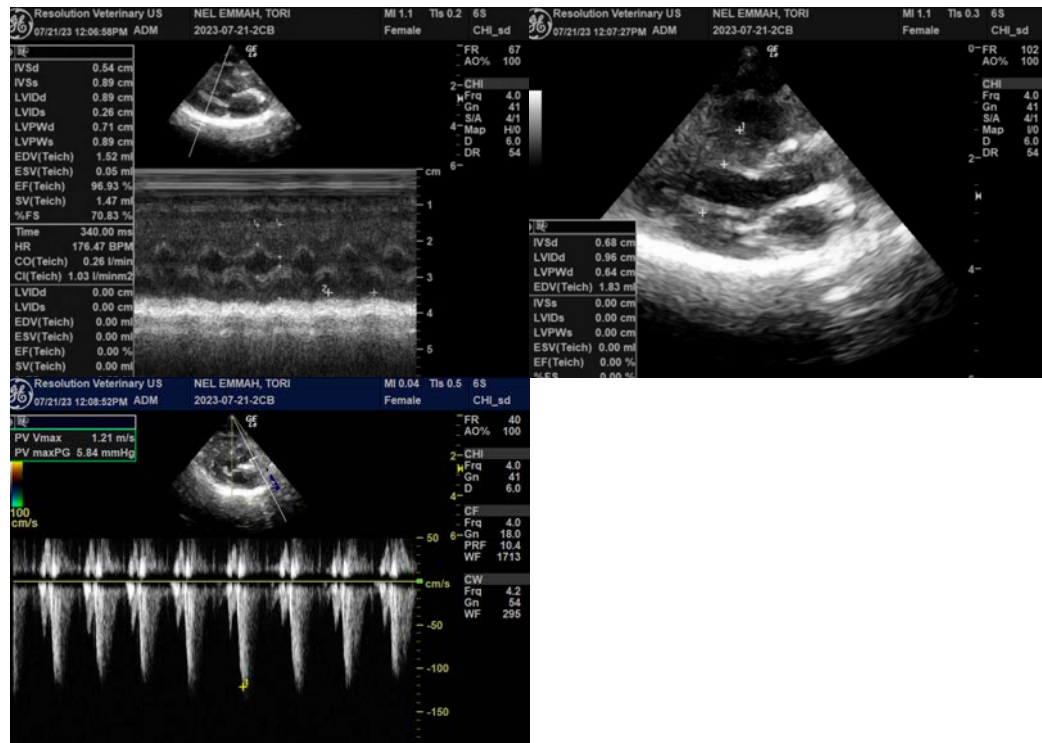
Dr. Kyono

INVOICE

44252

DATE

7/21/23



The information and recommendations provided are based on the images presented by the referring veterinarian/sonographer. No evaluation can be communicated regarding pathology that was not visible in the image/video clips provided.

Thank you for this referral. If the clinical or image interpretation does not parallel your findings or if I can be of any further assistance please contact me.

Eric Lindquist, DMV, DABVP, Cert. IVUSS, CEO of SonoPath.com

info@SonoPath.com