



DATE PRESENTING CLINICAL SIGNS

7/21/23 History of presumed inflammatory hepatitis - was doing well on low dose pred and ursodiol but over last several months alt and alp and bili have started to go back up, pet having intermittent V and appetite issues.

PATIENT

Kaiah Curry
Current Medications: currently on 2.5 mg prednisolone SID, Ursodiol 62.5 mg BID (was increased from SID after 6/16 apt), Cerenia 16 mg PRN, attempted to add in denamarin but pet V with it, O discontinued
Lab Results: 1/25/23 alt 683, alp 776, ggt 14, t bili 0.5. 2/15/23 alt 840, alp 840. 3/8/23 bile acid pre 119.3 post 137.4. 6/16/23 alt 3044, alp 2235. 7/19/23 alt 1990, alp 1817, tbili 1.5, ggt 68
Radiographs: 6/16/23 showed significant enlargement and rounding of liver
Date of Previous IntraPet Ultrasound: 1/14/22. See attached.
Sedation: Not required to complete full diagnostic ultrasound.
Stat Report: Not requested.
Imaging Performed By: Stephanie Warga RDCS, RVT.

SPECIES

Canine

BREED

Jack Russell

SEX

Spayed Female

AGE

1/15/09

WEIGHT

16.5 Pounds

INTERPRETED BY

Eric Lindquist, DMV
DABVP, Cert. IVUSS

HOSPITAL NAME

Greenbrier Vet Clinic

REFERRING VET

Dr. Boccanfuso

INVOICE

44260

ULTRASONOGRAPHIC EXAMINATION OF THE ABDOMEN

Urinary System

The **urinary bladder**, trigone, and pelvic urethra presented normal thicknesses and normal tone. The ureters were not visible which is normal. No uroliths or sediment were visualized and anechoic urine was present. No evidence of inflammatory or neoplastic changes were noted. Ureteral papillae were normal.

The **kidneys** revealed largely normal size and structure, corticomedullary definition and ratio (cortex 1/3 of medulla) were essentially maintained with some age-related loss of curvilinear patterns regarding the capsule and C/M junction. The cortices presented largely uniform texture with some increased echogenicity expected for his age patient. Medullary structure differed distinctly from that of the cortex and no evidence of pelvic dilation was present. The left kidney measured 4.33 cm. The right kidney measured 3.87 cm.

Adrenal Glands

Both **adrenal glands** were visualized and recognized as having largely normal shape, size, position and acceptable echogenicity for this age group and breed. Some heterogeneity was noted within the adrenal parenchyma without concerning capsular distortion. These changes are likely age related but should be monitored by sonogram should the patient be suspected of having adrenal disease. The left adrenal gland measured 1.91 cm x 0.75 cm at the caudal pole and 0.47 cm at the cranial pole, swollen yet remodeled caudal pole. The right adrenal gland measured 1.94 cm x 0.32 cm at the caudal pole and 0.61 cm at the cranial pole.

Spleen

The **spleen** was normal size and relatively normal contour with multifocal hyperechoic areas of mineralization. This is a benign change; however, can be related to Cushing's disease or other endocrinopathies.

Liver

The **liver** in this patient revealed diffuse macronodular disruptive parenchymal masses. A right cranial liver mass measured 6.5 cm x 4.87 cm. A left-sided mass measured 4.5 cm x 5.2 cm. The masses deviated the gallbladder cranially and do not appear resectable, given the multicentric to diffuse nature of the pathology.

Gastrointestinal

Examination of the **gastrointestinal tract** revealed a stomach and intestine free of stasis, of normal wall thickness, acceptable curvilinear mural detail, and peristaltic activity. Small and large intestine demonstrated

normal luminal chyme and stool consistency respectively. No obstructive or overt infiltrative disease was noted. No associated abnormal lymphatic activity was noted.

Pancreas

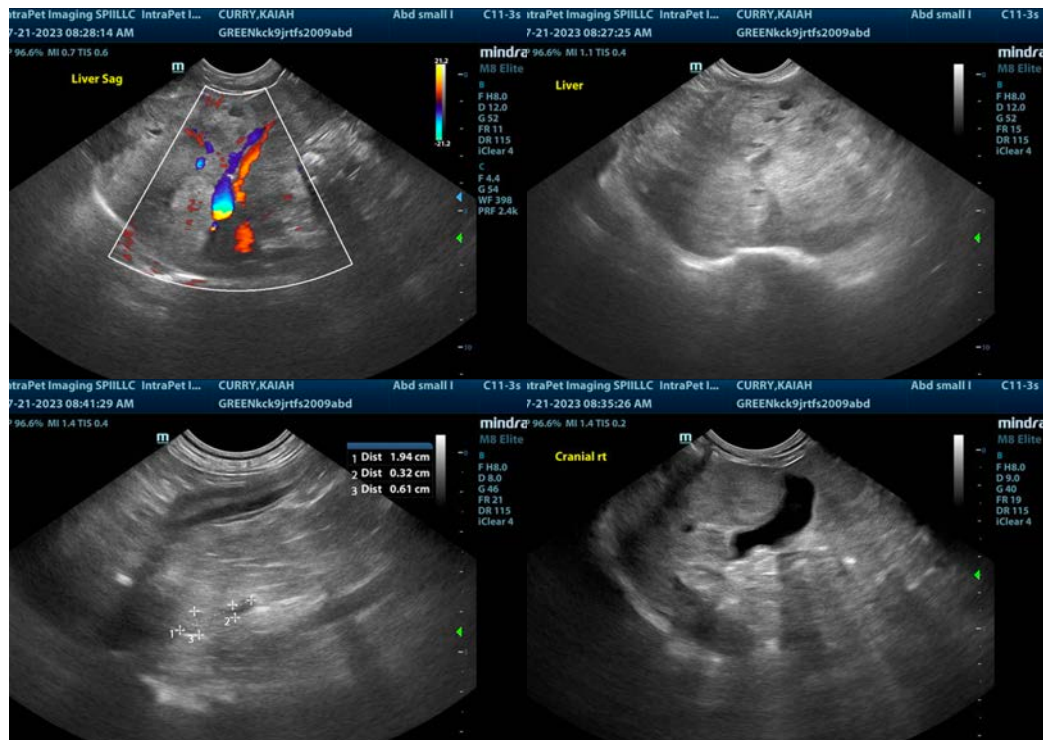
The base and limbs of the **pancreas** were observed to be largely isoechoic to surrounding omental fat. Pancreatic duct and capsular contour were acceptably normal and parenchyma respected normal curvilinear patterns. No overt evidence of active inflammatory or neoplastic disease was noted.

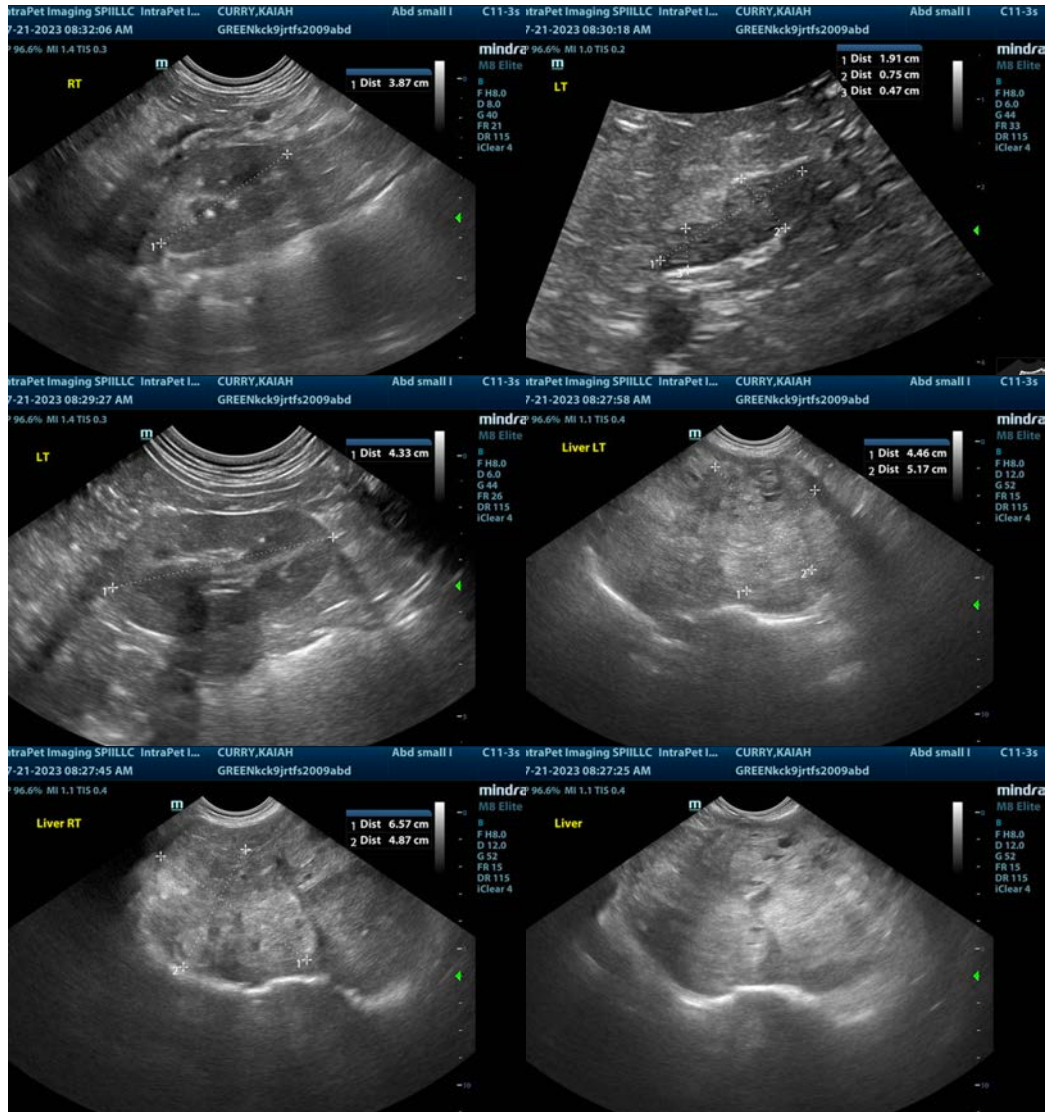
ULTRASONOGRAPHIC FINDINGS

- Diffuse hepatic neoplasia with multifocal disruptive masses and nodules – likely carcinoma.
- Age related renal and adrenal changes
- Mineralizing spleen

INTERPRETATION OF THE FINDINGS & FURTHER RECOMMENDATIONS

FNA of the masses could be considered for further definition. Bile acid profile could be considered to assess remaining function. However, prognosis is poor. Note the hepatic presentation is completely different and unrelated to the prior hepatic presentation. This is a fairly aggressive neoplastic hepatic presentation.





The information and recommendations provided are based on the images presented by the referring veterinarian/sonographer. No evaluation can be communicated regarding pathology that was not visible in the image/video clips provided.

Thank you for this referral. If the clinical or image interpretation does not parallel your findings or if I can be of any further assistance please contact me.

Eric Lindquist, DMV, DABVP, Cert. IVUSS, CEO of SonoPath.com
info@SonoPath.com