


PATIENT PRESENTING CLINICAL SIGNS

Jack Rodriguez

P is currently having diarrhea. Recently went to CARE ER clinic and dr thought heart and liver looked enlarged. Concerned for Cushings dz

SPECIES

Canine

Abnormal PE/Chem/CBC/UA Results: Alkp 696 (23-212) ALT 197 (10-125)

BREED

Rottie x

ULTRASONOGRAPHIC EXAMINATION OF THE HEART & ABDOMEN
SEX

Neutered Male

AGE

11 Years

WEIGHT

67 Pounds

CANINE CARDIAC PARAMETERS	MR VMAX (m/s)	TR VMAX (m/s)	LA/AO (Boon method)	LA/AO (Heart Base; Swe)	FS (%)	EF (%)	EPSS (cm)
NORMAL PARAMETER	4.5-5.5	<2.7	1.3	Up to 1.6	28-40	40-100	<0.6
PATIENT	5.2	2.48	1.4	1.18	37	68	0.47
CANINE CARDIAC PARAMETERS	HR (BPM)	AV VMAX (m/s)	PV MAX (m/s)	BODY WEIGHT (kg)	LA 2D short axis Base view (cm)	LVIDd Avg; 2D and m-mode short axis (cm)	LVIDs Avg; 2D and m-mode short axis (cm)
NORMAL PARAMETER	50-100	0.7-1.7	0.7-1.6	BELOW	BELOW	BELOW	BELOW
PATIENT	90	1.59	0.76		4.63	3.93	

INTERPRETED BY

Eric Lindquist, DMV

DABVP, Cert. IVUSS

E-wave velocity = 0.7

IMAGING PERFORMED BY

Carolina Vet Mobile

HOSPITAL NAME

Armstrong AC

REFERRING VET

Dr. Marnie Gallagher

INVOICE

44254

DATE

7/21/23

Cardiac Presentation

The echocardiogram in this patient demonstrated normal **left atrial** size based on 3 different LA measurement methods. Chamber volumes and echogenicity were normal. The cranial and caudal **mitral** valve leaflets presented vegetative thickening consistent with endocardiosis. Doppler indicated measurable insufficiency. Mitral insufficiency jet was centralized with moderate filling of the left atrium. The **left ventricle** presented thicknesses with linear contour and was not dilated nor restricted. The **myocardium** presented normal echogenicity without subjective evidence of significant fibrotic or ischemic disease. **Contractility** of the ventricular walls was adequate and in normal range for this patient evidenced by the fractional shortening measurement and subjective evaluation of the different regions of the myocardium. The **left ventricular outflow** tract demonstrated normal laminar flow and subjective structural integrity. The **right atrium** and auricle revealed normal size, structure and content. No evidence of masses was noted or chamber overload. **Tricuspid** insufficiency noted. The **right ventricle** was of normal size (1/3 diameter of LV), chordae structure, myocardial echogenicity and thickness. **Pulmonic** tract assessment revealed normal valve structure, laminar flow, and diameter (approx. 1:1 pa/ao ratio). No visible **pericardial** or free pleura fluid was noted. No echographically detectable evidence of infiltrative disease was visible. The cranial **mediastinum** and **pericardial** regions were free of masses in the visible window. Hepatic veins were not dilated.



PATIENT *Urinary System*

Jack Rodriguez

The **urinary bladder**, trigone, and pelvic urethra presented normal thicknesses and normal tone. The ureters were not visible which is normal. No uroliths or sediment were visualized and anechoic urine was present. No evidence of inflammatory or neoplastic changes were noted. Ureteral papillae were normal. The pelvic urethra was imaged 2.0 cm beyond the cystourethral junction. The residual prostate was unremarkable at 1.4 cm. Pre- and post-prostatic urethra were unremarkable.

SPECIES

Canine

BREED

Rottie x

The **kidneys** revealed largely normal size and structure, corticomedullary definition and ratio (cortex 1/3 of medulla) were essentially maintained with some age-related loss of curvilinear patterns regarding the capsule and C/M junction. The cortices presented largely uniform texture with some increased echogenicity expected for his age patient. Medullary structure differed distinctly from that of the cortex and no evidence of pelvic dilation was present. The right kidney measured 6.4 cm.

SEX

Neutered Male

Adrenal Glands

AGE

11 Years

Both **adrenal glands** were visualized and recognized as having normal shape, size, position and echogenicity for this breed. The phrenic vasculature, glandular echogenicity and detail were unremarkable. Capsule, cortex, and medullary definition were normal for this age patient. The left adrenal gland measured 2.26 cm x 0.59 cm at the cranial pole and 0.56 cm at the caudal pole. The right adrenal gland measured 2.17 cm x 0.79 cm at the caudal pole and 0.57 cm at the cranial pole.

WEIGHT

67 Pounds

Spleen

INTERPRETED BY

Eric Lindquist, DMV

The **spleen** presented a focal hypoechoic 1.4 cm mixed hypoechoic nodule at the cranial pole with mild capsular expansion and mild disruption of architecture. FNA and/or monitoring for progression recommended over the next 3-4 weeks.

DABVP, Cert. IVUSS

Liver

IMAGING PERFORMED BY

Carolina Vet Mobile

The **liver** images from right and left intercostal as well as subcostal views revealed subjectively normal liver size, contour, and structure. Some age-related parenchymal remodeling was noted but likely not clinically significant at this time. Vascular and biliary tracts were of normal volume and no evidence of congestion was noted. The gallbladder presented some dependent debris with essentially normal contour. The cystic and common bile ducts were normal. No overt evidence of active inflammatory, infiltrative or regenerative pathology was noted but should be paired with current or past LE elevations regarding any clinical significance to this presentation. The hepatic lymph nodes were unremarkable.

HOSPITAL NAME

Armstrong AC

Gastrointestinal

REFERRING VET

Dr. Marnie Gallagher

There was some residual chyme and gas was noted in the **stomach**, yet not pathological. This is consistent with end post prandial presentation. Transit of chyme into the small intestine was normal. Curvilinear patterns were maintained throughout the GI tract. No evidence of pathology. Small and large intestine demonstrated normal luminal chyme and stool consistency respectively. No obstructive or overt infiltrative disease was noted. No associated abnormal lymphatic activity was noted.

INVOICE

44254

DATE

7/21/23

Pancreas

The base and limbs of the **pancreas** were observed to be largely isoechoic to surrounding omental fat. Pancreatic duct and capsular contour were acceptably normal and parenchyma respected normal curvilinear patterns. No overt evidence of active inflammatory or neoplastic disease was noted.



PATIENT

Jack Rodriguez

SPECIES

Canine

BREED

Rottie x

SEX

Neutered Male

AGE

11 Years

WEIGHT

67 Pounds

INTERPRETED BY

Eric Lindquist, DMV

DABVP, Cert. IVUSS

IMAGING PERFORMED BY

Carolina Vet Mobile

HOSPITAL NAME

Armstrong AC

REFERRING VET

Dr. Marnie Gallagher

INVOICE

44254

DATE

7/21/23

ULTRASONOGRAPHIC FINDINGS

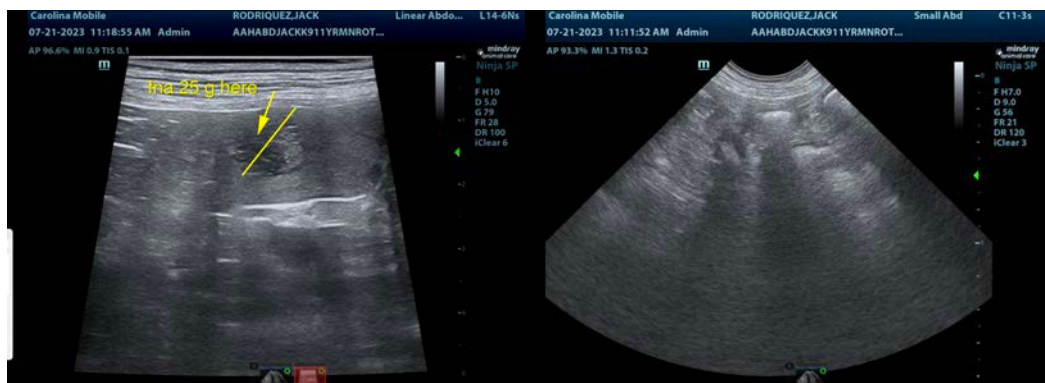
- Stage B1 valvular disease
- Splenic nodule – incidental finding and not likely an urgent clinical issue but should be monitored. Differentials include emerging round cell neoplasia, hemangiosarcoma, hyperplasia.
- Structurally unremarkable abdomen

INTERPRETATION OF THE FINDINGS & FURTHER RECOMMENDATIONS

The heart is stable without clinical disease. No overt contraindication for anesthesia of brief to moderate duration. I suggest Torbutrol premed, Propofol induction, Isoflor maintenance or similar protocol if anesthesia is desired. Blood pressure recommended if not already performed and target white coat negative systolic pressure of < 160 mmHg. If higher than this ACE-inhibitor is suggested to reach this level. Recheck echocardiogram is recommended in 6 months, earlier if murmur grade increases or clinical signs initiate.

The splenic nodule should be monitored. FNA could be considered. Direct splenectomy could also be justified in this patient.

Differentials for diarrhea include occult parasitism. Dietary indiscretion, dietary intolerance, antibiotic responsive colitis, intestinal dysbiosis and occult Addison's should all be considered as causes of diarrhea in this patient. A hydrolyzed diet trial may be in this patient's best interest +/- probiotics. 24-hour NPO and reintroduction of bland diet indicated. I recommend a baseline cortisol or ACTH stimulation test, a fresh fecal smear and fecal floatation analysis if not already performed.





PATIENT

Jack Rodriguez

SPECIES

Canine

BREED

Rottie x

SEX

Neutered Male

AGE

11 Years

WEIGHT

67 Pounds

INTERPRETED BY

Eric Lindquist, DMV

DABVP, Cert. IVUSS

IMAGING PERFORMED BY

Carolina Vet Mobile

HOSPITAL NAME

Armstrong AC

REFERRING VET

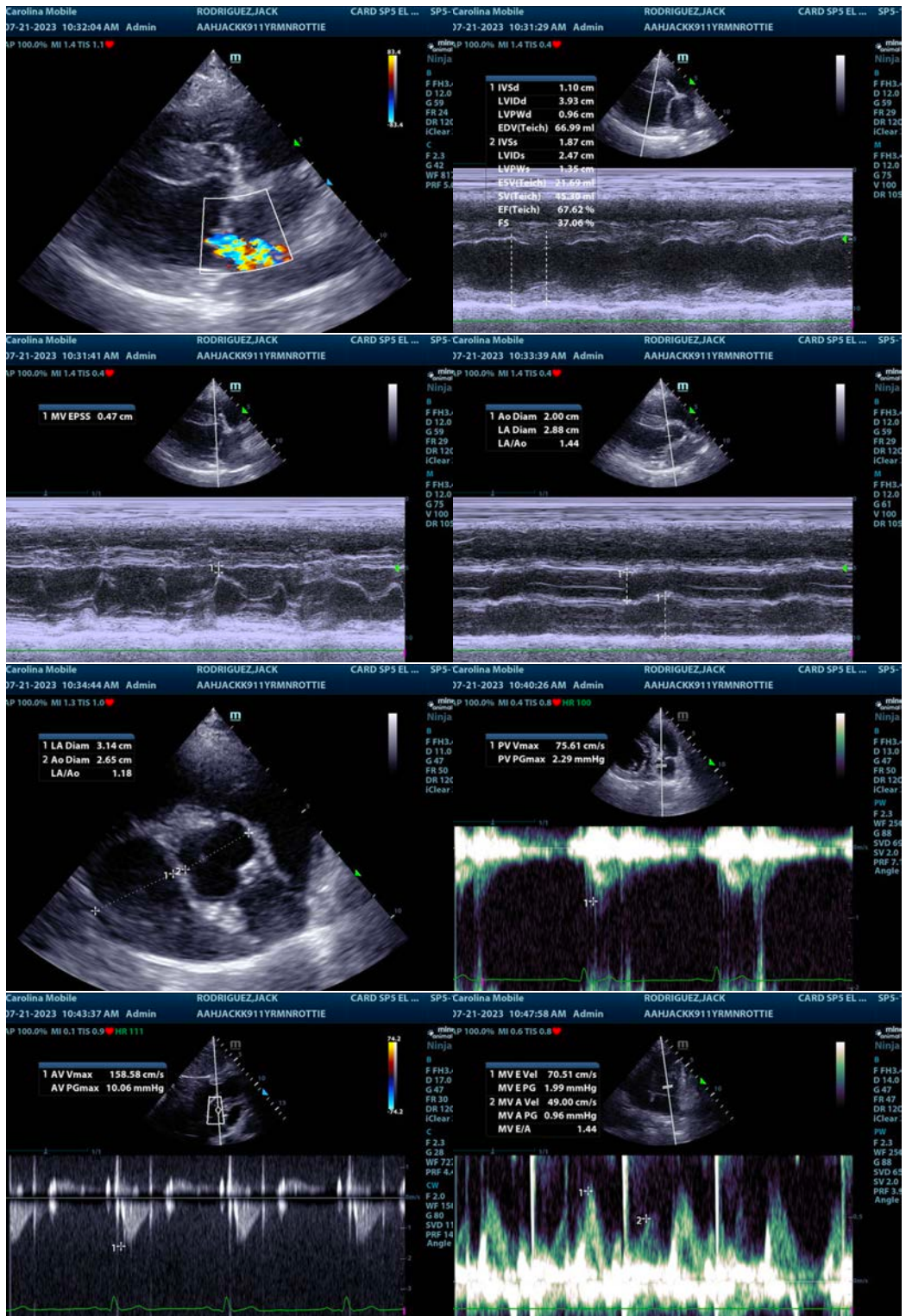
Dr. Marnie Gallagher

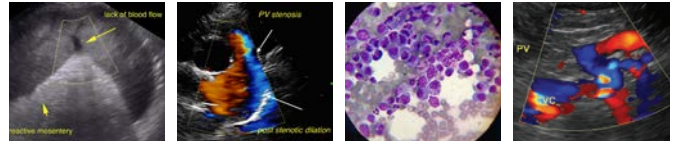
INVOICE

44254

DATE

7/21/23





PATIENT

Jack Rodriguez

SPECIES

Canine

BREED

Rottie x

SEX

Neutered Male

AGE

11 Years

WEIGHT

67 Pounds

INTERPRETED BY

Eric Lindquist, DMV
DABVP, Cert. IVUSS

IMAGING PERFORMED BY

Carolina Vet Mobile

HOSPITAL NAME

Armstrong AC

REFERRING VET

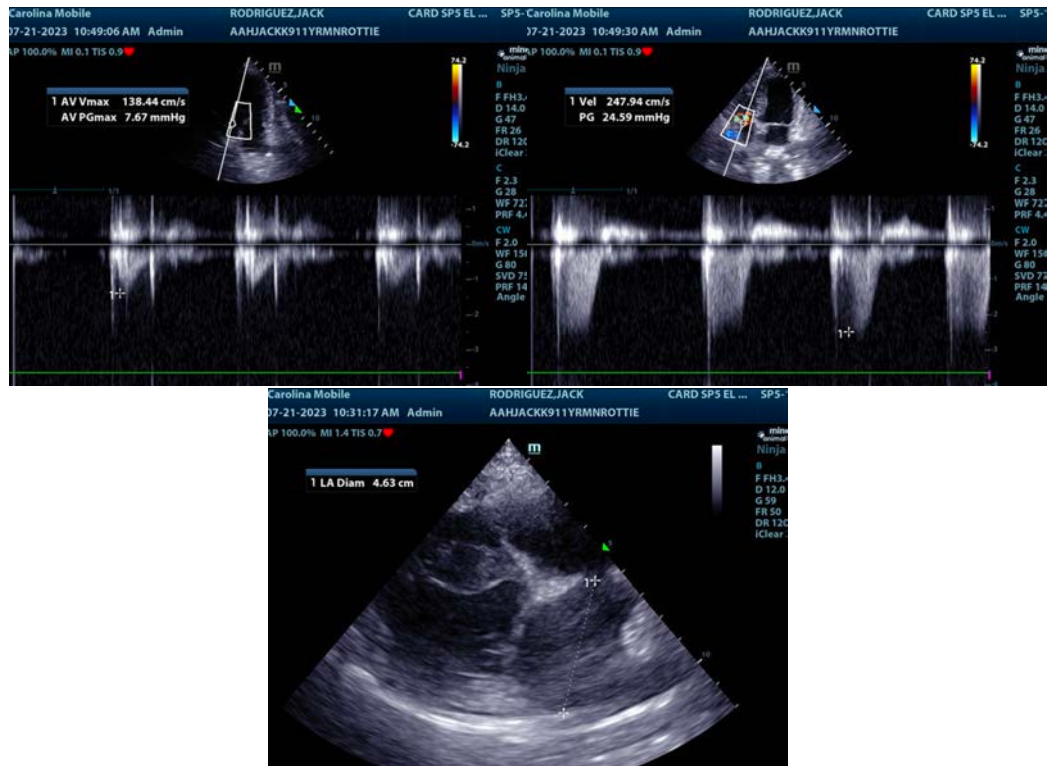
Dr. Marnie Gallagher

INVOICE

44254

DATE

7/21/23



The information and recommendations provided are based on the images presented by the referring veterinarian/sonographer. No evaluation can be communicated regarding pathology that was not visible in the image/video clips provided.

Thank you for this referral. If the clinical or image interpretation does not parallel your findings or if I can be of any further assistance please contact me.

Eric Lindquist, DMV, DABVP, Cert. IVUSS, CEO of SonoPath.com

info@SonoPath.com