

**DATE PRESENTING CLINICAL SIGNS**

7/21/23

History: Ate normally this pm. Then this pm vomited a large amount of food. Vomited a piece of a dentastick. The last vomitus had blood in it. Foamy. Owner reports that he is very difficult to give oral medications.

**PATIENT**

Hank Krieser

Current Medications: Sucralfate, Protonix, Provable, Ampicillin, Ondansetron, Metronidazole, Cerenia.  
 Lab Results: See attached.

**SPECIES**

Canine

Radiographs: No obvious FB or obstructive pattern, gas in the colon.

Date of Previous IntraPet Ultrasound: No previous.

Sedation: Not required to complete full diagnostic ultrasound.

Stat Report: Not requested.

**BREED**

Imaging Performed By: Rachel Brillhart, RDMS.

Yorkshire Terrier Mix

**ULTRASONOGRAPHIC EXAMINATION OF THE ABDOMEN****SEX**

Neutered Male

**Urinary System**

The **urinary bladder**, trigone, and pelvic urethra presented normal thicknesses and normal tone. The ureters were not visible which is normal. No uroliths or sediment were visualized and anechoic urine was present. No evidence of inflammatory or neoplastic changes were noted. Ureteral papillae were normal.

**AGE**

4/16/19

The **kidneys** revealed normal size and structure, corticomedullary definition and ratio for this age. The cortices presented largely uniform texture with normal echogenic relationship to liver and spleen. Medullary structure differed distinctly from the cortex and no evidence of pelvic dilation was present. The capsules were acceptably uniform without significant irregularities. The right kidney measured 4.7 cm. The left kidney measured 4.65 cm.

**WEIGHT**

17.2 Pounds

**Adrenal Glands**

Both **adrenal glands** were visualized and recognized as having normal shape, size, position and echogenicity for this breed. The phrenic vasculature, glandular echogenicity and detail were unremarkable. Capsule, cortex, and medullary definition were normal for this age patient. The left adrenal gland measured 1.96 cm x 0.6 cm at the caudal pole and 0.55 cm at the cranial pole. The right adrenal gland measured 2.23 cm x 0.89 cm at the cranial pole and 0.76 cm at the caudal pole.

**INTERPRETED BY**

Eric Lindquist, DMV  
 DABVP, Cert. IVUSS

**HOSPITAL NAME**

Animal Emergency  
 Hospital

**Spleen**

The **spleen** presented a smooth homogeneous parenchyma hyperechoic to liver and renal cortical parenchyma. The capsule was smooth without noticeable expansion or deviation from within the spleen or adjacent pathology. The splenic vasculature demonstrated normal volume without signs of congestion or thrombosis. No sonographic evidence of acute or chronic inflammatory, neoplastic, or infarctual changes were noted.

**REFERRING VET**

Dr. Ruby

**Liver**

The **liver** images submitted revealed subjectively normal liver size, contour, and structure. Parenchymal echogenicity was naturally coarse and hypoechoic to the spleen. Vascular and biliary tracts were of normal volume with no evidence of congestion. The gallbladder presented acceptably thin walls with primarily anechoic content. The cystic and common bile ducts were normal. No pathological hepatic lymphadenopathy was evident. No overt structural evidence of inflammatory, infiltrative or regenerative pathology was evident.

**INVOICE**

23568

**Gastrointestinal**

The upper **gastrointestinal tract** in this patient revealed minor, edematous wall. There was no evidence of foreign bodies. Minor areas of fluctuant fluid accumulation were noted within the lumen with hyperperistalsis. This pattern continued to the ileocecal valve. The colon revealed a fluid filled lumen. This presentation is most consistent with gastrointestinal irritation/inflammation without obstruction. This is a minor change.

### **Pancreas**

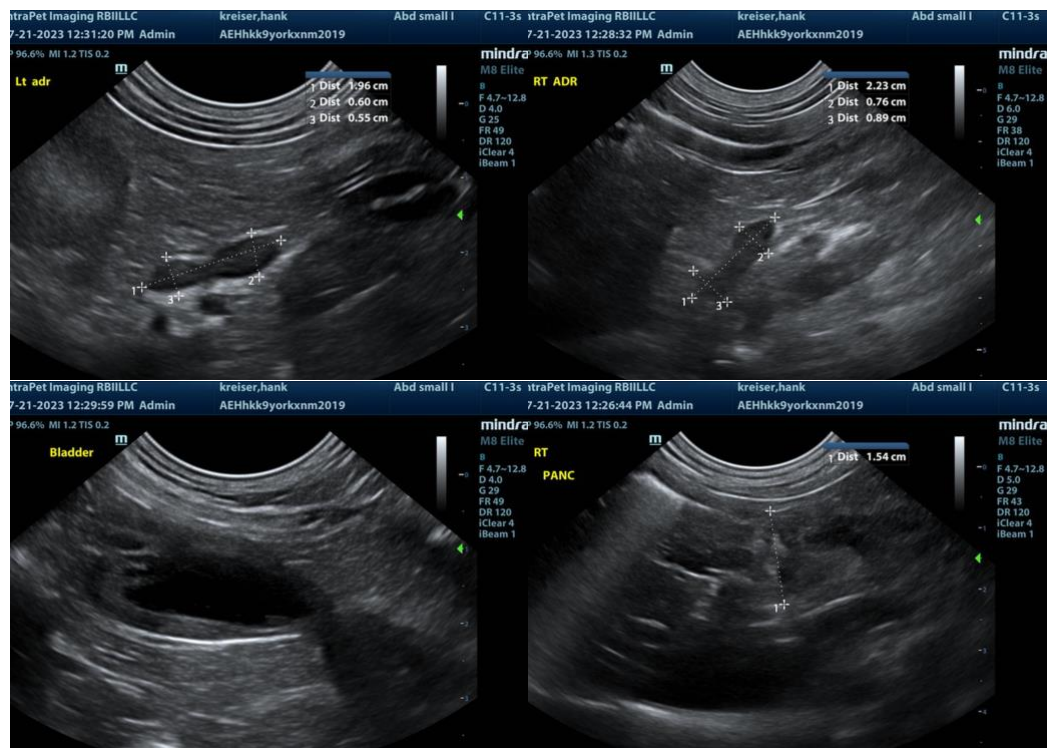
The **pancreas** revealed minor heterogenous parenchymal changes in the right limb with possible low grade inflammation. A history of pancreatitis is likely.

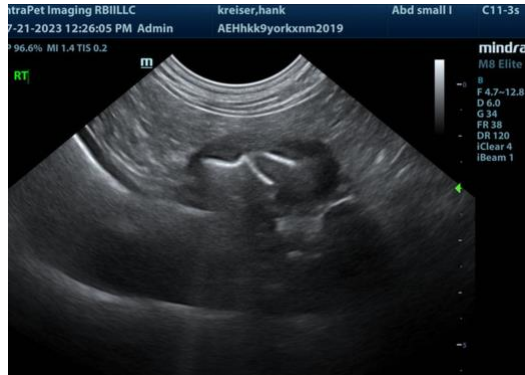
### **ULTRASONOGRAPHIC FINDINGS**

- Minor heterogenous pancreas- potential low-grade pancreatitis
- Gastroenteritis pattern

### **INTERPRETATION OF THE FINDINGS & FURTHER RECOMMENDATIONS**

Subxiphoid palpation is recommended to assess for pain or discomfort associated with the pancreas. No evidence of foreign bodies.





**The information and recommendations provided are based on the images presented by the referring veterinarian. No evaluation can be communicated regarding pathology that was not visible in the image/video clips provided.**

Thank you for this referral. If the clinical or image interpretation does not parallel your findings or if I can be of any further assistance please contact me.

**Eric Lindquist**, DMV, DABVP, Cert. IVUSS, CEO of SonoPath.com  
info@SonoPath.com