



**PATIENT**

Cotton Rose

**SPECIES**

Canine

**BREED**

Maltese x

**SEX**

Neutered Male

**AGE**

13 Years 11 Months

**WEIGHT**

14.5 Pounds

**INTERPRETED BY**

Eric Lindquist, DMV

DABVP, Cert. IVUSS

**IMAGING PERFORMED BY**

Carolina Vet Mobile

**HOSPITAL NAME**

Armstrong AC

**REFERRING VET**

Dr. Joey Aquino

**INVOICE**

44256

**DATE**

7/21/23

**PRESENTING CLINICAL SIGNS**

P presented for cough. Owner reports P has not eaten in 2 days and is considering euthanasia. Mass found in L caudal lung field on Rads. Drained 3 mls of serosanguinous fluid for cavitory lesions, Did FNA of 2 other areas in lesion.

**ULTRASONOGRAPHIC EXAMINATION OF THORAX**

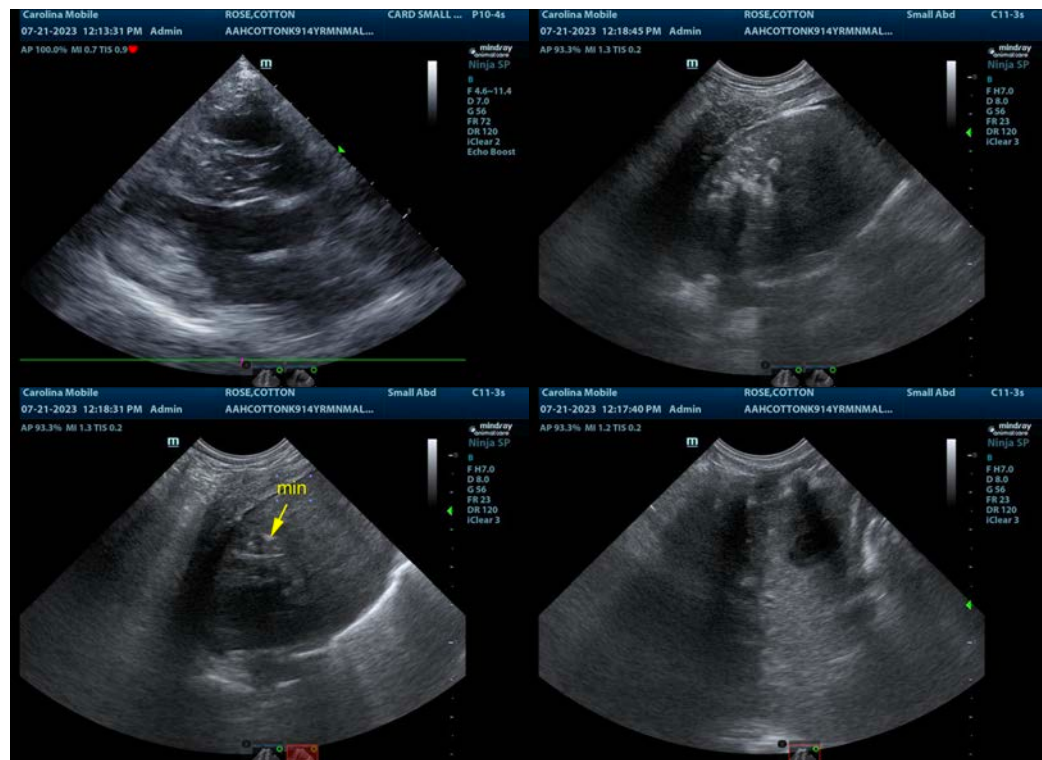
The heart revealed normal chamber sizes, volume and contractility. No evidence of primary disease. However, the caudal thorax revealed a microcavitated and parenchymal mass measuring approximately 8.0 cm adjacent to the diaphragm with peripheral air entrapment, indicative of lung origin. Areas of mineralization noted, suggestive for carcinoma. Possibility of lung sarcoma, necrosis less likely. Trace pleural effusion noted.

**ULTRASONOGRAPHIC FINDINGS**

- Mineralizing lung mass with normal echocardiogram

**INTERPRETATION OF THE FINDINGS & FURTHER RECOMMENDATIONS**

Possibly resectable depending upon chest CT findings ideally. Abdominal sonogram would be ideal to assess comorbidities or related pathology.





**PATIENT**

Cotton Rose

**SPECIES**

Canine

**BREED**

Maltese x

**SEX**

Neutered Male

**AGE**

13 Years 11 Months

**WEIGHT**

14.5 Pounds

**INTERPRETED BY**

Eric Lindquist, DMV

DABVP, Cert. IVUSS

**IMAGING PERFORMED BY**

Carolina Vet Mobile

**HOSPITAL NAME**

Armstrong AC

**REFERRING VET**

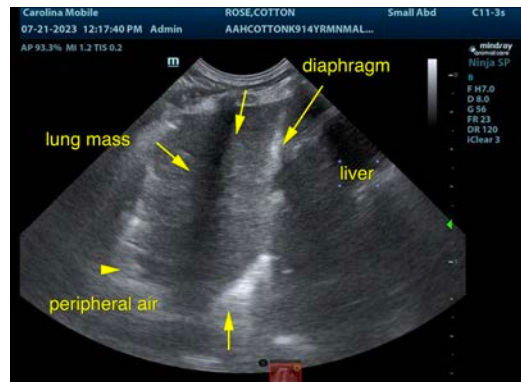
Dr. Joey Aquino

**INVOICE**

44256

**DATE**

7/21/23



The information and recommendations provided are based on the images presented by the referring veterinarian/sonographer. No evaluation can be communicated regarding pathology that was not visible in the image/video clips provided.

Thank you for this referral. If the clinical or image interpretation does not parallel your findings or if I can be of any further assistance please contact me.

Eric Lindquist, DMV, DABVP, Cert. IVUSS, CEO of SonoPath.com

[info@SonoPath.com](mailto:info@SonoPath.com)