



PATIENT

Brody Starnella

SPECIES

Canine

BREED

Yorkshire Terrier

SEX

Neutered Male

AGE

15 Years

WEIGHT

9.0 Pounds

INTERPRETED BY

Eric Lindquist, DMV

DABVP, Cert. IVUSS

IMAGING PERFORMED BY

Val Shumskaya

HOSPITAL NAME

Englewood Vet Center

REFERRING VET

Dr. Ezik

INVOICE

23560

DATE

7/21/23

PRESENTING CLINICAL SIGNS

Recheck echo + abd.

ULTRASONOGRAPHIC EXAMINATION OF THE ABDOMEN

Urinary System

The **urinary bladder** itself was unremarkable, however, the prostate was enlarged, irregular and mineralizing, strongly consistent with prostatic carcinoma with mild potential for trailing, measuring 2.0 cm. Ultrasound guided FNA or traumatic catheterization is warranted to confirm suspicion of carcinoma.

The **kidneys** revealed largely normal size and structure, corticomedullary definition and ratio (cortex 1/3 of medulla) were essentially maintained with some moderate age-related loss of curvilinear patterns regarding the capsule and C/M junction. The cortices presented largely uniform texture with some increased echogenicity expected for his age patient. Medullary structure differed distinctly from that of the cortex and no evidence of pelvic dilation was present. The right kidney measured 4.11 cm. The left kidney measured 3.6 cm. Polycystic cortical renal changes were noted in both kidneys. The degenerative changes were considered moderate.

Adrenal Glands

Both **adrenal glands** were visualized and recognized as having largely normal shape, size, position and acceptable echogenicity for this age group and breed. Some heterogeneity was noted within the adrenal parenchyma without concerning capsular distortion. These changes are likely age related but should be monitored by sonogram should the patient be suspected of having adrenal disease. The left adrenal gland measured 1.29 cm x 0.79 cm at the cranial pole and 0.39 cm at the caudal pole. The right adrenal gland measured 1.82 cm x 1.27 cm at the cranial pole and 0.71 cm at the caudal pole.

Spleen

The **spleen** presented a smooth homogeneous parenchyma hyperechoic to liver and renal cortical parenchyma. The capsule was smooth without noticeable expansion or deviation from within the spleen or adjacent pathology. The splenic vasculature demonstrated normal volume without signs of congestion or thrombosis. No sonographic evidence of acute or chronic inflammatory, neoplastic, or infarctual changes were noted.

Liver

The **liver** was uniformly swollen with minor, excessive gallbladder debris and over distension with dependent and suspended bile without evidence of overt mucocele formation. However, excessive sludge was present. The liver presented coarse architecture with mildly increased portal markings and subtle, mixed echogenic changes. This is a mild to moderate change, consistent with vacuolar hepatopathy and some level of remodeling and history of inflammatory component. There was no overt suspicion of neoplasia.

Gastrointestinal



PATIENT

Brody Starnella

SPECIES

Canine

BREED

Yorkshire Terrier

SEX

Neutered Male

AGE

15 Years

WEIGHT

9.0 Pounds

INTERPRETED BY

Eric Lindquist, DMV

DABVP, Cert. IVUSS

**IMAGING
PERFORMED BY**

Val Shumskaya

HOSPITAL NAME

Englewood Vet Center

REFERRING VET

Dr. Ezik

INVOICE

23560

DATE

7/21/23

Examination of the **gastrointestinal tract** revealed a stomach and intestine free of stasis, of normal wall thickness, acceptable curvilinear mural detail, and peristaltic activity. Small and large intestine demonstrated normal luminal chyme and stool consistency respectively. No obstructive or overt infiltrative disease was noted. No associated abnormal lymphatic activity was noted.

Pancreas

The base and limbs of the **pancreas** were observed to be largely isoechoic to surrounding omental fat. Pancreatic duct and capsular contour were acceptably normal and parenchyma respected normal curvilinear patterns. No overt evidence of active inflammatory or neoplastic disease was noted.

ULTRASONOGRAPHIC FINDINGS

- Prominent adrenal glands with remodeling
- Prostatic mass, consistent with carcinoma
- Moderate degenerative renal changes with secondary polycystic cortices
- Benign hepatopathy with remodeling

INTERPRETATION OF THE FINDINGS & FURTHER RECOMMENDATIONS

FNA of the prostatic mass or traumatic catheterization is warranted to confirm carcinoma.



PATIENT

Brody Starnella

SPECIES

Canine

BREED

Yorkshire Terrier

SEX

Neutered Male

AGE

15 Years

WEIGHT

9.0 Pounds

INTERPRETED BY

Eric Lindquist, DMV

DABVP, Cert. IVUSS

IMAGING PERFORMED BY

Val Shumskaya

HOSPITAL NAME

Englewood Vet Center

REFERRING VET

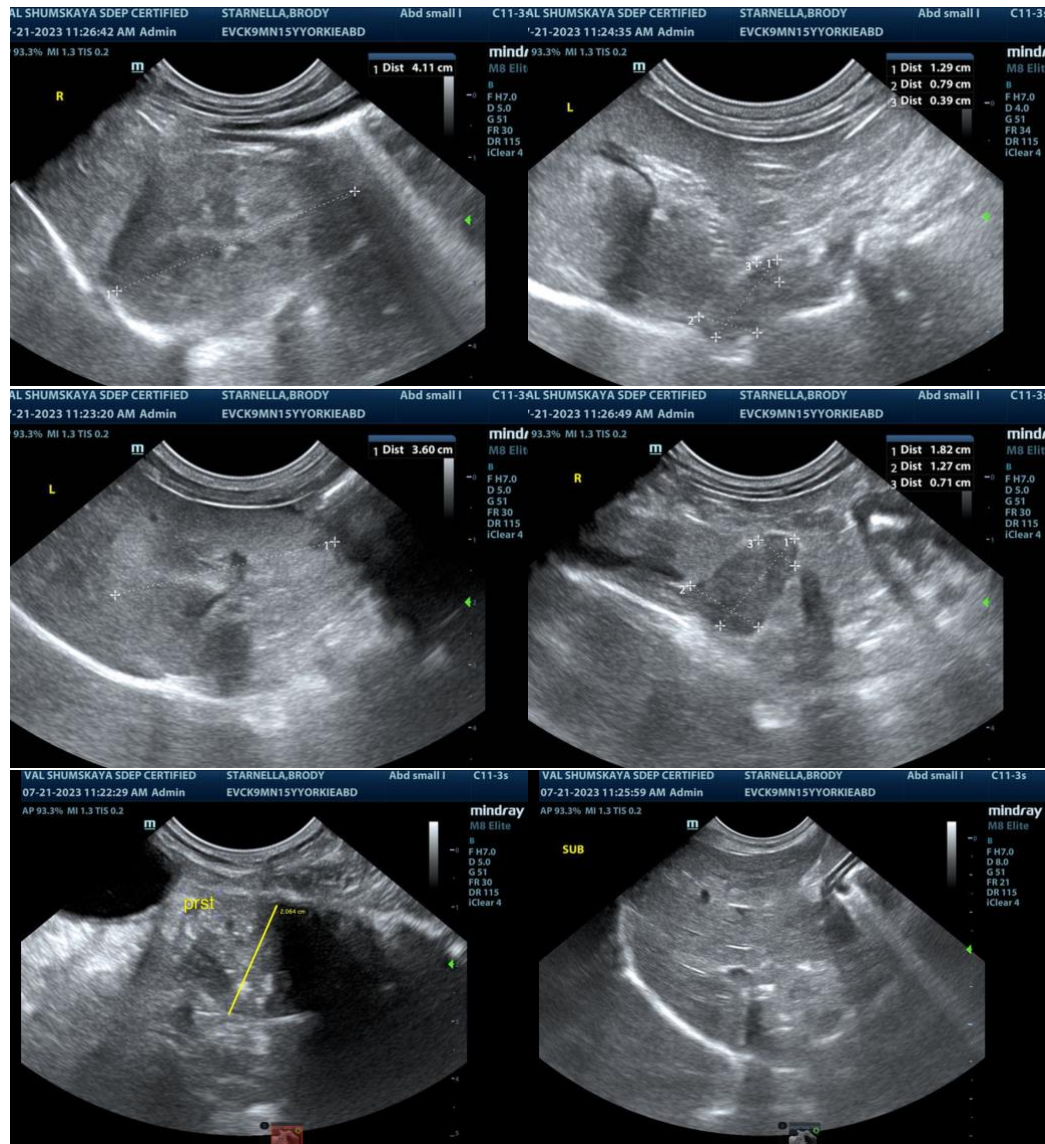
Dr. Ezik

INVOICE

23560

DATE

7/21/23



The information and recommendations provided are based on the images presented by the referring veterinarian/sonographer. No evaluation can be communicated regarding pathology that was not visible in the image/video clips provided.

Thank you for this referral. If the clinical or image interpretation does not parallel your findings or if I can be of any further assistance please contact me.

Eric Lindquist, DMV, DABVP, Cert. IVUSS, CEO of SonoPath.com

info@SonoPath.com

Canine Prostatic Neoplasia



PATIENT

<http://www.sonopath.com/ProstaticCarcinoma>

Brody Starnella

SPECIES

Canine

BREED

Yorkshire Terrier

SEX

Neutered Male

AGE

15 Years

WEIGHT

9.0 Pounds

INTERPRETED BY

Eric Lindquist, DMV

DABVP, Cert. IVUSS

IMAGING PERFORMED BY

Val Shumskaya

HOSPITAL NAME

Englewood Vet Center

REFERRING VET

Dr. Ezik

INVOICE

23560

DATE

7/21/23

Description: Prostatic neoplasia is frequently seen in dogs and can be diagnosed via ultrasonographic examination. The most commonly diagnosed prostatic neoplasms are adenocarcinoma and undifferentiated carcinoma. Transitional cell carcinoma (TCC) frequently spreads from the urinary bladder and urethra to the prostatic tissue (see the “Transitional Cell Carcinoma” chapter for more details). Metastatic squamous cell carcinoma, lymphoma, hemangiosarcoma, and leiomyosarcoma have been reported, but are less prevalent. Prostatic neoplasia has been documented in cats, but is quite rare.

Clinical Signs: Prostatic neoplasia presents in both neutered and intact males; however, a 2002 study suggested that neutered males were at greater risk for developing prostatic neoplasia than intact males. Typically, prostatic neoplasia is seen in older dogs (mean age of 10 years). Breed predilection includes mixed breed dogs, Shetland Sheepdogs, Dobermans, Scottish Terriers, and Airedale Terriers. Clinical signs and commonly reported signs from owners typically include: stranguria, frequent urinations, hematuria, dyschezia, weight loss, and decreased appetite. Other findings upon physical examination include fever, ataxia, pain upon rectal examination, and pain upon spinal palpation.

Diagnostics: Ultrasonographic examination should be performed if prostatic neoplasia is suspected. Common ultrasonographic findings include an enlarged, irregular prostate that typically has a hypoechoic appearance. Multifocal, poorly coalescing hyperechoic foci are also seen in prostatic malignancies. Hyperechoic foci are due to mineralization of the prostate; they cause far field shadowing. Cystic components can also be observed and are thought to indicate abscessation and/or necrosis. It can be difficult to differentiate chronic bacterial prostatitis from a prostatic neoplasia; however, regional lymphadenopathy is much more common with prostatic neoplasia than it is with chronic bacterial prostatitis. Malignancies of the prostate have often metastasized by the time of diagnosis. Frequent sites of metastases include the sublumbar lymph nodes, the pelvis, lumbar vertebrae, and the lungs. If metastases to the pelvis or lumbar vertebrae have occurred, bony lysis will often be noted radiographically. Metastasis to the liver, brain, kidney and spleen may occur. A definitive diagnosis of a prostatic neoplasm can be achieved through biopsy as well as fine needle aspiration (FNA) or through ultrasound-guided traumatic catheterization.

A complete and thorough workup includes a CBC, biochemical profile, urinalysis, as well as three radiographic views of the thorax, an abdominal ultrasound, and an ultrasound-guided prostatic biopsy or FNA, if indicated. Urinalysis may reveal hematuria and pyuria. Prostatic fluid analysis can also be helpful in identifying neoplastic cells.

Treatment: Unfortunately, once diagnosed, prostatic carcinoma offers a poor prognosis; prostatectomy, chemotherapy, and radiation therapy have proven unsuccessful in improving quality or length of life. Nonsteroidal anti-inflammatory drugs (NSAIDs), such as deracoxib, meloxicam, and piroxicam, have been used for their palliative, anti-neoplastic properties with prostatic carcinomas.



PATIENT

Brody Starnella

SPECIES

Canine

BREED

Yorkshire Terrier

SEX

Neutered Male

AGE

15 Years

WEIGHT

9.0 Pounds

INTERPRETED BY

Eric Lindquist, DMV

DABVP, Cert. IVUSS

IMAGING PERFORMED BY

Val Shumskaya

HOSPITAL NAME

Englewood Vet Center

REFERRING VET

Dr. Ezik

INVOICE

23560

DATE

7/21/23

Certain tumors, including various carcinomas (e.g. TCC, prostatic carcinoma, mammary carcinoma, squamous cell carcinoma) overexpress COX-2, which converts arachidonic acid to prostaglandin G2 (PGG2)/prostaglandin H2 (PGH2), and ultimately to prostaglandin E₂ (PGE₂). The metabolite, PGE₂, is associated with increased inflammation, tumor invasiveness, angiogenesis, and reduced apoptosis. In vivo and in vitro, NSAIDs inhibit COX-2, resulting in the suppression of PGE₂, and thereby inhibiting tumor growth and metastasis. This effect has been achieved with both non-selective COX inhibitors as well as COX-2 inhibitors (the latter will suppress COX-1 at increased doses).

Some cases of prostatic carcinoma are managed palliatively with cyst/abscess ultrasound-guided drainage, antibiotic infusion, systemic antibiotics, and NSAID treatment and/or chemotherapy. Anecdotally, it has been observed that patients that often present clinical signs of hematuria or dysuria owing to cyst or abscess formation may be treated with repeat ultrasound-guided drainage. This appears to work especially well if there is a considerable cystic component to the prostatic tumor. The key is to image the prostate adequately, drain any cysts that are present, sample the abnormal parenchyma (FNA or biopsy), and potentially infuse antibiotics directly into the cystic cavities if a suppurative fluid is retrieved. The patient should be monitored clinically over time and reevaluated to see if cysts recur. Every case responds differently to treatment, and the behavior of parenchymal and cystic growth will vary.

Currently, investigational studies involving fluoroscopic-guided direct chemotherapeutic embolization through the iliac arteries as well as urethral stent placement are offered by select tertiary veterinary facilities that have an interventional radiology department. Ultrasound-guided endoscopic diode laser ablation through a perineal urethrostomy is also being attempted as a salvage and palliative procedure.

Conclusion: Prostatic neoplasia is more commonly detected in neutered male dogs than intact males. Diagnosis is typically obtained using ultrasound, cytology, and histopathology. Unfortunately, traditional therapy typically yields a guarded to poor long-term prognosis, but palliation with NSAIDs and/or chemotherapy can temporarily improve clinical signs. Investigational techniques may provide additional therapeutic options but are currently experimental.

References:

Cerf DJ, Lindquist EC. Palliative ultrasound-guided endoscopic laser ablation of transitional cell carcinomas of the lower urinary tract in dogs. *J Am Vet Med Assoc* 2012;240(1):51-60.

Culp, WTN. Interventional oncology and the management of urinary tract cancer. Proceedings from the American College of Veterinary Internal Medicine, New Orleans, LA, May 30-June 2, 2012.



PATIENT

Francey T. Prostatic Diseases. In: Ettinger SJ, Feldman EC, eds. *Textbook of Veterinary Internal Medicine 7th ed.* Philadelphia, PA: WB Saunders; 2010:2047-58.

Brody Starnella

SPECIES

Hecht S. Male Reproductive Tract. In: Pennick D, D'Anjou MA, eds. *Atlas of Small Animal Ultrasonography.* Ames, IA: Blackwell Publishing; 2008:417-43.

Canine

BREED

Milner RJ. Do NSAIDs make a difference in cancer. Proceedings from the American College of Veterinary Internal Medicine, Denver, CO, June 15-18, 2011.

Yorkshire Terrier

SEX

Mohammed SI, Khan KN, Sellers RS, et al. Expression of cyclooxygenase-1 and 2 in naturally-occurring canine cancer. *Prostag Leukotr Ess* 2004;70(5):479-83.

Neutered Male

Nyland, TG, Mattoon JS. *Small Animal Diagnostic Ultrasound 2nd ed.* Philadelphia, PA: WB Saunders; 2002:250-66.

AGE

Sorenmo KU, Goldschmidt MH, Shofer FS, et al. Evaluation of cyclooxygenase-1 and cyclooxygenase-2 expression and the effect of cyclooxygenase inhibitors in canine prostatic carcinoma. *Vet Comp Oncol* 2004;2(1):13-23.

15 Years

WEIGHT

9.0 Pounds

INTERPRETED BY

Eric Lindquist, DMV

DABVP, Cert. IVUSS

IMAGING PERFORMED BY

Val Shumskaya

HOSPITAL NAME

Englewood Vet Center

REFERRING VET

Dr. Ezik

INVOICE

23560

DATE

7/21/23