



PATIENT

PRESENTING CLINICAL SIGNS

Tide Wood

History: xrays show a rock in colon, is there any perforation?

SPECIES

ULTRASONOGRAPHIC EXAMINATION OF THE ABDOMEN

Canine

Urinary System

BREED

Pit Bull

The **urinary bladder**, trigone, and pelvic urethra presented normal thicknesses and normal tone. The pelvic urethra was imaged 2.0 cm beyond the cystourethral junction and appeared normal. The ureters were not visible which is normal. No uroliths or sediment were visualized and anechoic urine was present. No evidence of inflammatory or neoplastic changes was noted. Ureteral papillae were normal.

SEX

Neutered male

The **kidneys** revealed normal size and structure, corticomedullary definition and ratio for this age. The cortices presented largely uniform texture with normal echogenic relationship to liver and spleen. Medullary structure differed distinctly from the cortex and no evidence of pelvic dilation was present. The capsules were acceptably uniform without significant irregularities. The left kidney measured 6.9 cm. The right kidney measured 6.6 cm.

AGE

5 years

Adrenal Glands

WEIGHT

55 lbs

Both **adrenal glands** were visualized and recognized as having normal shape, size, position and echogenicity for this breed. The phrenic vasculature, glandular echogenicity and detail were unremarkable. Capsule, cortex, and medullary definition were normal for this age patient. The right adrenal gland measured 1.86 x 0.59 cm at the caudal pole and 0.74 cm at the cranial pole. The left adrenal gland measured 1.68 x 0.42 cm at the caudal pole and 0.53 cm at the cranial pole.

INTERPRETED BY

Eric Lindquist, DMV
DABVP, Cert. IVUSS

Spleen

IMAGING PERFORMED BY

Jenn

The **spleen** revealed mixed, echogenic parenchymal mass that measured 3.0 cm with a focal, hyperechoic portion of fibrosis or lipogranuloma. This is likely benign; however, it is precarious for potential torsion. A separate splenic swelling/nodule is noted and measured 2.5 cm in the midbody.

HOSPITAL NAME

Rockaway AH

Liver

REFERRING VET

Dr. Maniar

The **liver** images submitted revealed subjectively normal liver size, contour, and structure. Parenchymal echogenicity was naturally coarse and hypoechoic to the spleen. Vascular and biliary tracts were of normal volume with no evidence of congestion. The gallbladder presented acceptably thin walls with primarily anechoic content. The cystic and common bile ducts were normal. No pathological hepatic lymphadenopathy was evident. No overt structural evidence of inflammatory, infiltrative or regenerative pathology was evident.

INVOICE

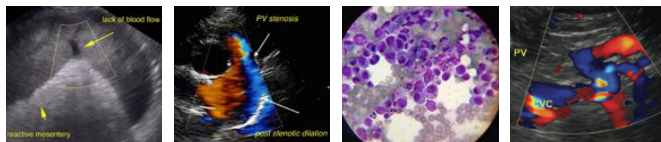
31849

Gastrointestinal

DATE

7/21/22

Examination of the **gastrointestinal tract** revealed a stomach and intestine free of stasis, of normal wall thickness, acceptable curvilinear mural detail, and peristaltic activity. Some retention of ingesta was noted in the stomach. Small and large intestine demonstrated normal luminal chyme and stool



PATIENT

Tide Wood

consistency respectively. The visible descending colon was unremarkable other than hard stool. No obstructive or overt infiltrative disease was noted. No associated abnormal lymphatic activity was noted.

SPECIES

Canine

Pancreas

The base and limbs of the **pancreas** were observed to be largely isoechoic to surrounding omental fat. Pancreatic duct and capsular contour were acceptably normal and parenchyma respected normal curvilinear patterns. No overt evidence of active inflammatory or neoplastic disease was noted.

BREED

Pit Bull

SEX

Neutered male

Heart

Rapid view of the heart revealed no evidence of pathology.

AGE

5 years

ULTRASONOGRAPHIC FINDINGS

Splenic mass and nodule.

WEIGHT

55 lbs

INTERPRETATION OF THE FINDINGS & FURTHER RECOMMENDATIONS

I recommend proactive splenectomy. Chest radiographs followed by splenectomy and manual palpation of the colon would be indicated.

INTERPRETED BY

Eric Lindquist, DMV
DABVP, Cert. IVUSS

IMAGING PERFORMED BY

Jenn

HOSPITAL NAME

Rockaway AH

REFERRING VET

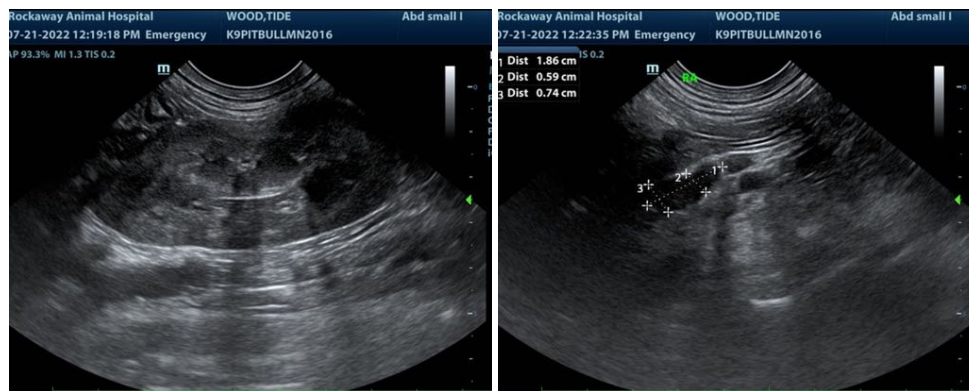
Dr. Maniar

INVOICE

31849

DATE

7/21/22





PATIENT

Tide Wood

SPECIES

Canine

BREED

Pit Bull

SEX

Neutered male

AGE

5 years

WEIGHT

55 lbs

INTERPRETED BY

Eric Lindquist, DMV
DABVP, Cert. IVUSS

IMAGING PERFORMED BY

Jenn

HOSPITAL NAME

Rockaway AH

REFERRING VET

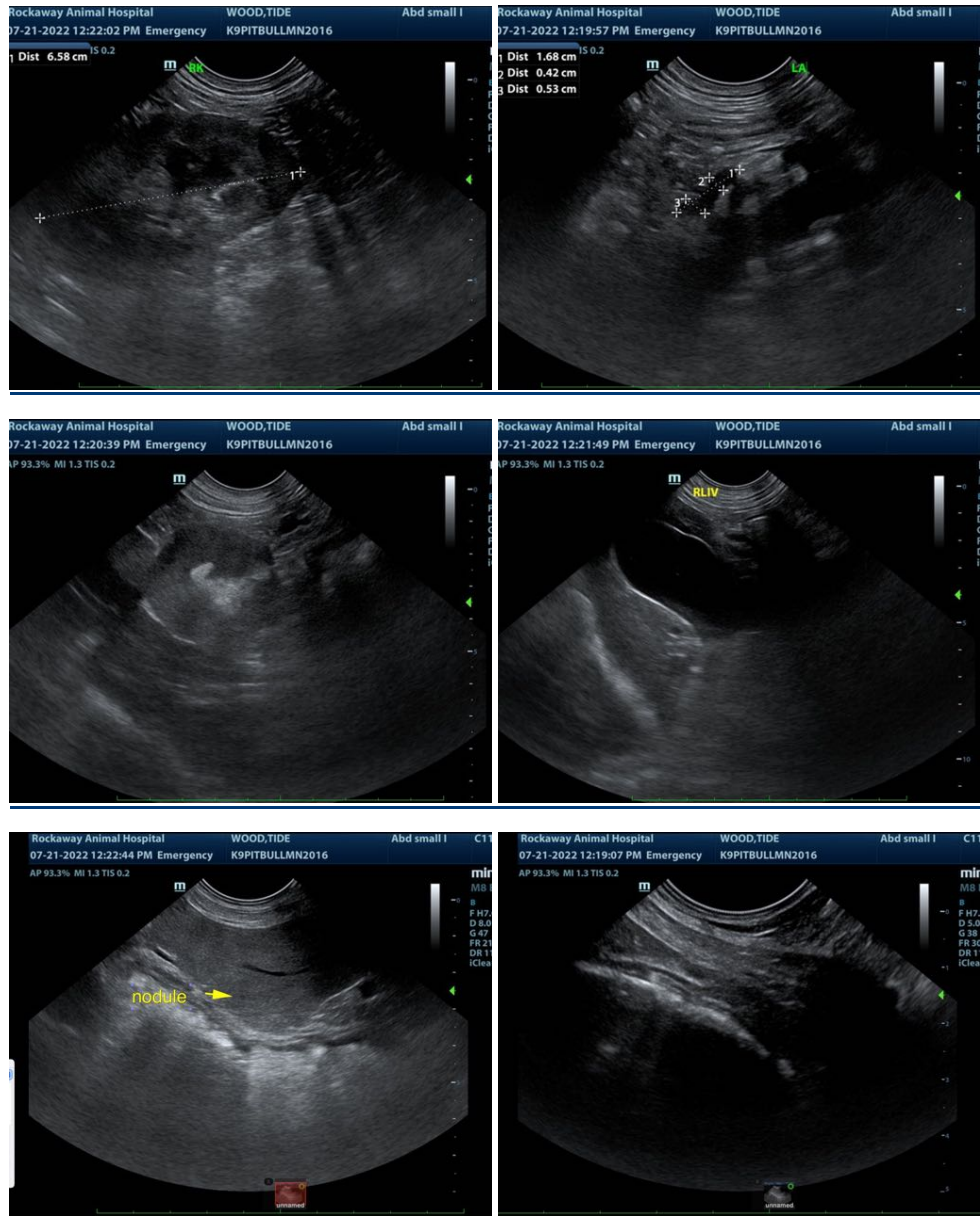
Dr. Maniar

INVOICE

31849

DATE

7/21/22



The information and recommendations provided are based on the images presented by the referring veterinarian/sonographer. No evaluation can be communicated regarding pathology that was not visible in the image/video clips provided.

Thank you for this referral. If the clinical or image interpretation does not parallel your findings or if I can be of any further assistance please contact me.

Eric Lindquist, DMV, DABVP, Cert. IVUSS, CEO of SonoPath.com
info@SonoPath.com