



**PATIENT**

Hobie McDivitt

**SPECIES**

Canine

**BREED**

Poodle Schnauzer Mix

**SEX**

Neutered male

**AGE**

11 years

**WEIGHT**

8.4 kg

**INTERPRETED BY**

Eric Lindquist, DMV  
DABVP, Cert. IVUS

**IMAGING PERFORMED BY**

Dr. Stegemoller

**HOSPITAL NAME**

North Idaho AH

**REFERRING VET**

Dr. Neher

**INVOICE**

31881

**DATE**

7/21/22

**PRESENTING CLINICAL SIGNS**

History: Followup echo after recommendation from last sonopath report.  
Abnormal PE/Chem/CBC/UA Results: Blood pressure: 173/98 MAP 124 Creat and BUN elevated at prior echocardiogram, both normal today. Creat is 0.6, BUN is 12.

**ULTRASONOGRAPHIC EXAMINATION OF THE HEART**

The echocardiogram in this patient presented mild volume overload of the left atrium and left ventricle. The internal volume was fairly normal. Contractility was adequate in this patient. Mitral insufficiency is persistent with minor prolapse. No hepatic vein dilation was noted. No hepatic vein dilation was noted. The right atrium, tricuspid valve and right ventricle are unremarkable. There is no pericardial effusion.

CANINE CARDIAC PARAMETERS	MR VMAX (m/s)	TR VMAX (m/s)	LA/AO (Boon method)	LA/AO (Heart Base; Swe)	FS (%)	EF (%)	EPSS (cm)
NORMAL PARAMETER	4.5-5.5	<2.7	1.3	<1.6	28-40	40-100	<0.6
PATIENT	5.5		1.4	2.0	55	90	0.1
CANINE CARDIAC PARAMETERS	HR (BPM)	AV VMAX (m/s)	PV MAX (m/s)	BODY WEIGHT (kg)	LA (2D short axis Base view) (cm)	LVIDd (Avg; 2D and m-mode short axis) (cm)	LVIDs (Avg; 2D and m-mode short axis) (cm)
NORMAL PARAMETER	50-100	0.7-1.7	0.7-1.6	BELOW	BELOW	BELOW	BELOW
PATIENT	110		1.3	8.4	3.8 max	3.58	

**ULTRASONOGRAPHIC FINDINGS**

Largely compensated stage B2 valvular disease.

**INTERPRETATION OF THE FINDINGS & FURTHER RECOMMENDATIONS**

An abdominal sonogram is recommended to assess the cause of azotemia. No adjustment on cardiac medications are warranted unless adjustment for azotemia needs to occur. Recheck echocardiogram is recommended in 6 months.



**PATIENT**

Hobie McDivitt

**SPECIES**

Canine

**BREED**

Poodle Schnauzer Mix

**SEX**

Neutered male

**AGE**

11 years

**WEIGHT**

8.4 kg

**INTERPRETED BY**

Eric Lindquist, DMV  
DABVP, Cert. IVUSS

**IMAGING PERFORMED BY**

Dr. Stegemoller

**HOSPITAL NAME**

North Idaho AH

**REFERRING VET**

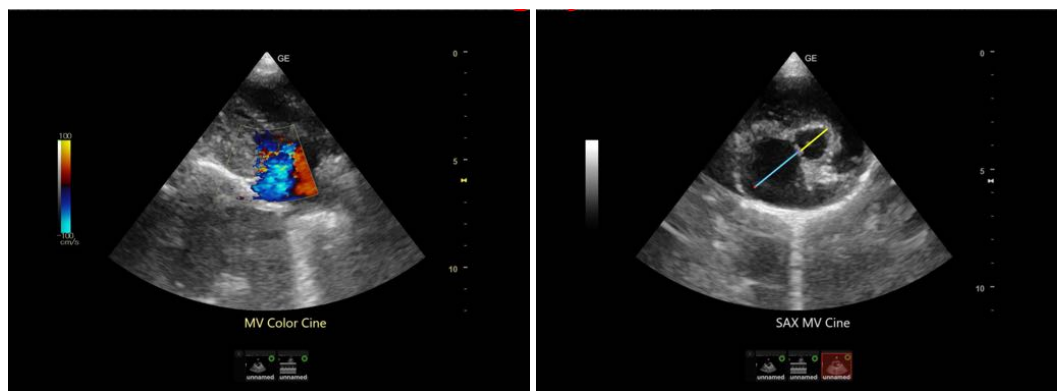
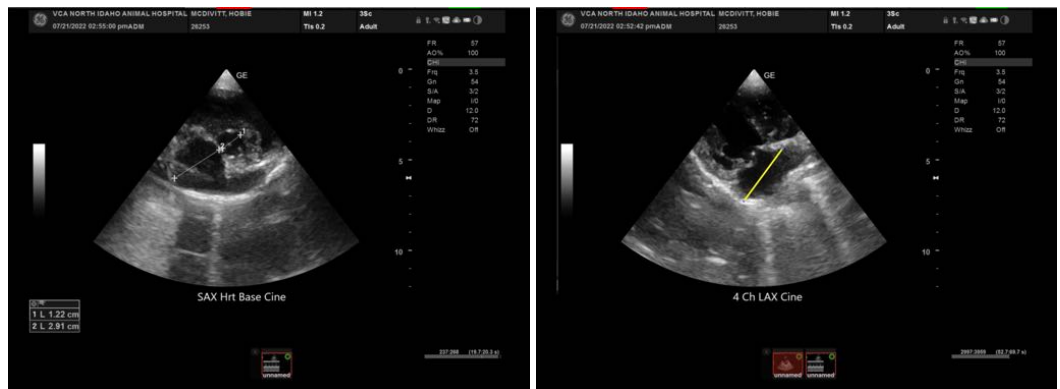
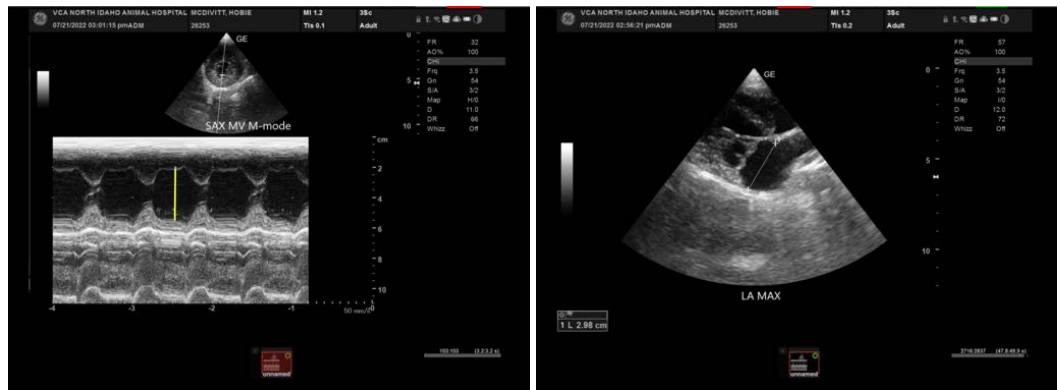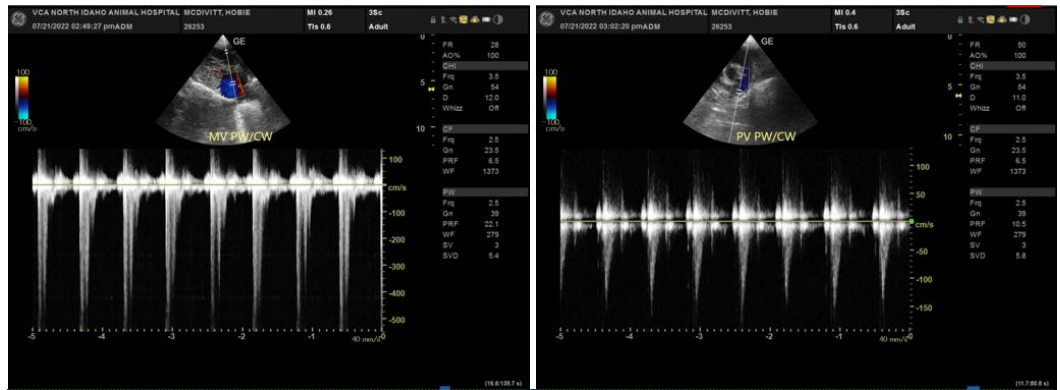
Dr. Neher

**INVOICE**

31881

**DATE**

7/21/22





**PATIENT**

Hobie McDivitt

The information and recommendations provided are based on the images presented by the referring veterinarian/sonographer. No evaluation can be communicated regarding pathology that was not visible in the image/video clips provided.

**SPECIES**

Canine

Thank you for this referral. If the clinical or image interpretation does not parallel your findings or if I can be of any further assistance please contact me.

**BREED**

Poodle Schnauzer Mix

**Eric Lindquist**, DMV, DABVP, Cert. IVUSS, CEO of SonoPath.com  
info@SonoPath.com

**SEX**

Neutered male

**AGE**

11 years

**WEIGHT**

8.4 kg

**INTERPRETED BY**

Eric Lindquist, DMV  
DABVP, Cert. IVUSS

**IMAGING  
PERFORMED BY**

Dr. Stegemoller

**HOSPITAL NAME**

North Idaho AH

**REFERRING VET**

Dr. Neher

**INVOICE**

31881

**DATE**

7/21/22