



**PATIENT**

Elliot Battifarano

**SPECIES**

Canine

**BREED**

Toy Poodle

**SEX**

Neutered Male

**AGE**

9 Years 11 Months

**WEIGHT**

6.94 Pounds

**PRESENTING CLINICAL SIGNS**

History: Grade II/VI systolic heart murmur

Abnormal PE/Chem/CBC/UA Results: Grade II/VI systolic heart murmur

**ULTRASONOGRAPHIC EXAMINATION OF THE HEART**

CANINE CARDIAC PARAMETERS	MR VMAX (m/s)	TR VMAX (m/s)	LA/AO (Boon method)	LA/AO (Heart Base; Swe)	FS (%)	EF (%)	EPSS (cm)
NORMAL PARAMETER	4.5-5.5	<2.7	1.3	<1.6	28-40	40-100	<0.6
PATIENT	--	--	1.0	1.3	35	80	0.1
CANINE CARDIAC PARAMETERS	HR (BPM)	AV VMAX (m/s)	PV MAX (m/s)	BODY WEIGHT (kg)	LA 2D short axis Base view (cm)	LVIDd Avg; 2D and m-mode short axis (cm)	LVIDs Avg; 2D and m-mode short axis (cm)
NORMAL PARAMETER	50-100	0.7-1.7	0.7-1.6				
PATIENT	--	1.30	--	--	1.54	1.7	--

**INTERPRETED BY**

Eric Lindquist, DMV DABVP, Cert. IVUSS

**IMAGING PERFORMED BY**

Dr. Gillian Striano-Kaplan

**HOSPITAL NAME**

Ramsey VH

**REFERRING VET**

Dr. Gillian Striano-Kaplan

**INVOICE**

23531

**DATE**

7/20/23

**Cardiac Presentation**

The echocardiogram in this patient demonstrated normal **left atrial** size based on 3 different LA measurement methods. Chamber volumes and echogenicity were normal. The cranial and caudal **mitral** valve leaflets presented vegetative thickening consistent with endocardiosis. Doppler indicated measurable insufficiency. The **left ventricle** presented thicknesses with linear contour and was not dilated nor restricted. The **myocardium** presented normal echogenicity without subjective evidence of significant fibrotic or ischemic disease. **Contractility** of the ventricular walls was adequate and in normal range for this patient evidenced by the fractional shortening measurement and subjective evaluation of the different regions of the myocardium. The **left ventricular outflow** tract demonstrated normal laminar flow and subjective structural integrity. The **right atrium** and auricle revealed normal size, structure and content. No evidence of masses was noted or chamber overload. **Tricuspid** valvular assessment demonstrated adequate linear morphology. The **right ventricle** was of normal size (1/3 diameter of LV), chordae structure, myocardial echogenicity and thickness. **Pulmonic** tract assessment revealed normal valve structure, laminar flow, and diameter (approx.1:1 pa/ao ratio). No visible **pericardial** or free pleura fluid was noted. No echographically detectable evidence of infiltrative disease was visible. The cranial **mediastinum and pericardial regions** were free of masses in the visible window. Arrhythmogenic activity was noted- EKG is indicated.

**ULTRASONOGRAPHIC FINDINGS**

- Stage B-1 valvular disease, compensated
- Arrythmia



**PATIENT**

Elliot Battifarano

**INTERPRETATION OF THE FINDINGS & FURTHER RECOMMENDATIONS**

EKG is indicated. Blood pressures are indicated.

**SPECIES**

Canine

**BREED**

Toy Poodle

**SEX**

Neutered Male

**AGE**

9 Years 11 Months

**WEIGHT**

6.94 Pounds

**INTERPRETED BY**

Eric Lindquist, DMV  
DABVP, Cert. IVUSS

**IMAGING PERFORMED BY**

Dr. Gillian Striano-Kaplan

**HOSPITAL NAME**

Ramsey VH

**REFERRING VET**

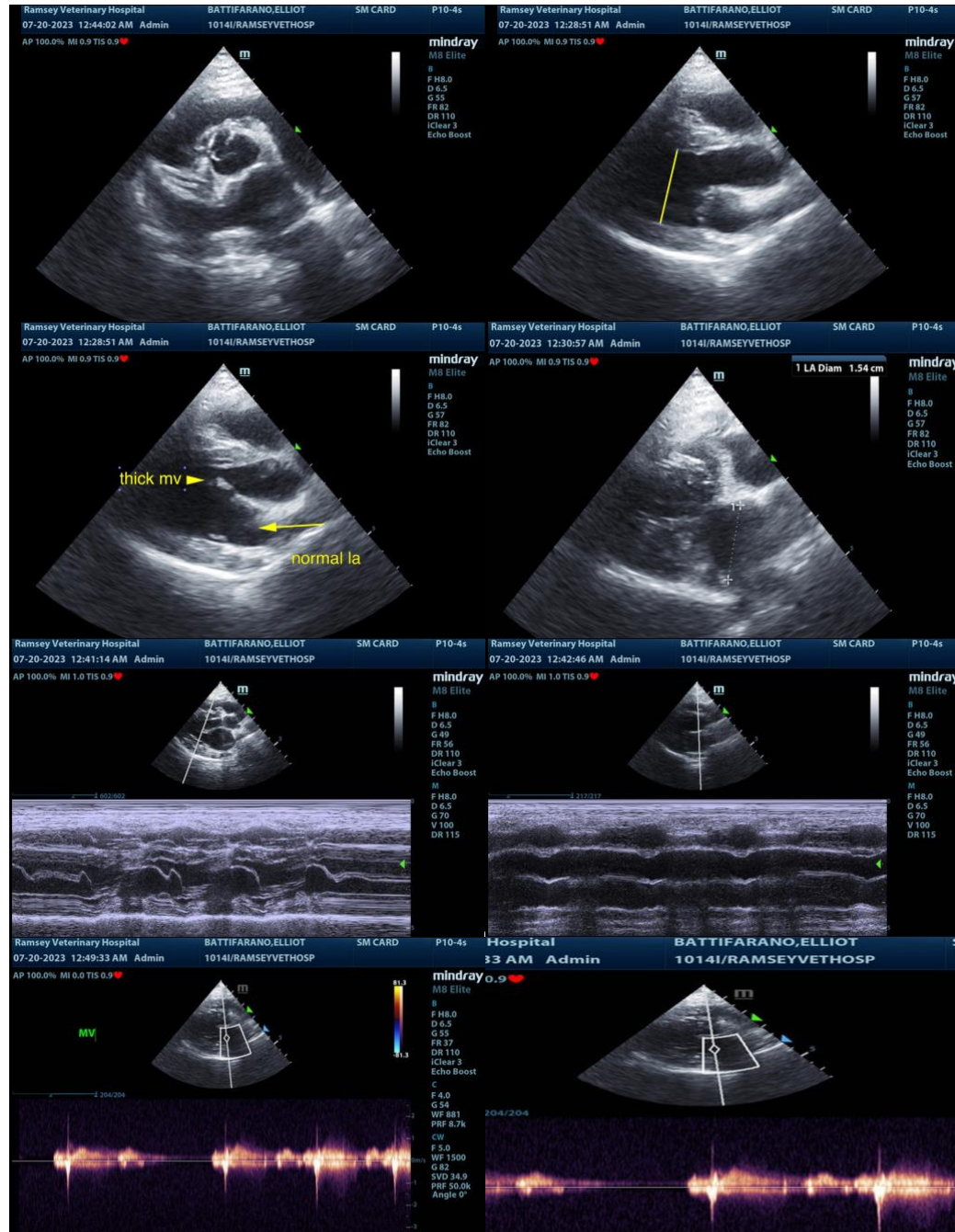
Dr. Gillian Striano-Kaplan

**INVOICE**

23531

**DATE**

7/20/23



The information and recommendations provided are based on the images presented by the referring veterinarian. No evaluation can be communicated regarding pathology that was not visible in the image/video clips provided.



**PATIENT**

Elliot Battifarano

Thank you for this referral. If the clinical or image interpretation does not parallel your findings or if I can be of any further assistance please contact me.

**SPECIES**

Canine

**Eric Lindquist**, DMV, DABVP, Cert. IVUSS, CEO of SonoPath.com  
info@SonoPath.com

**BREED**

Toy Poodle

**SEX**

Neutered Male

**AGE**

9 Years 11 Months

**WEIGHT**

6.94 Pounds

**INTERPRETED BY**

Eric Lindquist, DMV  
DABVP, Cert. IVUSS

**IMAGING  
PERFORMED BY**

Dr. Gillian Striano-  
Kaplan

**HOSPITAL NAME**

Ramsey VH

**REFERRING VET**

Dr. Gillian Striano-  
Kaplan

**INVOICE**

23531

**DATE**

7/20/23