



PATIENT

Astrid Dellaporta

SPECIES

Canine

BREED

Pitbull

SEX

Spayed Female

AGE

20 Months

WEIGHT

26.6 kg

INTERPRETED BY

Eric Lindquist, DMV
DABVP, Cert. IVUSS

IMAGING PERFORMED BY

Erin Wicks

HOSPITAL NAME

Shores VEC

REFERRING VET

Dr. Miller

INVOICE

23521

DATE

7/20/23

PRESENTING CLINICAL SIGNS

Presented at our hospital for Having to pee every 20 mins P has a hooded vulva and has been on medication for frequent UTI's p is not overly drinking water and still has to go to the bathroom every 20 to 30 minutes. Owner wipes pet after every urination to prevent infections. Previous Health Concerns: hooded vulva, parvo Current Medications: doxycycline 100mg 1 ½ tablet BID Appetite/When did they eat last: this am

Abnormal PE/Chem/CBC/UA Results: 03/17/23 UA(free catch): PH 5.0; SG 1.050; Ascorbic Acid 40; cocci present.

ULTRASONOGRAPHIC EXAMINATION OF THE ABDOMEN

Urinary System

The **urinary bladder**, trigone, and pelvic urethra presented normal thicknesses and normal tone. The ureters were not visible which is normal. No uroliths or sediment were visualized and anechoic urine was present. No evidence of inflammatory or neoplastic changes were noted. Ureteral papillae were normal. The pelvic urethra was imaged 2.0 cm beyond the cystourethral junction. No evidence of ectopic ureters.

The **kidneys** revealed normal size and structure, corticomedullary definition and ratio for this age. The cortices presented largely uniform texture with normal echogenic relationship to liver and spleen. Medullary structure differed distinctly from the cortex and no evidence of pelvic dilation was present. The capsules were acceptably uniform without significant irregularities. The right kidney measured 7.1 cm. The left kidney measured 6.35 cm.

Adrenal Glands

Both **adrenal glands** were visualized and recognized as having normal shape, size, position and echogenicity for this breed. The phrenic vasculature, glandular echogenicity and detail were unremarkable. Capsule, cortex, and medullary definition were normal for this age patient. The left adrenal gland measured 0.5 cm. The right adrenal gland measured 0.6 cm at the cranial pole and 0.4 cm at the caudal pole.

Spleen

The **spleen** presented a smooth homogeneous parenchyma hyperechoic to liver and renal cortical parenchyma. The capsule was smooth without noticeable expansion or deviation from within the spleen or adjacent pathology. The splenic vasculature demonstrated normal volume without signs of congestion or thrombosis. No sonographic evidence of acute or chronic inflammatory, neoplastic, or infarctual changes were noted.

Liver

The **liver** images submitted revealed subjectively normal liver size, contour, and structure. Parenchymal echogenicity was naturally coarse and hypoechoic to the spleen. Vascular and biliary tracts were of normal volume with no evidence of congestion. The gallbladder presented acceptably thin walls with primarily anechoic content. The cystic and common bile ducts were normal. No pathological hepatic lymphadenopathy was evident. No overt structural evidence of inflammatory, infiltrative or regenerative pathology was evident.

Gastrointestinal



PATIENT

Astrid Dellaporta

There was some residual chyme and gas was noted in the **stomach**, yet not pathological. This is consistent with end post prandial presentation. Transit of chyme into the small intestine was normal. Curvilinear patterns were maintained throughout the GI tract. No evidence of pathology. Small and large intestine demonstrated normal luminal chyme and stool consistency respectively. No obstructive or overt infiltrative disease was noted. No associated abnormal lymphatic activity was noted.

SPECIES

Canine

Pancreas

BREED

Pitbull

The base and limbs of the **pancreas** were observed to be largely isoechoic to surrounding omental fat. Pancreatic duct and capsular contour were acceptably normal and parenchyma respected normal curvilinear patterns. No overt evidence of active inflammatory or neoplastic disease was noted.

SEX

Spayed Female

- Structurally normal abdomen and urinary tract

ULTRASONOGRAPHIC FINDINGS

INTERPRETATION OF THE FINDINGS & FURTHER RECOMMENDATIONS

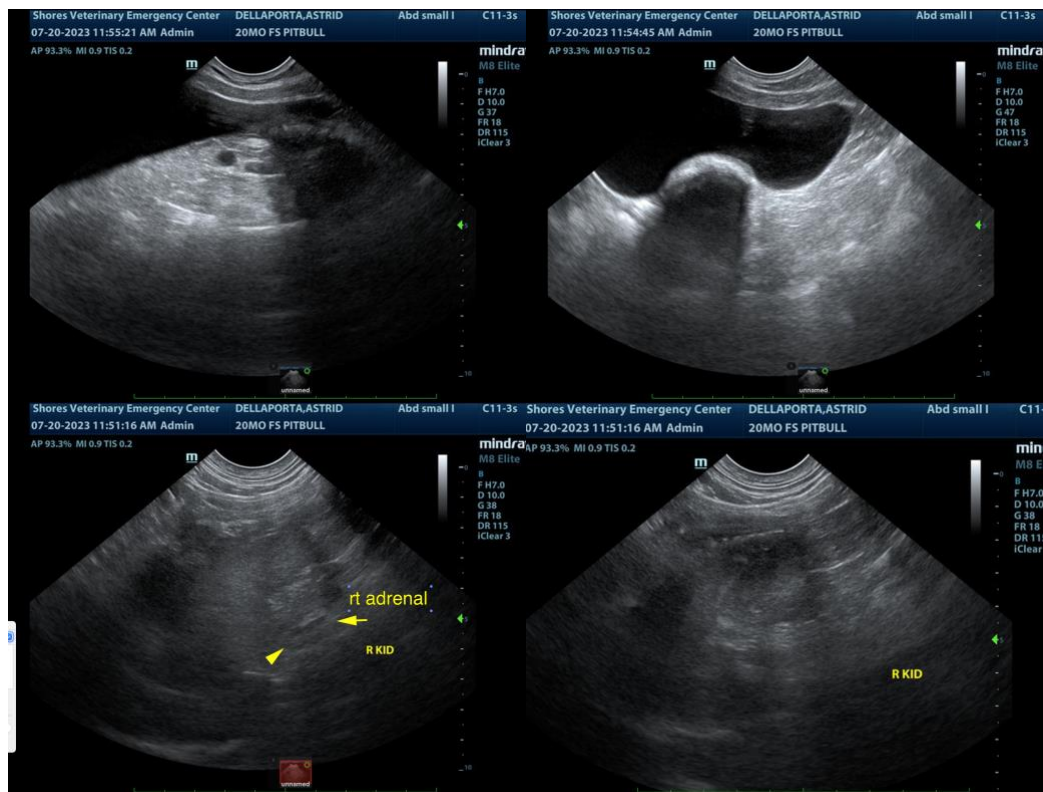
AGE

20 Months

Behavioral issues should be considered. Examination of the vaginal vestibule for pyoderma and urine pooling is warranted, yet structurally, the urinary tract is unremarkable. If isosthenuria is an issue, then partial water deprivation test is indicated to assess the ability to concentrate.

WEIGHT

26.6 kg



INTERPRETED BY

Eric Lindquist, DMV
DABVP, Cert. IVUSS

IMAGING PERFORMED BY

Erin Wicks

HOSPITAL NAME

Shores VEC

REFERRING VET

Dr. Miller

INVOICE

23521

DATE

7/20/23



PATIENT

Astrid Dellaporta

SPECIES

Canine

BREED

Pitbull

SEX

Spayed Female

AGE

20 Months

WEIGHT

26.6 kg

INTERPRETED BY

Eric Lindquist, DMV
DABVP, Cert. IVUSS

IMAGING PERFORMED BY

Erin Wicks

HOSPITAL NAME

Shores VEC

REFERRING VET

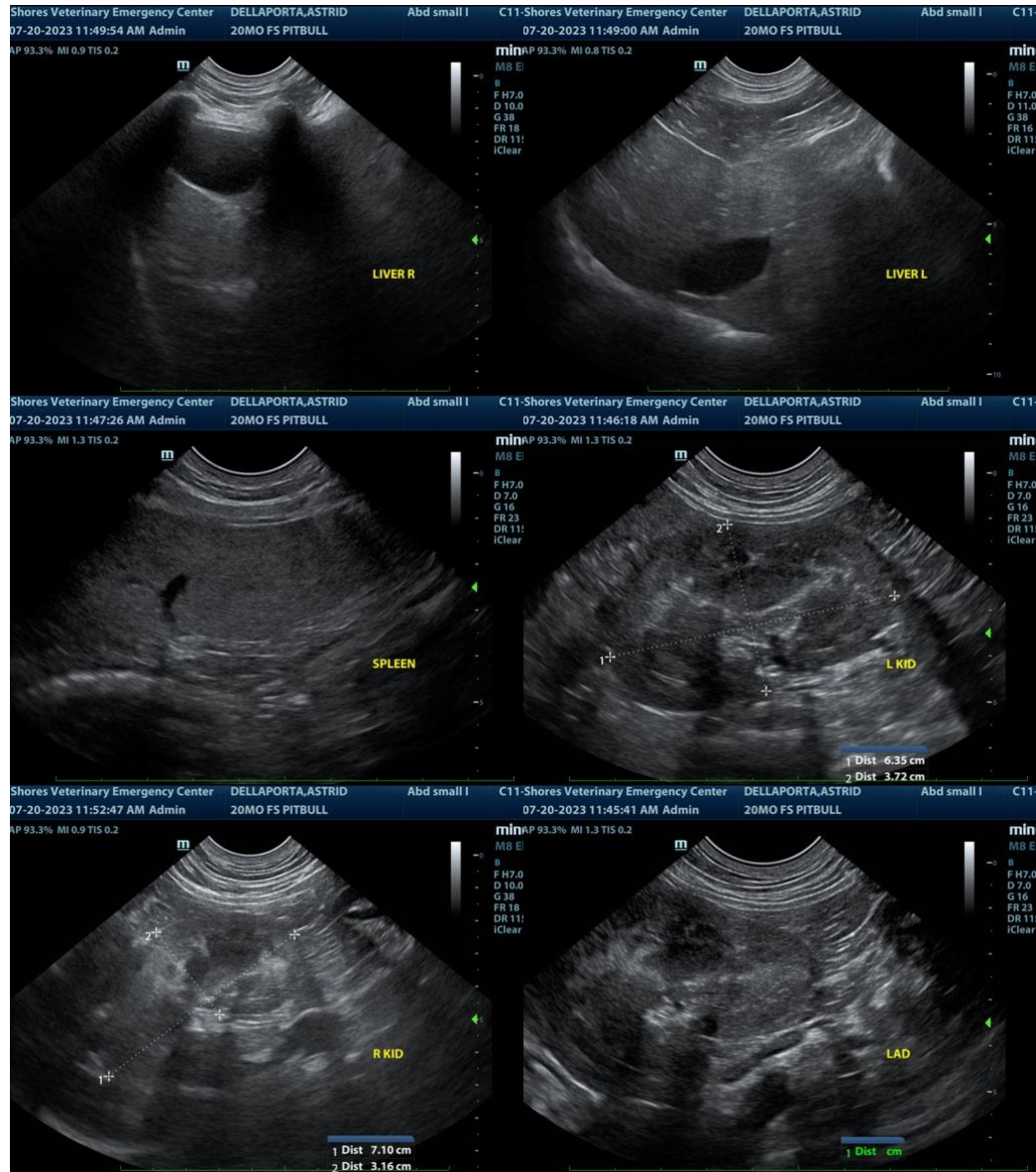
Dr. Miller

INVOICE

23521

DATE

7/20/23



The information and recommendations provided are based on the images presented by the referring veterinarian. No evaluation can be communicated regarding pathology that was not visible in the image/video clips provided.

Thank you for this referral. If the clinical or image interpretation does not parallel your findings or if I can be of any further assistance please contact me.

Eric Lindquist, DMV, DABVP, Cert. IVUSS, CEO of SonoPath.com
info@SonoPath.com