



PATIENT

Abbey Widmer

SPECIES

Canine

BREED

Pitbull Mix

SEX

Spayed Female

AGE

10 Years

WEIGHT

52.3 Pounds

INTERPRETED BY

Eric Lindquist, DMV
DABVP, Cert. IVUSS

**IMAGING
PERFORMED BY**

Michelle Bartus

HOSPITAL NAME

Valley Veterinary
Service, Inc.

REFERRING VET

Michelle Bartus

INVOICE

23522

DATE

7/20/23

PRESENTING CLINICAL SIGNS

Patient was examined by a relief veterinarian. Sudden onset of Hematuria and increased frequency of urination. Dog otherwise normal.

Abnormal PE/Chem/CBC/UA Results: U/A sp.gr. 1.018, pH 7.0, WBC 48, RBC>50, Pro 500, BL 250, no bacteria seen (Sedivue). No bloodwork was done.

ULTRASONOGRAPHIC EXAMINATION OF THE ABDOMEN

Urinary System

The **urinary bladder** presented a relatively uniform thickening of the cranioventral and craniodorsal mucosae with micropolypoid mucosal changes without involvement of the submucosae. The urine presented some echogenicity consistent with suspended debris. No evidence of urethral pathology was present. This presentation is most consistent with chronic cystitis. Technically transitional cell carcinoma cannot be ruled out without histopathological review but is not overtly suspected based on this pattern. Cystocentesis and urine culture +/- pathological review of urine cytology would be warranted. No overt calculi were present at this time. This is a mild change.

The **kidneys** revealed normal size and structure, corticomedullary definition and ratio for this age. The cortices presented largely uniform texture with normal echogenic relationship to liver and spleen. Medullary structure differed distinctly from the cortex and no evidence of pelvic dilation was present. The capsules were acceptably uniform without significant irregularities. The right kidney measured 5.7 cm. The left kidney measured 5.12 cm.

Adrenal Glands

Both **adrenal glands** were visualized and recognized as having normal shape, size, position and echogenicity for this breed. The phrenic vasculature, glandular echogenicity and detail were unremarkable. Capsule, cortex, and medullary definition were normal for this age patient.

Spleen

The **spleen** presented a smooth homogeneous parenchyma hyperechoic to liver and renal cortical parenchyma. The capsule was smooth without noticeable expansion or deviation from within the spleen or adjacent pathology. The splenic vasculature demonstrated normal volume without signs of congestion or thrombosis. No sonographic evidence of acute or chronic inflammatory, neoplastic, or infarctual changes were noted. Caudal folding of the spleen was noted.

Liver

The **liver** images submitted revealed subjectively normal liver size, contour, and structure. Parenchymal echogenicity was naturally coarse and hypoechoic to the spleen. Vascular and biliary tracts were of normal volume with no evidence of congestion. The gallbladder presented acceptably thin walls with primarily anechoic content. The cystic and common bile ducts were normal. No pathological hepatic lymphadenopathy was evident. No overt structural evidence of inflammatory, infiltrative or regenerative pathology was evident.

Gastrointestinal

Examination of the **gastrointestinal tract** revealed a stomach and intestine free of stasis, of normal wall thickness, acceptable curvilinear mural detail, and peristaltic activity. Small and large intestine



PATIENT

Abbey Widmer

demonstrated normal luminal chyme and stool consistency respectively. No obstructive or overt infiltrative disease was noted. No associated abnormal lymphatic activity was noted.

Pancreas

SPECIES

Canine

The base and limbs of the **pancreas** were observed to be largely isoechoic to surrounding omental fat. Pancreatic duct and capsular contour were acceptably normal and parenchyma respected normal curvilinear patterns. No overt evidence of active inflammatory or neoplastic disease was noted.

BREED

Pitbull Mix

ULTRASONOGRAPHIC FINDINGS

- Chronic cystitis bladder pattern- minimal potential for transitional cell carcinoma

SEX

Spayed Female

INTERPRETATION OF THE FINDINGS & FURTHER RECOMMENDATIONS

Cystoscopy and mucosal biopsies would be ideal. BRAF testing is indicated, if negative, then urine culture and sensitivity and 4-6 weeks antibiotic therapy is recommended. Given the pyuria, chronic cystitis is likely and will likely necessitate 4-6 weeks for clearance. Assessment for predisposing issues, such as recessed vulva and perivulvar pyoderma is indicated.

AGE

10 Years

WEIGHT

52.3 Pounds

INTERPRETED BY

Eric Lindquist, DMV
DABVP, Cert. IVUSS

**IMAGING
PERFORMED BY**

Michelle Bartus

HOSPITAL NAME

Valley Veterinary
Service, Inc.

REFERRING VET

Michelle Bartus

INVOICE

23522

DATE

7/20/23



PATIENT

Abbey Widmer

SPECIES

Canine

BREED

Pitbull Mix

SEX

Spayed Female

AGE

10 Years

WEIGHT

52.3 Pounds

INTERPRETED BY

Eric Lindquist, DMV
DABVP, Cert. IVUSS

IMAGING PERFORMED BY

Michelle Bartus

HOSPITAL NAME

Valley Veterinary
Service, Inc.

REFERRING VET

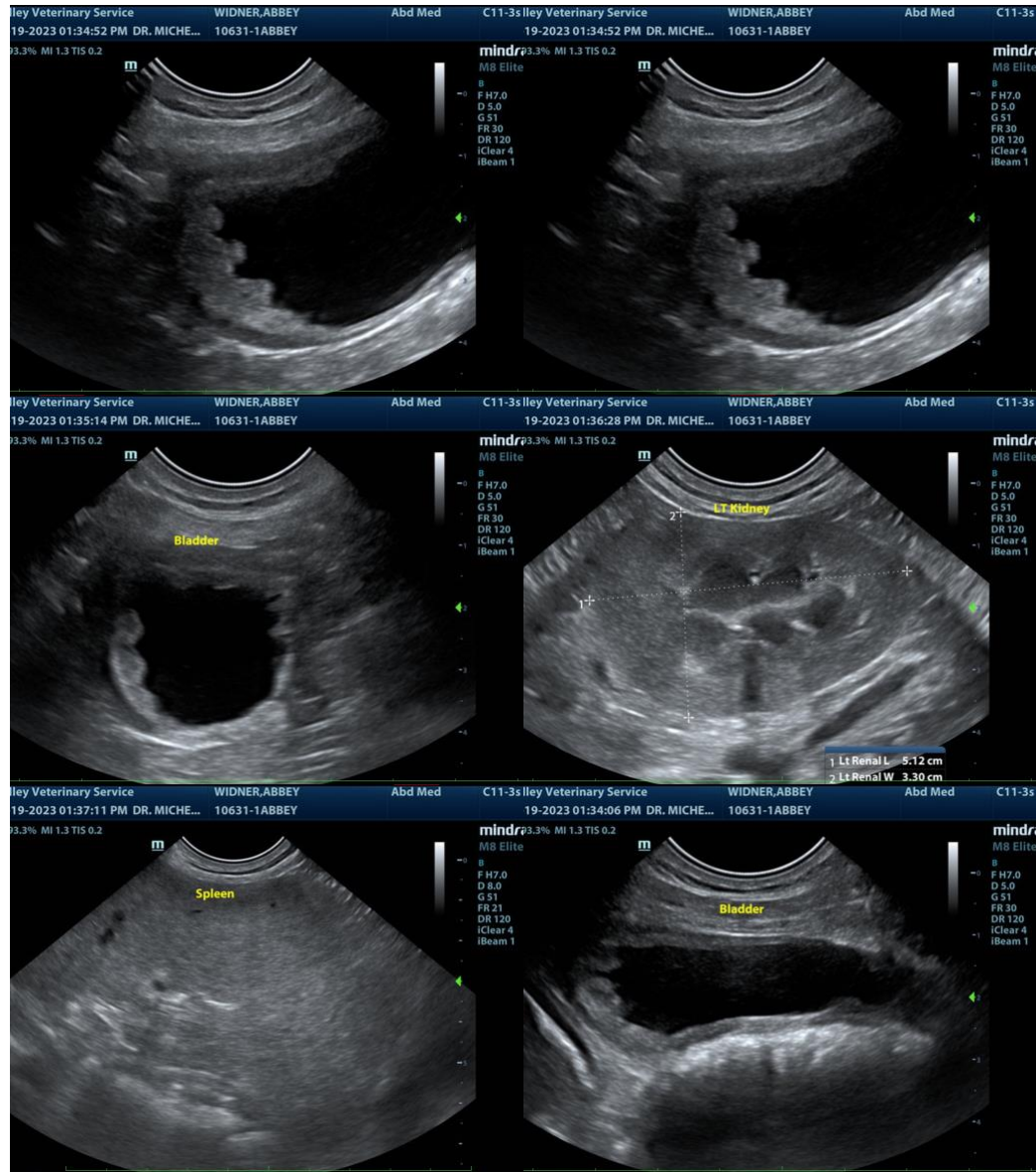
Michelle Bartus

INVOICE

23522

DATE

7/20/23



The information and recommendations provided are based on the images presented by the referring veterinarian. No evaluation can be communicated regarding pathology that was not visible in the image/video clips provided.

Thank you for this referral. If the clinical or image interpretation does not parallel your findings or if I can be of any further assistance please contact me.

Eric Lindquist, DMV, DABVP, Cert. IVUSS, CEO of SonoPath.com
info@SonoPath.com