

PATIENT

Truman Bird

SPECIES

Canine

BREED

Shih Tzu

SEX

Neutered Male

AGE

11 years

WEIGHT

26.6 Pounds

INTERPRETED BY

Eric Lindquist, DMV
DABVP, Cert. IUUSS

IMAGING PERFORMED BY

Rachel Runnells, RVT

HOSPITAL NAME

SVS Imaging Kansas
City

REFERRING VET

Dr. Mervin

INVOICE

31834

DATE

7/20/22

PRESENTING CLINICAL SIGNS

History: Firmish mass, 2 cm on left side of neck ventral to mandible a few inches. When pt is dorsal, mass is just L of trachea.

ULTRASONOGRAPHIC EXAMINATION

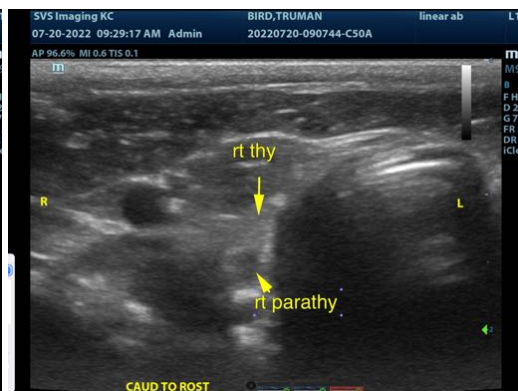
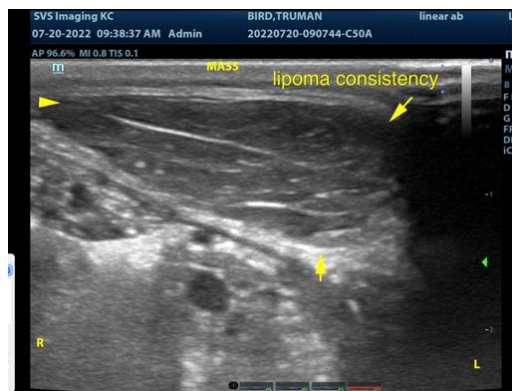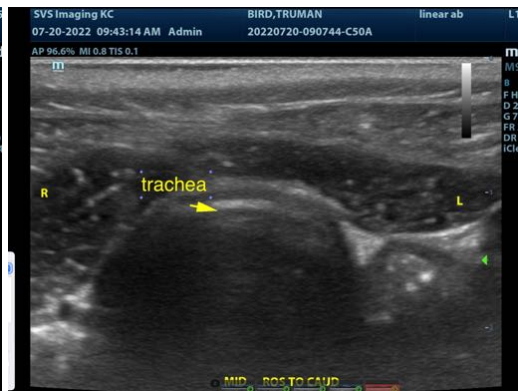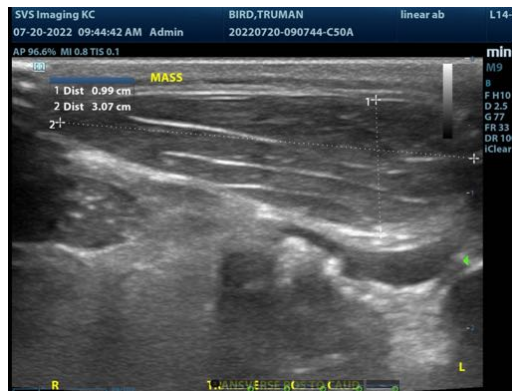The cervical region was imaged in this patient. Both thyroid lobes are uniform and measured 2.0 cm in maximum width with normal parathyroids up to 0.4 cm on the right and 0.2 cm on the left. The trachea, esophagus, regional salivary glands and lymph nodes were all normal. The right subcutaneous space revealed a lipomatous type mass that appears to be occupying subcutaneous position. The mass measures 3.0 x 1.0 cm. This does not appear pathological and is non-vascular.

ULTRASONOGRAPHIC FINDINGS

Subcutaneous mass, consistent with lipoma.

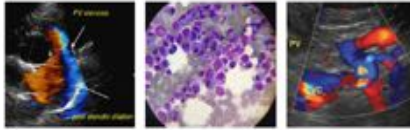
INTERPRETATION OF THE FINDINGS & FURTHER RECOMMENDATIONS

FNA can be considered for further definition. It does appear resectable and is well encapsulated.



IMAGING PERFORMED BY

SVS Mobile Imaging KC 816-401-5010
svsimagingkc@gmail.com



Clinical Sonography & Telectyology

EDUCATIONAL TELECONSULTATION SERVICES™

1-800-838-4268 info@sonopath.com SonoPath.com

PATIENT

Truman Bird

SPECIES

Canine

BREED

Shih Tzu

SEX

Neutered Male

AGE

11 years

WEIGHT

26.6 Pounds

INTERPRETED BY

Eric Lindquist, DMV
DABVP, Cert. IVUSS

IMAGING PERFORMED BY

Rachel Runnells, RVT

HOSPITAL NAME

SVS Imaging Kansas
City

REFERRING VET

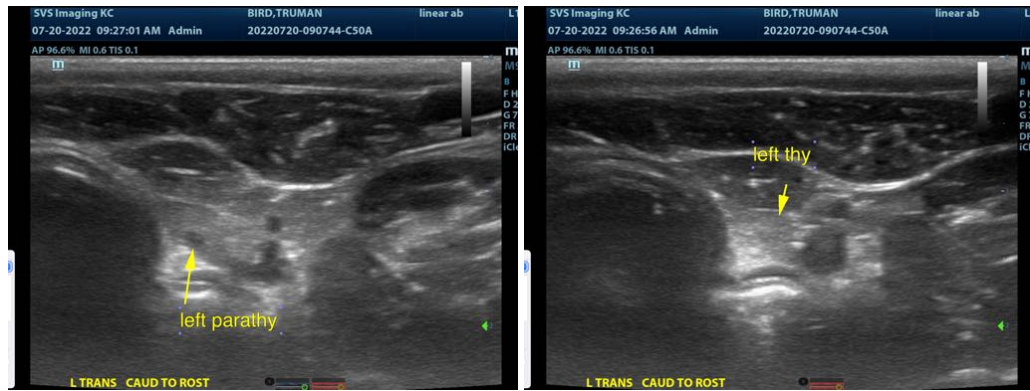
Dr. Mervin

INVOICE

31834

DATE

7/20/22



The information and recommendations provided are based on the images presented by the referring veterinarian/sonographer. No evaluation can be communicated regarding pathology that was not visible in the image/video clips provided.

Thank you for this referral. If the clinical or image interpretation does not parallel your findings or if I can be of any further assistance please contact me.

Eric Lindquist, DMV, DABVP, Cert. IVUSS, CEO of SonoPath.com
Eric.Lindquist@SonoPath.com