



PATIENT

Stella Ross

SPECIES

Feline

BREED

Domestic Longhair

SEX

Spayed female

AGE

11 years

WEIGHT

10.5 lbs

INTERPRETED BY

Eric Lindquist, DMV
DABVP, Cert. IVUSS

IMAGING PERFORMED BY

Dr. Rodriguez

HOSPITAL NAME

Foxfield VS

REFERRING VET

Dr. Rodriguez

PRESENTING CLINICAL SIGNS

History: Heart murmur 4/6
Abnormal PE/Chem/CBC/UA Results: WNL. T4: 2.5

ULTRASONOGRAPHIC EXAMINATION OF THE HEART

The echocardiogram in this patient demonstrated normal **left atrial** size and structure with no evidence of “smoke” or thrombi. The cranial and caudal **mitral** valve leaflets appeared mildly thickened with some insufficiency noted on Doppler. Systolic anterior motion was noted. The **left ventricle** presented excessive free wall and septal thicknesses with hypertrophic thicknesses compared to normal for this species. The **myocardium** presented essentially normal echogenicity without immediate signs of fibrotic or ischemic disease. **Contractility** of the ventricular walls was considered excessive for this patient evidenced by the elevated fractional shortening measurement. The **left ventricular outflow** tract demonstrated turbulent laminar flow. Subjective assessment of the **right atrium** and auricle revealed normal size, structure and content. No evidence of masses was noted. **Tricuspid** insufficiency was noted. The **right ventricle** was of normal size with normal chordae structure, myocardial echogenicity and thickness. **Pulmonic** tract assessment revealed normal valve structure, laminar flow, and diameter. No visible **pericardial** or free pleura fluid was noted. No echographically detectable evidence of infiltrative disease was visible. The **mediastinum** was free of masses in the visible window.

FELINE CARDIAC PARAMETERS	BODY WEIGHT (kg)	HR (BPM)	IVSd (cm)	LVIDd (cm)	LVWd (cm)	FS (%)	EF (%)
NORMAL PARAMETER	-----	150-240	0.3-0.6	1.0-2.1	0.25-0.6	35-67	80-100
PATIENT		NM	0.65	1.2	0.73	50	
FELINE CARDIAC PARAMETERS	LA/AO (Boon)	LA/AO HEART BASE (Sisson)	LA 2D 4-chamber long axis AS to FW (Sisson) (cm)		LVOT VEL. (m/s)	RVOT VEL. (m/s)	IVRT (m)
NORMAL PARAMETER	<1.5	0.88-1.79	0.7-1.7		<1.6	<1.3	40-60
PATIENT	1.2	1.0	1.3		4.0	1.2	NM
Adapted from June Boon, Veterinary Echocardiography, 1998 Sisson D et al. JVIM 1991; 5: 232, Jacobs et al. Am J Vet Res 1985; 46:1705							

INVOICE

31857

DATE

7/20/22

ULTRASONOGRAPHIC FINDINGS

Hypertrophic cardiomyopathy phenotype, compensated at this time.



PATIENT

Stella Ross

SPECIES

Feline

BREED

Domestic Longhair

SEX

Spayed female

AGE

11 years

WEIGHT

10.5 lbs

INTERPRETED BY

Eric Lindquist, DMV
DABVP, Cert. IVUSS

IMAGING PERFORMED BY

Dr. Rodriguez

HOSPITAL NAME

Foxfield VS

REFERRING VET

Dr. Rodriguez

INVOICE

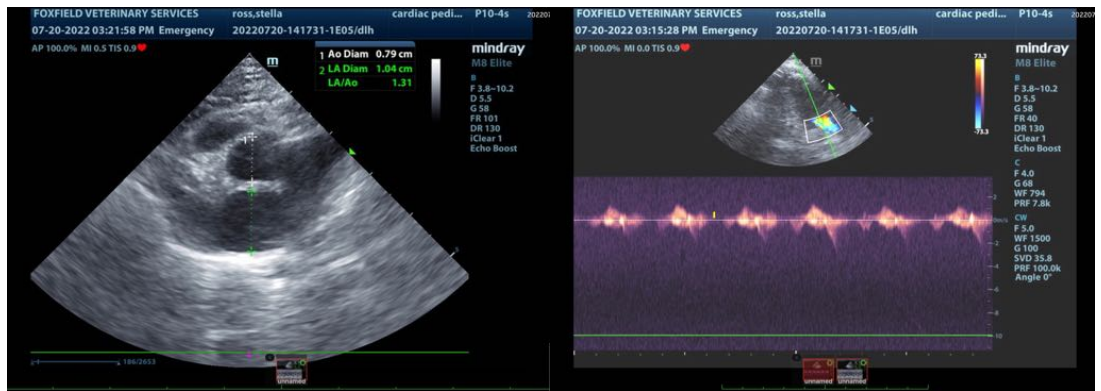
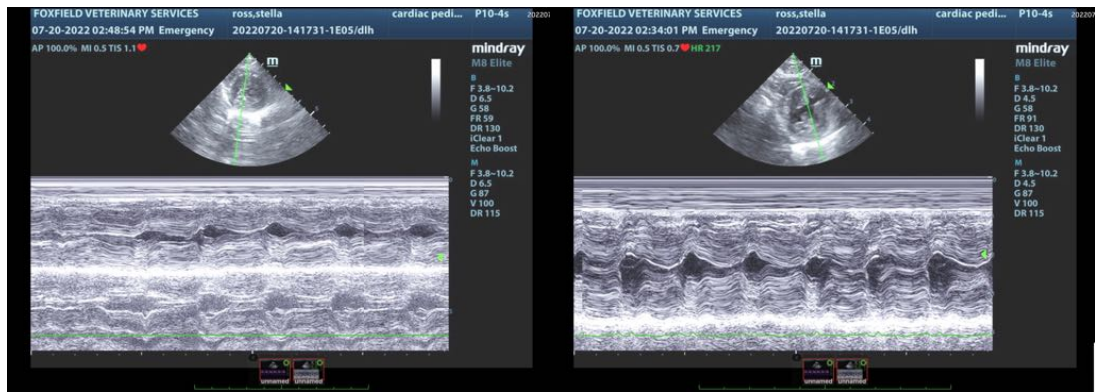
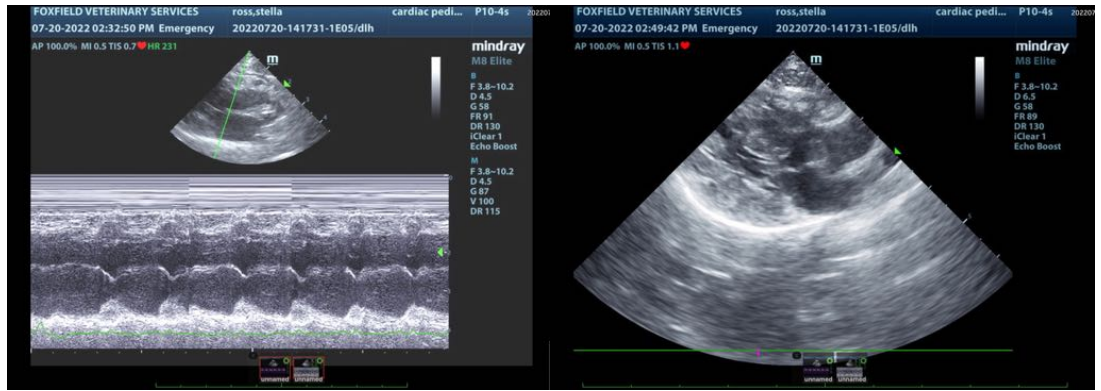
31857

DATE

7/20/22

INTERPRETATION OF THE FINDINGS & FURTHER RECOMMENDATIONS

Atenolol therapy can be considered in this patient at 6.25-12.5 mg s.i.d. to b.i.d. to reach a target heart rate less than 200; however, it is debatable on whether therapy is necessary at this time. I recommend therapy if any exercise intolerance is an issue.





PATIENT

Stella Ross

SPECIES

Feline

BREED

Domestic Longhair

SEX

Spayed female

AGE

11 years

WEIGHT

10.5 lbs

INTERPRETED BY

Eric Lindquist, DMV
DABVP, Cert. IVUSS

IMAGING PERFORMED BY

Dr. Rodriguez

HOSPITAL NAME

Foxfield VS

REFERRING VET

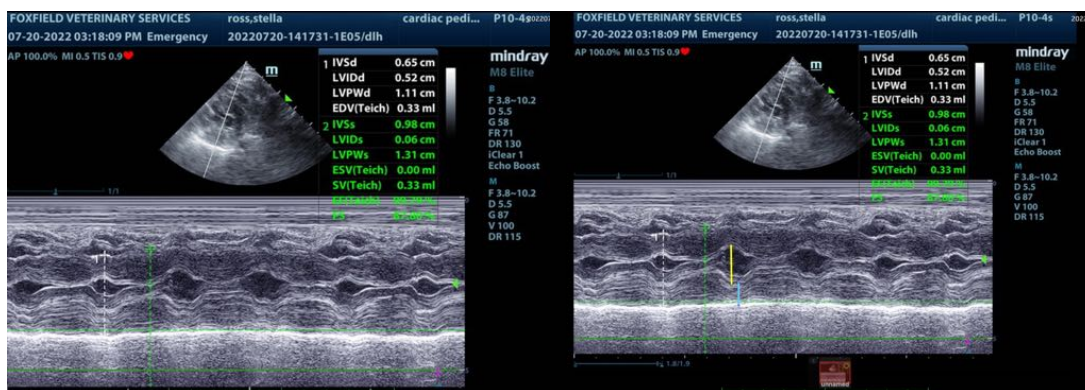
Dr. Rodriguez

INVOICE

31857

DATE

7/20/22



The information and recommendations provided are based on the images presented by the referring veterinarian/sonographer. No evaluation can be communicated regarding pathology that was not visible in the image/video clips provided.

Thank you for this referral. If the clinical or image interpretation does not parallel your findings or if I can be of any further assistance please contact me.

Eric Lindquist, DMV, DABVP, Cert. IVUSS, CEO of SonoPath.com
info@SonoPath.com