



**PATIENT**

Reya Smith

**SPECIES**

Canine

**BREED**

Mix

**SEX**

Spayed female

**AGE**

1 year

**WEIGHT**

45.6 lbs

**PRESENTING CLINICAL SIGNS**

**History:** Patient possibly ate part of a blanket in April, 3 days later she presented for bloating and early GDV, she was taken to surgery at that time. Since surgery she has had recurrent bouts of regurgitation and vomiting. She has lost weight since surgery as well.... Currently on Gas-x, metoclopramide, and cerenia.

**Abnormal PE/Chem/CBC/UA Results:** BW done 5/18/22 unremarkable. Radiographs: Diffuse gas throughout the small intestines, stomach gas distended with suspect foreign material within the lumen, otherwise unremarkable..

**ULTRASONOGRAPHIC EXAMINATION OF THE ABDOMEN**

**Urinary System**

The **urinary bladder**, trigone, and pelvic urethra presented normal thicknesses and normal tone. The ureters were not visible which is normal. No uroliths or sediment were visualized and anechoic urine was present. No evidence of inflammatory or neoplastic changes was noted. Ureteral papillae were normal.

The **kidneys** revealed normal size and structure, corticomedullary definition and ratio for this age. The cortices presented largely uniform texture with normal echogenic relationship to liver and spleen. Medullary structure differed distinctly from the cortex and no evidence of pelvic dilation was present. The capsules were acceptably uniform without significant irregularities. The right kidney measured 6.06 cm. The left kidney measured 5.86 cm.

**INTERPRETED BY**

Eric Lindquist, DMV  
DABVP, Cert. IVUSS

**IMAGING PERFORMED BY**

Jessica Green

**HOSPITAL NAME**

Stanglein VC

**REFERRING VET**

Dr. Rothrock

**INVOICE**

31839

**DATE**

7/20/22

**Adrenal Glands**

The left **adrenal gland** was visualized and recognized as having normal shape, size, position and echogenicity for this breed. The phrenic vasculature, glandular echogenicity and detail were unremarkable. Capsule, cortex, and medullary definition were normal for this age patient. The left adrenal gland measured 1.32 x 0.32 cm. The region of the right adrenal gland was imaged with no evidence of pathology.

**Spleen**

The **spleen** was folded upon itself cranially with slight, heterogenous parenchymal changes without disruption of architecture.

**Liver**

The **liver** images submitted revealed subjectively normal liver size, contour, and structure. Parenchymal echogenicity was naturally coarse and hypoechoic to the spleen. Vascular and biliary tracts were of normal volume with no evidence of congestion. The gallbladder presented acceptably thin walls with primarily anechoic content. The cystic and common bile ducts were normal. No pathological hepatic lymphadenopathy was evident. No overt structural evidence of inflammatory, infiltrative or regenerative pathology was evident.



**PATIENT**

**Gastrointestinal**

Reya Smith

Examination of the **gastrointestinal tract** revealed a stomach and intestine free of stasis, of normal wall thickness, acceptable curvilinear mural detail, and peristaltic activity. Small and large intestine demonstrated normal luminal chyme and stool consistency respectively. No obstructive or overt infiltrative disease was noted. No associated abnormal lymphatic activity was noted.

**SPECIES**

Canine

**BREED**

Mix

**Pancreas**

The base and limbs of the **pancreas** were observed to be largely isoechoic to surrounding omental fat. Pancreatic duct and capsular contour were acceptably normal and parenchyma respected normal curvilinear patterns. No overt evidence of active inflammatory or neoplastic disease was noted.

**SEX**

Spayed female

**ULTRASONOGRAPHIC FINDINGS**

Structurally unremarkable abdomen.

**AGE**

1 year

**INTERPRETATION OF THE FINDINGS & FURTHER RECOMMENDATIONS**

There is no evidence of obstructive disease. Supportive care should prove effective.

**WEIGHT**

45.6 lbs

**INTERPRETED BY**

Eric Lindquist, DMV  
DABVP, Cert. IVUS

**IMAGING PERFORMED BY**

Jessica Green

**HOSPITAL NAME**

Stanglein VC

**REFERRING VET**

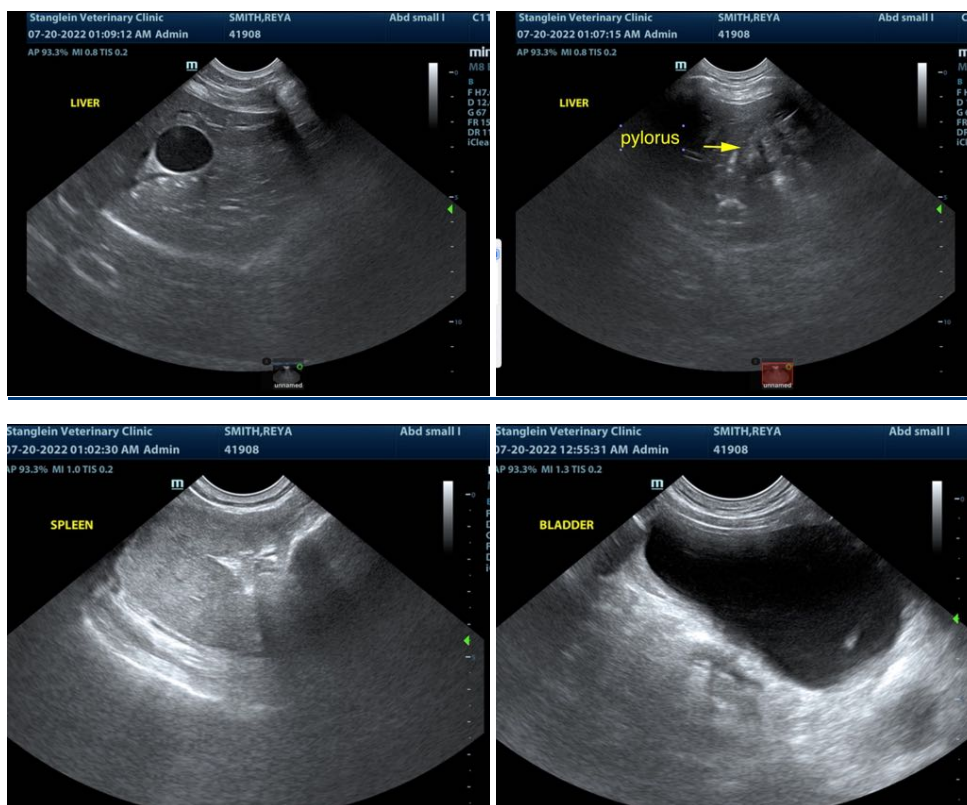
Dr. Rothrock

**INVOICE**

31839

**DATE**

7/20/22





**PATIENT**

Reya Smith

**SPECIES**

Canine

**BREED**

Mix

**SEX**

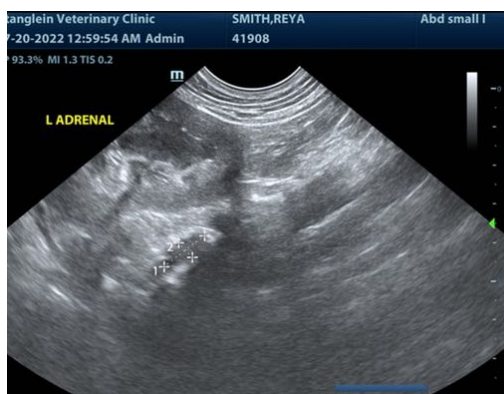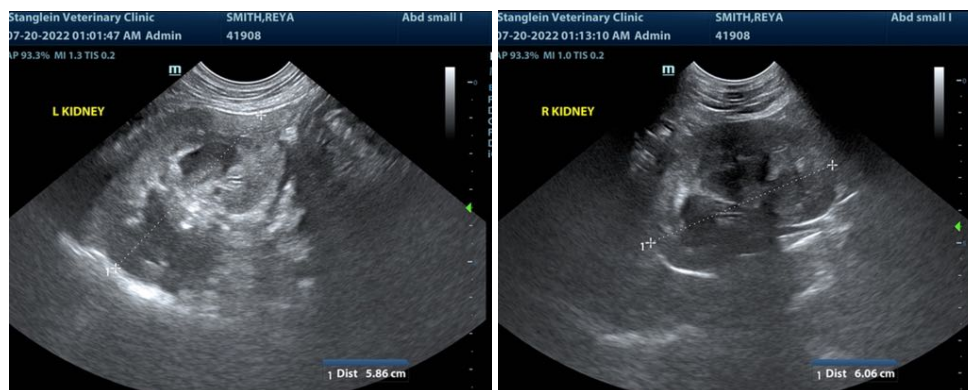
Spayed female

**AGE**

1 year

**WEIGHT**

45.6 lbs



**INTERPRETED BY**

Eric Lindquist, DMV  
DABVP, Cert. IVUSS

**IMAGING PERFORMED BY**

Jessica Green

**HOSPITAL NAME**

Stanglein VC

**REFERRING VET**

Dr. Rothrock

**INVOICE**

31839

**DATE**

7/20/22

The information and recommendations provided are based on the images presented by the referring veterinarian/sonographer. No evaluation can be communicated regarding pathology that was not visible in the image/video clips provided.

Thank you for this referral. If the clinical or image interpretation does not parallel your findings or if I can be of any further assistance please contact me.

**Eric Lindquist, DMV, DABVP, Cert. IVUSS, CEO of SonoPath.com**  
info@SonoPath.com