



**PATIENT**

Brody Baumaister

**SPECIES**

Canine

**BREED**

Yorkshire Terrier

**SEX**

Neutered Male

**AGE**

11 Years

**WEIGHT**

6.08 Pounds

**INTERPRETED BY**

Eric Lindquist, DMV  
DABVP, Cert. IVUSS

**IMAGING PERFORMED BY**

Dr. Carver

**HOSPITAL NAME**

Animal Emergency  
Hospital, Volusia

**REFERRING VET**

Dr. Carver

**INVOICE**

16472

**DATE**

7/2/22

**PRESENTING CLINICAL SIGNS**

History: Vomiting and diarrhea the last couple of days. P had an abnormal CPL and slightly elevated liver values

**ULTRASONOGRAPHIC EXAMINATION OF THE ABDOMEN**

**Urinary System**

The **urinary bladder**, trigone, and pelvic urethra presented normal thicknesses and normal tone. The ureters were not visible which is normal. No uroliths or sediment were visualized, and anechoic urine was present. No evidence of inflammatory or neoplastic changes were noted. Ureteral papillae were normal.

The **kidneys** revealed largely normal size and structure, corticomedullary definition and ratio (cortex 1/3 of medulla) were essentially maintained with some moderate age-related loss of curvilinear patterns regarding the capsule and C/M junction. The cortices presented largely uniform texture with some increased echogenicity expected for his age patient. Medullary structure differed distinctly from that of the cortex and no evidence of pelvic dilation was present. Both kidneys measured 5.0 cm each.

**Adrenal Glands**

Both **adrenal glands** were visualized and recognized as having normal shape, size, position and echogenicity for this breed. The phrenic vasculature, glandular echogenicity and detail were unremarkable. Capsule, cortex, and medullary definition were normal for this age patient. The left adrenal gland measured the upper limits of normal at 0.7 cm. The right adrenal gland measured 0.5 cm.

**Spleen**

The **spleen** presented a smooth homogeneous parenchyma hyperechoic to liver and renal cortical parenchyma. The capsule was smooth without noticeable expansion or deviation from within the spleen or adjacent pathology. The splenic vasculature demonstrated normal volume without signs of congestion or thrombosis. No sonographic evidence of acute or chronic inflammatory, neoplastic, or infarctual changes were noted.

**Liver**

The **liver** presented heterogenous parenchyma with increased portal markings and coarse architecture. Slight undulating capsular contour was noted. The gallbladder and common bile duct were unremarkable. This is a mild change, consistent with chronic inflammatory hepatopathy.

**Gastrointestinal**

The **pylorus** was thickened in this patient with hypertrophied muscularis and echogenic remodeling. Some aspects of hypertrophic pyloric gastropathy were noted. Gastric wall thickness measured up to 9.0 mm in the pyloric outflow. Echogenic submucosal layer was also noted. No evidence of foreign bodies and neoplastic criteria is not present.

**Pancreas**

The **pancreas** revealed hyperechoic remodeling consistent with past episodes of pancreatitis, yet no evidence of active inflammation was present.



## PATIENT

Brody Baumaister

## SPECIES

Canine

## BREED

Yorkshire Terrier

## SEX

Neutered Male

## AGE

11 Years

## WEIGHT

6.08 Pounds

## INTERPRETED BY

Eric Lindquist, DMV  
DABVP, Cert. IVUSS

## IMAGING PERFORMED BY

Dr. Carver

## HOSPITAL NAME

Animal Emergency  
Hospital, Volusia

## REFERRING VET

Dr. Carver

## INVOICE

16472

## DATE

7/2/22

## ULTRASONOGRAPHIC FINDINGS

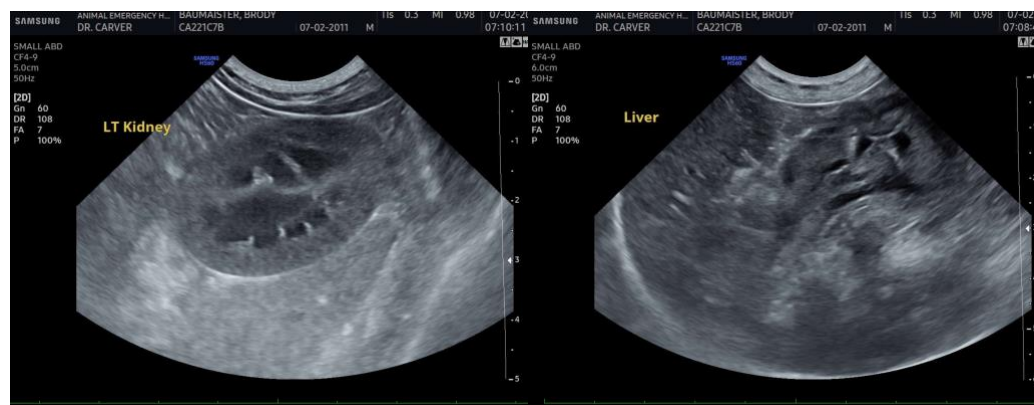
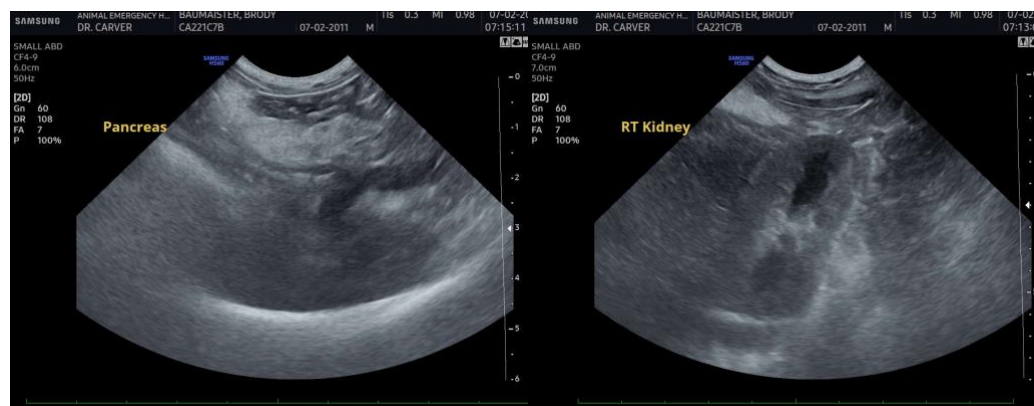
- Pyloric hypertrophy/chronic gastritis pattern
- Pancreatic remodeling
- Hepatic remodeling
- Age-related abdominal changes

## INTERPRETATION OF THE FINDINGS & FURTHER RECOMMENDATIONS

Criteria for hypertrophic pyloric gastropathy was incomplete yet functionally sustaining as such. A history of pancreatitis is likely. A history if inflammatory hepatopathy is likely given the hepatic remodeling. No evidence of neoplasia. Repeated upper GI, pancreatic and hepatic insult is likely playing a role in this patients history. A clinical trial of the following is recommended. 24-hour NPO recommended.

### Helicobacter/Gastritis protocol

A clinical trial of **Zithromax (Dogs: 5-10 mg/kg p.o. q24h. May increase dosing interval to q48h after 3-5 days of treatment)**, **Metronidazole (10-20 mg/kg p.o. b.i.d.)**, **Pepcid (0.5-1 mg/kg s.i.d.)** and **Sucralfate (0.5-2 g/dog PO)** or **Omeprazole (1 mg/kg p.o. s.i.d.)** over the next 3 weeks along with a canned BID feedings. A hydrolyzed diet may be in this patients best interest long term given the global presentation. Dry food should be avoided over the next 4 weeks. A recheck sonogram to assess GI improvement or progression would be ideal in 4 weeks.





**PATIENT**

Brody Baumaister

**SPECIES**

Canine

**BREED**

Yorkshire Terrier

**SEX**

Neutered Male

**AGE**

11 Years

**WEIGHT**

6.08 Pounds

**INTERPRETED BY**

Eric Lindquist, DMV  
DABVP, Cert. IVUSS

**IMAGING  
PERFORMED BY**

Dr. Carver

**HOSPITAL NAME**

Animal Emergency  
Hospital, Volusia

**REFERRING VET**

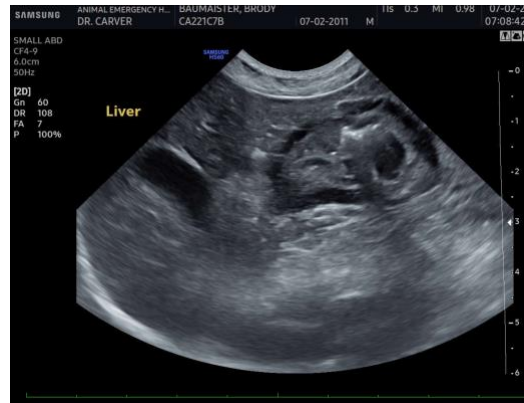Dr. Carver

**INVOICE**

16472

**DATE**

7/2/22



The information and recommendations provided are based on the images presented by the referring veterinarian. No evaluation can be communicated regarding pathology that was not visible in the image/video clips provided.

Thank you for this referral. If the clinical or image interpretation does not parallel your findings or if I can be of any further assistance please contact me.

**Eric Lindquist**, DMV, DABVP, Cert. IVUSS, CEO of SonoPath.com  
info@SonoPath.com