



PATIENT

Sonny Pietropaolo

SPECIES

Canine

BREED

Bichon/Shih Tzu Mix

SEX

Neutered Male

AGE

14 Years

WEIGHT

18.8 Pounds

INTERPRETED BY

Eric Lindquist, DMV
DABVP, Cert. IVUSS

**IMAGING
PERFORMED BY**

Meghan Myers, VMD

HOSPITAL NAME

Hershire AH

REFERRING VET

Dr. Alesha Glass

INVOICE

23468

DATE

7/19/23

PRESENTING CLINICAL SIGNS

Patient has a history calcium oxalate bladder stones and is on potassium citrate as well as Hill's c/d. 2 pounds of weight loss in 4 months. PE reveals severe otitis externa and grade 1/6 heart murmur (new finding since last visit), PMI mitral. At his recheck exam on 6/12/23 a rectal exam was performed Two small tumors were palpated within the left anal gland. His left popliteal LN palpates a bit more prominent than his right. Remainder of peripheral LN's are WNL. Recommend next steps being thoracic radiographs and abdominal US to scan for metastasis before referral for surgery.

Abnormal PE/Chem/CBC/UA Results: Bloodwork revealed ALT of 127 (18-121). ALP 274 (5-160). Ca 13.5 (8.4-11.8). TP 7.8 (5.5-7.5). chest rads pending however, 1 suspicious lesion

ULTRASONOGRAPHIC EXAMINATION OF THE ABDOMEN

Urinary System

The **urinary bladder** revealed normal wall structure, however, a 2.3 cm calculus, or grouping of calculi, was noted, nonobstructive. The pelvic urethra was imaged 3.0 cm beyond the cystourethral junction. The residual prostate measured 7.0 mm. Iliac trifurcation was unremarkable.

The **kidneys** revealed largely normal size and structure, corticomedullary definition and ratio (cortex 1/3 of medulla) were essentially maintained with some moderate age-related loss of curvilinear patterns regarding the capsule and C/M junction. Medullary structure differed distinctly from that of the cortex and no evidence of pelvic dilation was present. The left kidney measured 4.8 cm. Microcystic cortices were present. The right kidney measured 5.5 cm.

Adrenal Glands

The **left adrenal gland** was visualized and recognized as having normal shape, size, position and echogenicity for this breed. The phrenic vasculature, glandular echogenicity and detail were unremarkable. Capsule, cortex, and medullary definition were normal for this age patient. The left adrenal gland measured 0.45 cm.

The cranial pole of the **right adrenal gland** was mildly swollen, to monitor. The right adrenal gland measured 1.2 cm at the cranial pole and 0.55 cm at the caudal pole. Adenomatous or hyperplastic change is likely.

Spleen

The **spleen** presented a smooth homogeneous parenchyma hyperechoic to liver and renal cortical parenchyma. The capsule was smooth without noticeable expansion or deviation from within the spleen or adjacent pathology. The splenic vasculature demonstrated normal volume without signs of congestion or thrombosis. No sonographic evidence of acute or chronic inflammatory, neoplastic, or infarctual changes were noted.

Liver

Generalized **hepatic** enlargement was present. The liver presented coarse architecture with mildly increased portal markings and subtle, mixed echogenic changes. This is a moderate change, consistent with vacuolar hepatopathy, some level of remodeling and history of inflammatory component. Occasional non-disrupted nodular changes were noted in the liver. The gallbladder was mildly over distended with suspended and dependent debris, yet not to the level of emerging mucocele, yet sludge appears to be mildly excessive. No adjunctive inflammation was noted.



PATIENT

Sonny Pietropaolo

SPECIES

Canine

BREED

Bichon/Shih Tzu Mix

SEX

Neutered Male

AGE

14 Years

WEIGHT

18.8 Pounds

INTERPRETED BY

Eric Lindquist, DMV
DABVP, Cert. IVUSS

**IMAGING
PERFORMED BY**

Meghan Myers, VMD

HOSPITAL NAME

Hershire AH

REFERRING VET

Dr. Alesha Glass

INVOICE

23468

DATE

7/19/23

Gastrointestinal

There was some residual chyme and gas was noted in the **stomach**, yet not pathological. This is consistent with end post prandial presentation. Transit of chyme into the small intestine was normal. Curvilinear patterns were maintained throughout the GI tract. No evidence of pathology. Small and large intestine demonstrated normal luminal chyme and stool consistency respectively. No obstructive or overt infiltrative disease was noted. No associated abnormal lymphatic activity was noted.

Pancreas

The base and limbs of the **pancreas** were observed to be largely isoechoic to surrounding omental fat. Some mild parenchymal remodeling, however, with mild deviation from curvilinear normalcy was observed. Pancreatic duct and capsular irregularities were present consistent with age related changes. If pain upon imaging (+ Murphy sign) was present or if the patient is focally painful in subxyphoid palpation then low-grade smoldering chronic pancreatitis should be suspected.

ULTRASONOGRAPHIC FINDINGS

- Prominent cranial pole of the right adrenal gland
- Urinary bladder calculi
- Vacuolar hepatopathy liver pattern with remodeling and nodular changes, subjectively benign.
- Age-related abdominal changes otherwise

INTERPRETATION OF THE FINDINGS & FURTHER RECOMMENDATIONS

FNA of the liver could be considered for further definition. No contraindication to anesthetic procedure. The cause of hypercalcemia is not evident in the abdomen, Anal gland imaging and palpation, spinal and chest radiographs, and parathyroid imaging are indicated, based on Michigan State hypercalcemia panel.



PATIENT

Sonny Pietropaolo

SPECIES

Canine

BREED

Bichon/Shih Tzu Mix

SEX

Neutered Male

AGE

14 Years

WEIGHT

18.8 Pounds

INTERPRETED BY

Eric Lindquist, DMV
DABVP, Cert. IVUSS

IMAGING PERFORMED BY

Meghan Myers, VMD

HOSPITAL NAME

Hershire AH

REFERRING VET

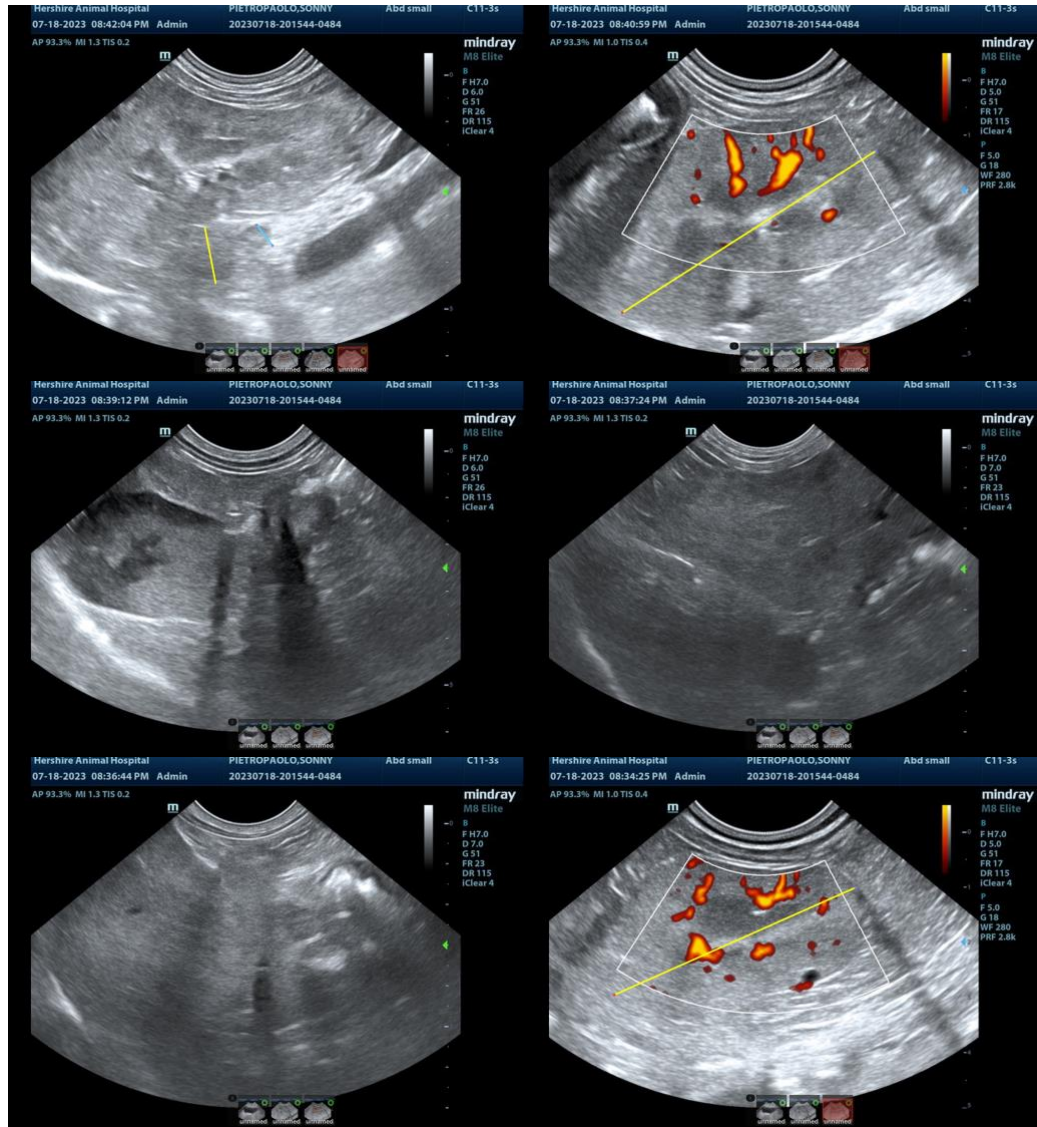
Dr. Alesha Glass

INVOICE

23468

DATE

7/19/23





PATIENT

Sonny Pietropaolo

SPECIES

Canine

BREED

Bichon/Shih Tzu Mix

SEX

Neutered Male

AGE

14 Years

WEIGHT

18.8 Pounds

INTERPRETED BY

Eric Lindquist, DMV
DABVP, Cert. IVUSS

IMAGING PERFORMED BY

Meghan Myers, VMD

HOSPITAL NAME

Hershire AH

REFERRING VET

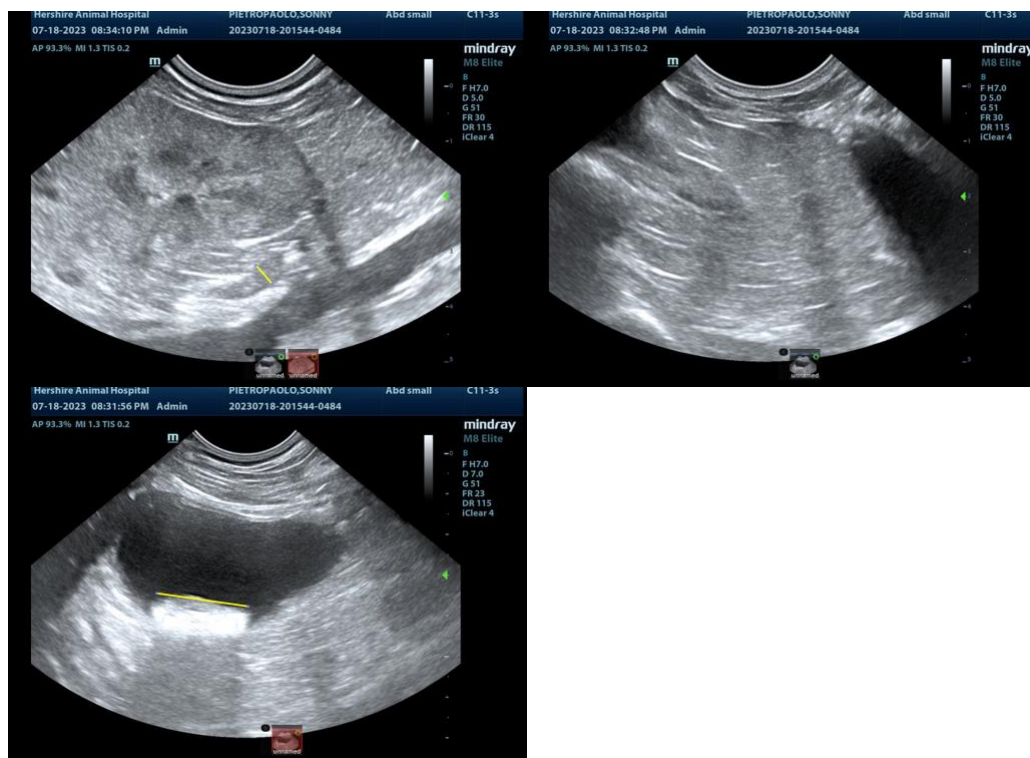
Dr. Alesha Glass

INVOICE

23468

DATE

7/19/23



The information and recommendations provided are based on the images presented by the referring veterinarian. No evaluation can be communicated regarding pathology that was not visible in the image/video clips provided.

Thank you for this referral. If the clinical or image interpretation does not parallel your findings or if I can be of any further assistance please contact me.

Eric Lindquist, DMV, DABVP, Cert. IVUSS, CEO of SonoPath.com
info@SonoPath.com

CANINE HYPERCALCEMIA

<http://www.sonopath.com/CanineHypercalcemia>

Description: Hypercalcemia is defined as either a persistently elevated total calcium serum (> 12 mg/dl) or ionized calcium (> 1.45 mmol/l) concentration. Clinical signs are often absent with mild hypercalcemia (< 13 mg/dl). In fact, hypercalcemia is often only discovered when serum biochemistry is done for unrelated reasons. Clinical signs are usually mild when the serum calcium concentration is less than 14 mg/dl; however, signs become more readily apparent when the concentration exceeds 15 mg/dl. Life-threatening cardiac arrhythmias can develop when the serum calcium exceeds 18 mg/dl.



PATIENT

Sonny Pietropaolo

Common etiologies of hypercalcemia include humoral hypercalcemia of malignancy (HHM), hypoadrenocorticism, chronic kidney disease (CKD), hypervitaminosis D, and primary hyperparathyroidism. Less common etiologies include bone neoplasia, osteomyelitis, hypertrophic osteodystrophy, granulomatous disease, calcium supplementation, and oral phosphate binders.

SPECIES

Canine

Clinical Signs: Common clinical signs include polyuria, polydipsia, lethargy, inappetence, and weakness. With chronic hypercalcemia, calcium oxalate and calcium phosphate uroliths can form, resulting in clinical signs suggestive of lower urinary tract disease. Systemic signs of illness are suggestive of HHM.

BREED

Bichon/Shih Tzu Mix

SEX

Neutered Male

Diagnostics: One important etiology of hypercalcemia is laboratory error; therefore, hypercalcemia should always be confirmed before embarking on any further diagnostic evaluation. Results of a CBC, serum biochemistry panel, and urinalysis, in conjunction with a patient history and findings from a physical examination, can often provide enough information to arrive at a diagnosis. The appendicular skeleton, peripheral lymph nodes, abdominal cavity, and rectum should all be carefully palpated for masses, lymphadenopathy, hepatomegaly, splenomegaly, and/or pain in the long bones. The following diagnostic tests are helpful for identifying an underlying malignancy: thoracic and abdominal radiographs; abdominal ultrasound; cytological evaluation of aspirates of the liver, spleen, lymph nodes, and bone marrow; determination of serum ionized calcium, parathyroid hormone (PTH), and parathyroid hormone-related protein concentration (PTHrP); and ultrasound of the neck. Ascertaining the concentrations of serum ionized calcium, PTH, and PTHrP helps differentiate primary hyperparathyroidism from HHM. The finding of one or more enlarged parathyroid glands upon conducting an ultrasound of the neck supports a diagnosis of primary hyperparathyroidism.

AGE

14 Years

WEIGHT

18.8 Pounds

INTERPRETED BY

Eric Lindquist, DMV
DABVP, Cert. IVUSS

Hypoadrenocorticism-induced hypercalcemia usually occurs in conjunction with hyponatremia, hyperkalemia, and prerenal azotemia. With HHM and primary hyperparathyroidism, serum phosphorus concentration is often in the low to low-normal reference range. If the serum phosphorus concentration is high but kidney function is normal, hypervitaminosis D or osteolysis should be suspected.

IMAGING PERFORMED BY

Meghan Myers, VMD

HOSPITAL NAME

Hershire AH

It can be difficult to determine whether kidney failure is primary or secondary to hypercalcemia when hyperphosphatemia and hypercalcemia coexist with azotemia. Serum ionized calcium concentrations are typically normal or decreased in cases of renal failure and increased in cases of hypercalcemia caused by other disorders.

REFERRING VET

Dr. Alesha Glass

Sternal and hilar lymphadenopathy is common with lymphoma-induced hypercalcemia and can be readily identified on thoracic radiographs. In cases of multiple myeloma, discrete lytic lesions in the vertebrae or long bones, hyperproteinemia, proteinuria, and plasma cell infiltration in the bone marrow may be present. Cytological evaluation of the peripheral lymph nodes, bone marrow, and spleen can be helpful in identifying lymphoma.

INVOICE

23468

DATE

7/19/23



PATIENT

Sonny Pietropaolo

Increased serum ionized calcium concentrations, detectable serum PTHrP concentrations, and non-detectable serum PTH concentrations are all diagnostic for HHM. Lymphoma is the most common etiology of HHM, but other tumors, such as apocrine gland adenocarcinoma and various carcinomas (e.g. mammary gland, squamous cell, bronchogenic), can all give rise to hypercalcemia. Increased serum ionized calcium, normal to increased serum PTH, and non-detectable PTHrP concentrations are diagnostic of primary hyperparathyroidism.

SPECIES

Canine

BREED

Bichon/Shih Tzu Mix

Differentials for Hypercalcemia: "HARD IONS"

SEX

Neutered Male

Hyperparathyroid

Addison's

Renal

AGE

14 Years

D-toxicity

Idiopathic

WEIGHT

18.8 Pounds

Osteolytic

Neoplastic

Spurious

INTERPRETED BY

Eric Lindquist, DMV
DABVP, Cert. IVUSS

PTH tumor: Elevated total and ionized Ca, low PTHrP, and normal/high PTH. Keeshonds, German Shepherds, and Golden Retrievers are all predisposed.

IMAGING PERFORMED BY

Meghan Myers, VMD

Addison's disease: Elevated total and normal ionized Ca, elevated BUN, hypoalbuminemia and hyperkalemia.

Renal failure: Elevated to normal total Ca, low ionized Ca, low PTHrP, elevated PTH, azotemia, and low urine specific gravity.

HOSPITAL NAME

Hershire AH

Vitamin D toxicity: Elevated total and ionized Ca, low PTHrP, and normal/low PTH.

Hypercalcemia of malignancy (HHM): Elevated total and ionized Ca, high PTHrP, and low PTH.

REFERRING VET

Dr. Alesha Glass

Granulomatous disease: Elevated total and ionized Ca, low PTHrP, and low PTH.

Renal failure: Elevated to normal total Ca, low ionized Ca, low PTHrP, elevated PTH, azotemia, and low urine specific gravity.

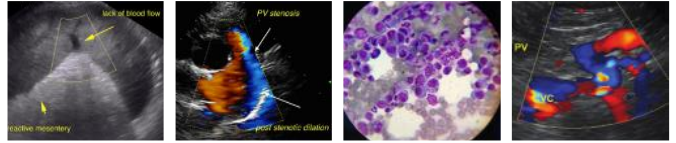
INVOICE

23468

Treatment: Therapies for hypercalcemia are aimed at correcting the underlying etiology; however, because prolonged hypercalcemia can result in kidney damage, the use of fluid therapy, furosemide, and possibly prednisone is indicated in all cases to reduce serum calcium levels. Suggested dosages include saline (0.9% 120-180 ml/kg day IV), furosemide (1-4 mg/kg PO TID), and prednisone (0.25 mg/kg PO Q24hr).

DATE

7/19/23



PATIENT

Sonny Pietropaolo

References:

SPECIES

Canine

Chew DJ, Schenck PA, Jaeger JQ. Clinical disorders of hypercalcemia and hypocalcemia in dogs and cats. Proceedings from the American College of Veterinary Internal Medicine, Charlotte, NC, June 4-7, 2003.

BREED

Bichon/Shih Tzu Mix

Feldman EC. Disorders of the parathyroid glands. In: Ettinger SJ, Feldman EC, ed. *Textbook of Veterinary Internal Medicine, 7th ed.* St. Louis, MO: Saunders Elsevier; 2010:1722-50.

SEX

Neutered Male

Peterson ME. Hypercalcemia in dogs & cats: differential diagnosis & treatment. Proceedings from the Western Veterinary Conference, Las Vegas, NV, February 19-23, 2012.

AGE

14 Years

WEIGHT

18.8 Pounds

INTERPRETED BY

Eric Lindquist, DMV
DABVP, Cert. IVUSS

**IMAGING
PERFORMED BY**

Meghan Myers, VMD

HOSPITAL NAME

Hershire AH

REFERRING VET

Dr. Alesha Glass

INVOICE

23468

DATE

7/19/23