



PATIENT

Pearl Trimmer

SPECIES

Canine

BREED

Bulldog Mix

SEX

Spayed Female

AGE

7 Years 2 Months

WEIGHT

48 Pounds

INTERPRETED BY

Eric Lindquist, DMV
DABVP, Cert. IVUSS

IMAGING PERFORMED BY

Kaitlyn McDaniel

HOSPITAL NAME

Elizabeth AH

REFERRING VET

Leon Anderson, DVM

INVOICE

23503

DATE

7/19/23

PRESENTING CLINICAL SIGNS

History: Dental exam generated labs for pre-anesthesia. Liver enzyme elevations (AST, ALT) noted. BA's were normal. No issues at home or long term conditions.

Abnormal PE/Chem/CBC/UA Results: PE: Stage III Dental disease. Nasal hyperkeratosis. Stifle OA. UA, CBC, cPL, Total T4, Free T4, Blood parasite screen, and Fecal all good. Chem: ALT 458 U/L, AST 208 U/L proBNP: 1302 pmol/L FNA of liver pending cytology.

ULTRASONOGRAPHIC EXAMINATION OF THE ABDOMEN

Urinary System

The **urinary bladder**, trigone, and pelvic urethra presented normal thicknesses and normal tone. The ureters were not visible which is normal. No uroliths or sediment were visualized and anechoic urine was present. No evidence of inflammatory or neoplastic changes were noted. Ureteral papillae were normal. The pelvic urethra was imaged 1.0 cm beyond the cystourethral junction.

The **kidneys** revealed normal size and structure, corticomedullary definition and ratio for this age. The cortices presented largely uniform texture with normal echogenic relationship to liver and spleen. Medullary structure differed distinctly from the cortex and no evidence of pelvic dilation was present. The capsules were acceptably uniform without significant irregularities. The right kidney measured 5.44 cm. The left kidney measured 5.24 cm.

Adrenal Glands

Both **adrenal glands** were visualized and recognized as having normal shape, size, position and echogenicity for this breed. The phrenic vasculature, glandular echogenicity and detail were unremarkable. Capsule, cortex, and medullary definition were normal for this age patient. The left adrenal gland measured 2.63 cm x 0.77 cm at the cranial pole and 0.72 cm at the caudal pole. The right adrenal gland measured 2.0 cm x 0.95 cm.

Spleen

The **spleen** presented a smooth homogeneous parenchyma hyperechoic to liver and renal cortical parenchyma. The capsule was smooth without noticeable expansion or deviation from within the spleen or adjacent pathology. The splenic vasculature demonstrated normal volume without signs of congestion or thrombosis. No sonographic evidence of acute or chronic inflammatory, neoplastic, or infarctual changes were noted.

Liver

The **liver** images submitted revealed subjectively normal liver size, contour, and structure. Parenchymal echogenicity was naturally coarse and hypoechoic to the spleen. Vascular and biliary tracts were of normal volume with no evidence of congestion. The gallbladder presented acceptably thin walls with primarily anechoic content. The cystic and common bile ducts were normal. No pathological hepatic lymphadenopathy was evident. No overt structural evidence of inflammatory, infiltrative or regenerative pathology was evident.

Gastrointestinal

Examination of the **gastrointestinal tract** revealed a stomach and intestine free of stasis, of normal wall thickness, acceptable curvilinear mural detail, and peristaltic activity. Small and large intestine



PATIENT

Pearl Trimmer

demonstrated normal luminal chyme and stool consistency respectively. No obstructive or overt infiltrative disease was noted. No associated abnormal lymphatic activity was noted.

Pancreas

SPECIES

Canine

The base and limbs of the **pancreas** were observed to be largely isoechoic to surrounding omental fat. Pancreatic duct and capsular contour were acceptably normal and parenchyma respected normal curvilinear patterns. No overt evidence of active inflammatory or neoplastic disease was noted.

BREED

Bulldog Mix

ULTRASONOGRAPHIC FINDINGS

- Structurally normal liver, likely reactive hepatopathy or nonspecific inflammatory hepatopathy

SEX

Spayed Female

No evidence of structural disease. No overt contraindication to anesthetic procedure, especially given that bile acids were normal.

AGE

7 Years 2 Months

The hepatic clinical sonographic presentation is most consistent with Reactive Hepatopathy which is the most common cause of liver enzyme elevation in dogs and cats. The presumption is that gut and other organ antigen stimuli may be causing a low-grade immune response through portal system with which the liver is reacting to causing low-grade enzyme elevations. US-guided FNA could be performed to assess if low grade lymphoplasmacytic inflammation is present that would support this theory. If FNA is performed, please ask the cytologist to emphasize the primary inflammatory cell type. Empirical treatment measures to address this issue can include diet change to hydrolyzed diet, probiotics, deworming, nutraceuticals (SAME, Actigall...), dental exam and cleaning, and potentially antibiotics such as Clavamox. Metronidazole and Tylosin have traditionally been utilized for this purpose but new studies show that both these antibiotics can disrupt the normal intestinal bacterial flora (intestinal dysbiosis) for weeks and up to 4-6 months. Therefore, Metronidazole and Tylosin should be utilized as a last resort if other efforts have not been effective and sonographic organ appearance remains benign.

WEIGHT

48 Pounds

INTERPRETED BY

Eric Lindquist, DMV
DABVP, Cert. IVUSS

IMAGING PERFORMED BY

Kaitlyn McDaniel

HOSPITAL NAME

Elizabeth AH

REFERRING VET

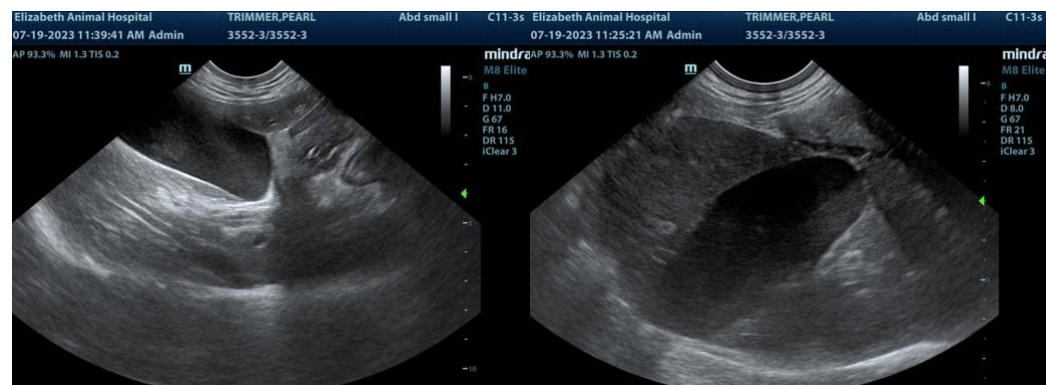
Leon Anderson, DVM

INVOICE

23503

DATE

7/19/23





PATIENT

Pearl Trimmer

SPECIES

Canine

BREED

Bulldog Mix

SEX

Spayed Female

AGE

7 Years 2 Months

WEIGHT

48 Pounds

INTERPRETED BY

Eric Lindquist, DMV
DABVP, Cert. IVUSS

IMAGING PERFORMED BY

Kaitlyn McDaniel

HOSPITAL NAME

Elizabeth AH

REFERRING VET

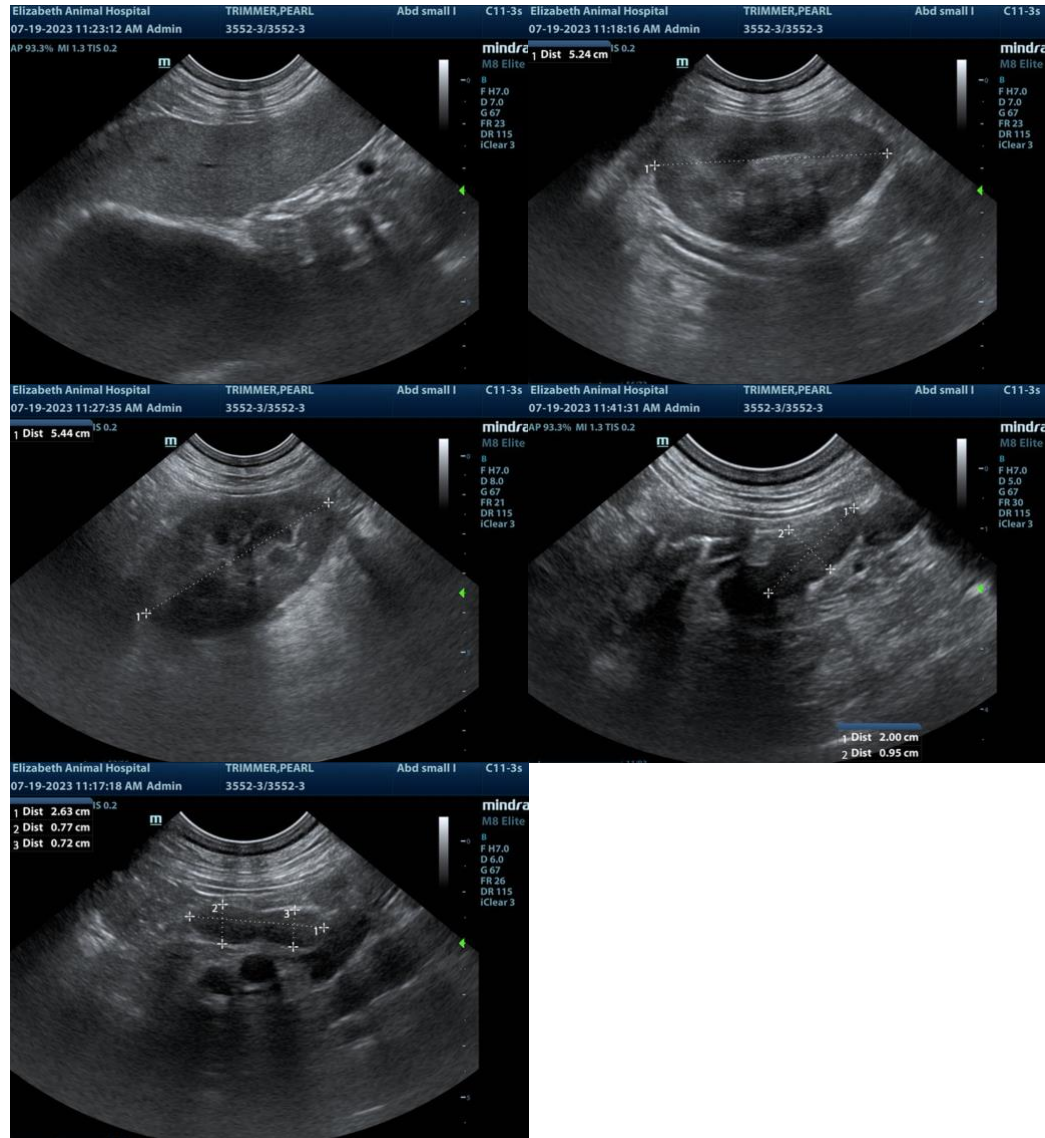
Leon Anderson, DVM

INVOICE

23503

DATE

7/19/23



The information and recommendations provided are based on the images presented by the referring veterinarian. No evaluation can be communicated regarding pathology that was not visible in the image/video clips provided.

Thank you for this referral. If the clinical or image interpretation does not parallel your findings or if I can be of any further assistance please contact me.

Eric Lindquist, DMV, DABVP, Cert. IVUSS, CEO of SonoPath.com
info@SonoPath.com