



**PATIENT PRESENTING CLINICAL SIGNS**

Omar Burttt Vomiting prolapsed anus decreased appetite.

**SPECIES ULTRASONOGRAPHIC EXAMINATION OF THE ABDOMEN**

**Canine Urinary System**

**BREED**

Frenchie

**SEX**

Neutered Male

**AGE**

4

**WEIGHT**

27

The **urinary bladder** presented a relatively uniform thickening of the cranioventral and craniodorsal mucosae with micropolypoid mucosal changes without involvement of the submucosae. The urine presented some echogenicity consistent with suspended debris. No evidence of urethral pathology was present. This presentation is most consistent with chronic cystitis. Technically transitional cell carcinoma cannot be ruled out without histopathological review but is not overtly suspected based on this pattern. Cystocentesis and urine culture +/- pathological review of urine cytology would be warranted. No overt calculi were present at this time. The pelvic urethra was imaged 2.0 cm beyond the cystourethral junction.

The **kidneys** revealed normal size and structure, corticomedullary definition and ratio for this age. The cortices presented largely uniform texture with normal echogenic relationship to liver and spleen. Medullary structure differed distinctly from the cortex and no evidence of pelvic dilation was present. The capsules were acceptably uniform without significant irregularities. The right kidney measured 4.62 cm. The left kidney measured 4.52 cm.

**Adrenal Glands**

Both **adrenal glands** were visualized and recognized as having normal shape, size, position and echogenicity for this breed. The phrenic vasculature, glandular echogenicity and detail were unremarkable. Capsule, cortex, and medullary definition were normal for this age patient. The right adrenal gland measured 1.63 cm x 0.50 cm at the caudal pole and 0.88 cm at the cranial pole. The left adrenal gland measured 1.65 cm x 0.56 cm at the caudal pole and 0.58 cm at the cranial pole.

**INTERPRETED BY**

Eric Lindquist, DMV

DABVP, Cert. IVUSS

**Spleen**

The **spleen** presented a smooth homogeneous parenchyma hyperechoic to liver and renal cortical parenchyma. The capsule was smooth without noticeable expansion or deviation from within the spleen or adjacent pathology. The splenic vasculature demonstrated normal volume without signs of congestion or thrombosis. No sonographic evidence of acute or chronic inflammatory, neoplastic, or infarctual changes were noted.

**IMAGING PERFORMED BY**

Jenn

**HOSPITAL NAME**

Rockaway AH

**Liver**

The **liver** images submitted revealed subjectively normal liver size, contour, and structure. Parenchymal echogenicity was naturally coarse and hypoechoic to the spleen. Vascular and biliary tracts were of normal volume with no evidence of congestion. The gallbladder presented acceptably thin walls with primarily anechoic content. The cystic and common bile ducts were normal. No pathological hepatic lymphadenopathy was evident. No overt structural evidence of inflammatory, infiltrative or regenerative pathology was evident.

**REFERRING VET**

Dr. Maniar

**INVOICE**

44118

**DATE**

7/19/23

**Gastrointestinal**

Examination of the **gastrointestinal tract** revealed a stomach and intestine free of stasis, of normal wall thickness, acceptable curvilinear mural detail, and peristaltic activity. Small and large intestine



**PATIENT**

Omar Burt

demonstrated normal luminal chyme and stool consistency respectively. No obstructive or overt infiltrative disease was noted. No associated abnormal lymphatic activity was noted.

**SPECIES**

Canine

**Pancreas**

The base and limbs of the **pancreas** were observed to be largely isoechoic to surrounding omental fat. Pancreatic duct and capsular contour were acceptably normal and parenchyma respected normal curvilinear patterns. No overt evidence of active inflammatory or neoplastic disease was noted.

**BREED**

Frenchie

**ULTRASONOGRAPHIC FINDINGS**

- Chronic cystitis bladder pattern, unremarkable abdomen otherwise

**SEX**

Neutered Male

**INTERPRETATION OF THE FINDINGS & FURTHER RECOMMENDATIONS**

No evidence of significant disease.

**AGE**

4

**WEIGHT**

27

**INTERPRETED BY**

Eric Lindquist, DMV

DABVP, Cert. IVUSS

**IMAGING PERFORMED BY**

Jenn

**HOSPITAL NAME**

Rockaway AH

**REFERRING VET**

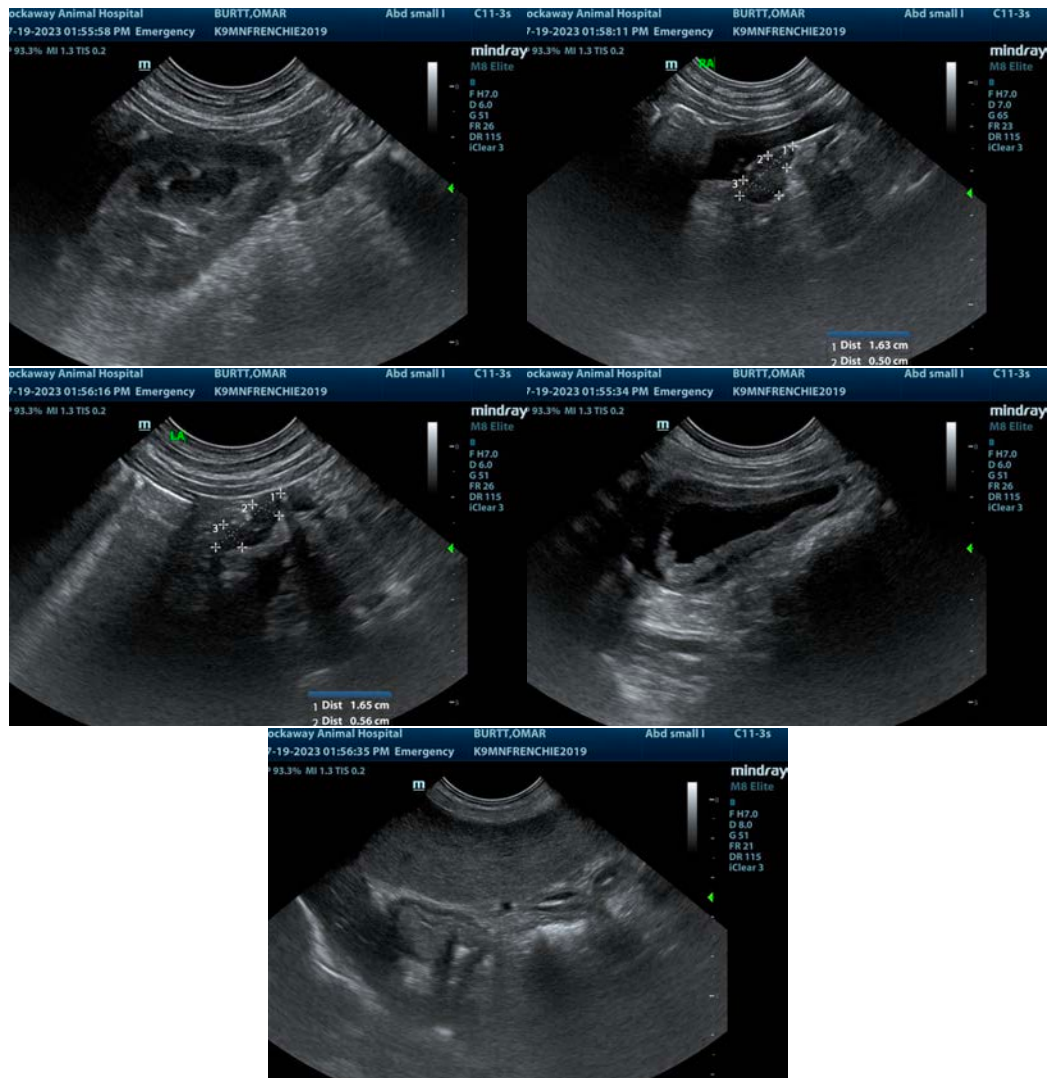
Dr. Maniar

**INVOICE**

44118

**DATE**

7/19/23





**PATIENT**

Omar Burt

The information and recommendations provided are based on the images presented by the referring veterinarian/sonographer. No evaluation can be communicated regarding pathology that was not visible in the image/video clips provided.

**SPECIES**

Canine

Thank you for this referral. If the clinical or image interpretation does not parallel your findings or if I can be of any further assistance please contact me.

**BREED**

Frenchie

**Eric Lindquist**, DMV, DABVP, Cert. IVUSS, CEO of SonoPath.com

[info@SonoPath.com](mailto:info@SonoPath.com)

**SEX**

Neutered Male

**AGE**

4

**WEIGHT**

27

**INTERPRETED BY**

Eric Lindquist, DMV

DABVP, Cert. IVUSS

**IMAGING PERFORMED BY**

Jenn

**HOSPITAL NAME**

Rockaway AH

**REFERRING VET**

Dr. Maniar

**INVOICE**

44118

**DATE**

7/19/23