



PATIENT

Elmi Llanes

SPECIES

Canine

BREED

French Bulldog

SEX

Spayed Female

AGE

7 Years

WEIGHT

22.2 Pounds

INTERPRETED BY

Eric Lindquist, DMV
DABVP, Cert. IVUSS

IMAGING PERFORMED BY

Guhrun Gunther

HOSPITAL NAME

New Frontier AMC

REFERRING VET

Guhrun Gunther

INVOICE

23489

DATE

7/19/23

PRESENTING CLINICAL SIGNS

Weight loss and generalized muscle attrition, very poor haircoat with alopecia on ears; abdominal distention in cranial abdomen Hx of atopy - treated with Apoquel, Cytopoint, Omega capsules Diet - Royal Canin HP Other meds: Fluoxetine for anxiety Amoxicillin/Clavulonate 125mg 1 PO BID - started last week for an elevated ALT Has NOT been on Prednisone since May 2022 (excessively PU/PD even on low doses) Most significant muscle atrophy on hind limbs - concerned about degenerative myelopathy Concerned about IBD, Cushing's

Abnormal PE/Chem/CBC/UA Results: BW and Urine = 7/6/23 UA - 1.029 USG otherwise unremarkable CBC - mild lymphopenia, eosinopenia CHEM - ALT 347 ALP 54 Albumin 2.7 (low end of normal range) Thyroid panel - euthyroid sick ACTH pending Significant bradycardia resolved after Atropine = Vagally Mediated Bradyarrhythmia

ULTRASONOGRAPHIC EXAMINATION OF THE ABDOMEN

Urinary System

The **urinary bladder**, trigone, and pelvic urethra presented normal thicknesses and normal tone. The ureters were not visible which is normal. No uroliths or sediment were visualized and anechoic urine was present. No evidence of inflammatory or neoplastic changes were noted. Ureteral papillae were normal. The pelvic urethra was imaged 2.0 cm beyond the cystourethral junction.

The **kidneys** revealed largely normal size and structure, corticomedullary definition and ratio (cortex 1/3 of medulla) were essentially maintained with some minor age-related loss of curvilinear patterns regarding the capsule and C/M junction. The cortices presented largely uniform texture with some increased echogenicity expected for his age patient. Medullary structure differed distinctly from that of the cortex and no evidence of pelvic dilation was present. The right kidney measured 4.83 cm. The left kidney measured 5.48 cm. The right kidney measured 5.0 cm.

Adrenal Glands

Both **adrenal glands** were heterogenous, mildly enlarged and slightly irregular yet encapsulated. The left adrenal gland was uniform, mildly enlarged, measuring 0.82 cm. The right adrenal gland was irregular, measuring 1.09 cm.

Spleen

The **spleen** presented a smooth homogeneous parenchyma hyperechoic to liver and renal cortical parenchyma. The capsule was smooth without noticeable expansion or deviation from within the spleen or adjacent pathology. The splenic vasculature demonstrated normal volume without signs of congestion or thrombosis. No sonographic evidence of acute or chronic inflammatory, neoplastic, or infarctual changes were noted. Caudal folding of the spleen was noted.

Liver

The **liver** images submitted revealed subjectively normal liver size, contour, and structure. Parenchymal echogenicity was naturally coarse and hypoechoic to the spleen. Vascular and biliary tracts were of normal volume with no evidence of congestion. The gallbladder presented acceptably thin walls with primarily anechoic content. The cystic and common bile ducts were normal. No pathological hepatic lymphadenopathy was evident. No overt structural evidence of inflammatory, infiltrative or regenerative pathology was evident.



PATIENT

Elmi Llanes

SPECIES

Canine

BREED

French Bulldog

SEX

Spayed Female

AGE

7 Years

WEIGHT

22.2 Pounds

INTERPRETED BY

Eric Lindquist, DMV
DABVP, Cert. IVUSS

IMAGING PERFORMED BY

Guhrun Gunther

HOSPITAL NAME

New Frontier AMC

REFERRING VET

Guhrun Gunther

INVOICE

23489

DATE

7/19/23

Gastrointestinal

The **stomach** was overdistended with chyme. A shadowing structure was noted in the stomach yet likely kibble or medications, measuring up to 1.4 cm in length. Mucosal remodeling was noted. Transit of chyme into the small intestine appeared present. The small intestine and colon were unremarkable.

Pancreas

The base and limbs of the **pancreas** were observed to be largely isoechoic to surrounding omental fat. Pancreatic duct and capsular contour were acceptably normal and parenchyma respected normal curvilinear patterns. No overt evidence of active inflammatory or neoplastic disease was noted.

Other

The **uterine stump** was prominent yet uniform, measuring 6.0 mm.

ULTRASONOGRAPHIC FINDINGS

- Mild bilateral adrenal hypertrophy
- Chronic gastritis pattern with shadowing structure, likely kibble or medication
- Prominent uterine stump
- Age-related renal changes

INTERPRETATION OF THE FINDINGS & FURTHER RECOMMENDATIONS

If the patient was NPO at the time of the sonogram, then delayed outflow or foreign matter should be considered. If urine specific gravity is <1.020, then work up for pituitary dependent hyperadrenocorticism is recommended. The ALT elevation is likely owing to reactive hepatopathy. No overt evidence of neoplasia is present, however, given the gastric mucosal remodeling, some level of malassimilation of nutrients could be an issue.

For an additional charge, internal medicine consult can be utilized through SonoPath.com. You can select the internal medicine drop down at <http://spa.sonopath.com/>.

One of the world's top internists & SonoPath associate Dr. Remo Lobetti BVSc, MMedVet, PhD, DECVIM can evaluate your case through SonoPath. <https://sonopath.com/resources/sonopath-services/internal-medicine-teleconsultation-services>

Cushing Work UP

Efficient & Accurate Cushing's Work up-Lindquist

Notes regarding Cushing's Clinical Presentations:

Nearly all Cushing's dogs have SAP elevations and true PU/PD (USG < 1.025) and most are polyphagic. Cushing's dogs are > 6 years and usually > 9 years old, usually have poor skin coats, body scores > 3/5, and are usually sedentary animals.

Its important to remember that Cushing's dogs usually look and play the part and other diseases cause false + stress related cortisol spikes. On rare occasion a Cushing's dog will not follow the rules but this is truly an exception.

Potential Cushing's patient workups can be costly and frustrating if not definitive and, in my experience, the non-definitive patient usually has something else going on that may be contributing to some of the



PATIENT

Elmi Llanes

clinical signs a Cushing's dog will have, especially SAP elevations or PU/PD. Based on this prelude of information I came up with the following algorithm in the spirit of diagnostic efficiency.

SPECIES

Canine

The following suggested protocol is based on current available literature on Cushing's disease and extensive clinical-sonographic experience evaluation + Cushing's and False + LDDST & ACTH stim. cases in order to maximize the efficiency of a Cushing's workup in practice.

BREED

French Bulldog

Screen first, workup second

SEX

Spayed Female

1) **UA:** Repeatable (2-3 urine samples) Urine specific gravity & urine cortisol/creatinine ratio (UCCR): If **repeatable USG < 10.20 and + UCCR** move to next step 2.

AGE

7 Years

Note: UA is inexpensive and easy to obtain and if UA criteria is not met for Cushing's then resources can be spent into other more pertinent diagnostics or left on hold until the UA criteria is met in emerging Cushing's cases.

WEIGHT

22.2 Pounds

2) **Sonogram:** Does the patient **have concurrent disease** clinically or sonographically as non-Cushing's illness will influence the potential false + LDDST or even ACTH stim. The sonogram gives a global perspective of the internal health of the patient to be considered in the Cushing's workup as an assessment of concurrent disease. Is there a concurrent neoplastic process, UTI pancreatitis, mucocele....? Are the adrenals enlarged (Cushing's-PDH, stress, age related or breed variant), or atrophied (iatrogenic Cushing's or adrenal burnout), have asymmetric enlargement (Adrenal tumor, hyperplasia, adenoma, age related variant), or is there vascular invasion (Invasive pheo with false + UA criteria or adenocarcinoma or phrenic thrombosis)? The sonogram answers these questions proactively.

INTERPRETED BY

Eric Lindquist, DMV
DABVP, Cert. IVUSS

Address & treat concurrent disease first before performing Cushing's testing or testing will be artificially altered increasing false negatives and positives.

IMAGING PERFORMED BY

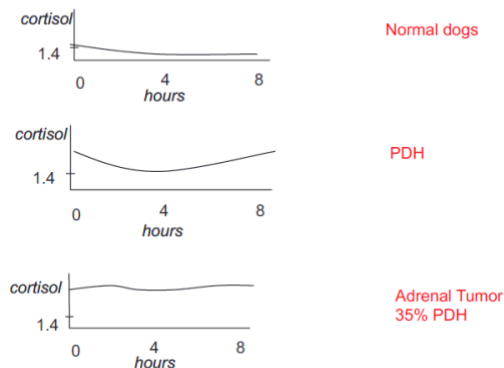
Guhrun Gunther

3) **LDDST** (0.01 D-Sodium phosphate mg/kg IV **with precise dosing******) (Better screening test but plagued with false + but considered more specific than ACTH stim) Use if there is potential early Cushing's or if adrenal asymmetry present on sonogram suspecting tumor. Use LDDST in cats at a higher dose (0.1 mg/kg IV). **Interpretation LDDST:** Look at 8-hour post first: If > 1.4 = Cushing's. Then look at 4-hour: if > 1.4 or > 50% baseline = Cushing's. 4-hour do then 8-hour spike most consistent with PDH. Flat line high constant curve without dip more consistent with tumor but can be PDH. See attached graph.

HOSPITAL NAME

New Frontier AMC

LDDS



REFERRING VET

Guhrun Gunther

INVOICE

23489

DATE

7/19/23



PATIENT

Courtesy: Rebecca Berg DACVIM, DECVIM

Elmi Llanes

SPECIES

Canine

BREED

French Bulldog

SEX

Spayed Female

AGE

7 Years

WEIGHT

22.2 Pounds

INTERPRETED BY

Eric Lindquist, DMV
DABVP, Cert. IVUSS

IMAGING PERFORMED BY

Gudrun Gunther

HOSPITAL NAME

New Frontier AMC

REFERRING VET

Gudrun Gunther

INVOICE

23489

DATE

7/19/23

4) **ACTH stim.** (Better confirming test but can have false +) Use if the patient “looks” Cushingoid or if bilateral adrenal enlargement is present, or high normal width on sonogram, or if iatrogenic Cushing’s suspected (Cortisone Tx in past). ACTH stim is better for diagnosis of Addison’s, Iatrogenic Cushing’s, and Cushing’s therapy monitoring but problematic with initial Cushing’s diagnosis. First dx LDDST is suggested.

5) If **diabetic** then run both LDDST & ACTH stim but stabilize as much as possible first.

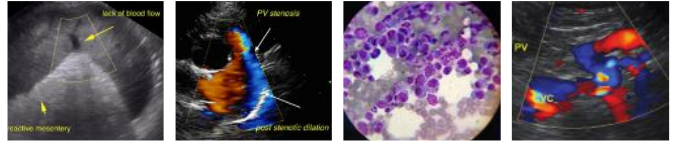
5) Run a **serial blood pressure** in a BP friendly non “white coat effect” atmosphere. Run at least 3 at different times over a few hours or when eating as the patient tends to be calm when eating or give Torbutrol when entering the facility. Cushing’s hypertension is usually 150-180 systolic range while pheochromocytoma range is more often > 180 systolic.

6) **Perform CT** of the pituitary to identify macro adenoma expansion if any lethargy or dullness or other central clinical CNS signs are minimally present. CT for adrenal may be more thorough for adrenalectomy surgical planning if ultrasound views of the CVC were problematic.

7) **Adrenalectomy** for adrenal mass is prescribed then it is essential to stabilize the patient first regarding secondary disease such as organ dysfunction, hypertension, diabetes mellitus, hypernatremia, thromboembolic risk urinary and other infection in order to minimize potential for operative and postoperative complications as they are common in adrenalectomy. Trilostane stabilization therapy for Cushing’s would be the first approach then address surgery and hypertension should be managed ideally < 160 systolic with ace inhibitors, phenoxybenzamine, or amlodipine.

Suggested reading:

Behrend EN, Kooistra HS, Nelson R, et al. Diagnosis of Spontaneous Canine Hyperadrenocorticism: 2012 ACVIM Consensus Statement (Small Animal). J Vet Intern Med 2013;27:1292–1304 .



PATIENT

Elmi Llanes

SPECIES

Canine

BREED

French Bulldog

SEX

Spayed Female

AGE

7 Years

WEIGHT

22.2 Pounds

INTERPRETED BY

Eric Lindquist, DMV
DABVP, Cert. IVUSS

IMAGING PERFORMED BY

Gudrun Gunther

HOSPITAL NAME

New Frontier AMC

REFERRING VET

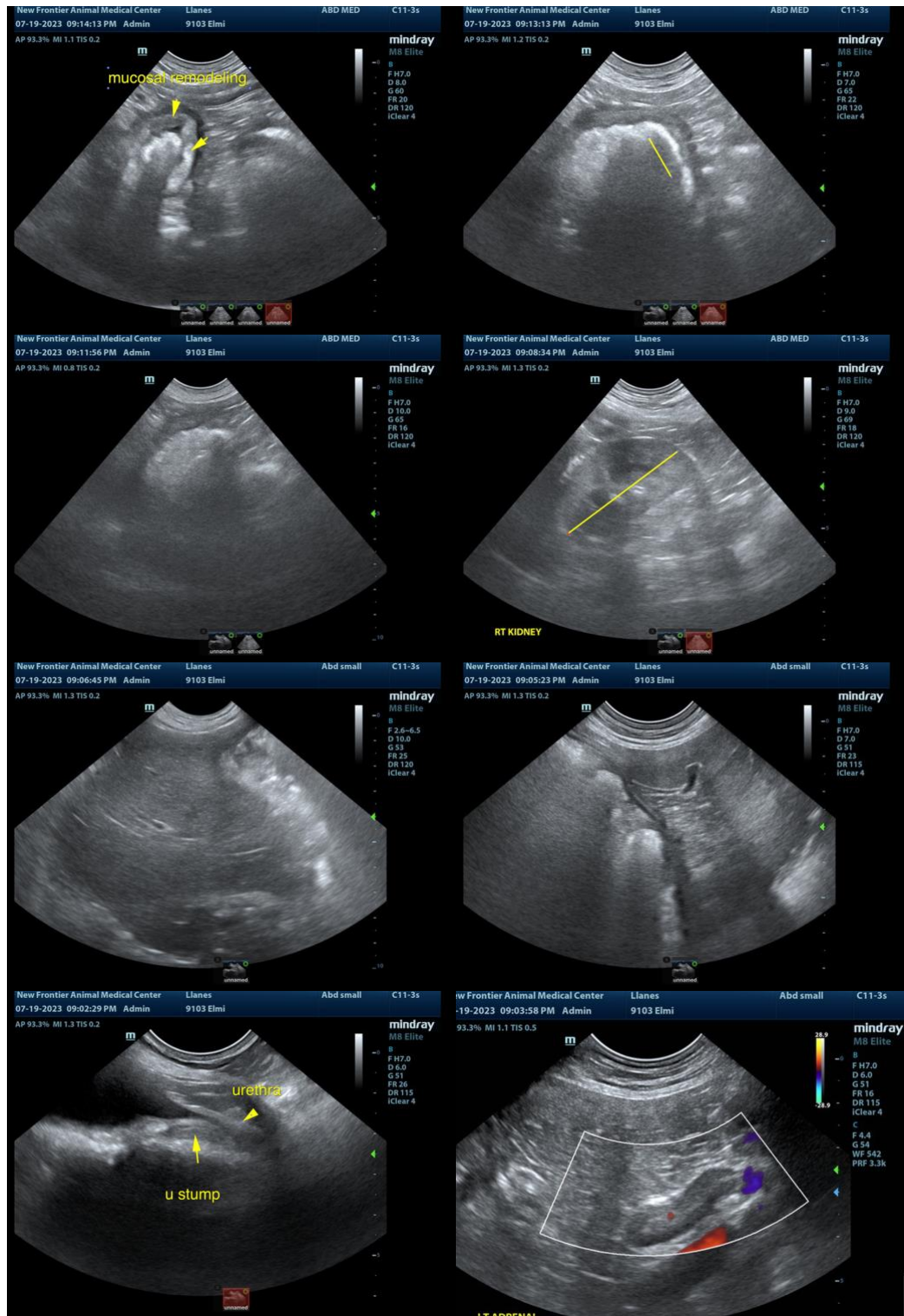
Gudrun Gunther

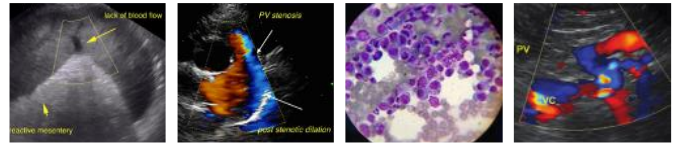
INVOICE

23489

DATE

7/19/23





PATIENT

Elmi Llanes

SPECIES

Canine

BREED

French Bulldog

SEX

Spayed Female

AGE

7 Years

WEIGHT

22.2 Pounds

INTERPRETED BY

Eric Lindquist, DMV
DABVP, Cert. IVUSS

IMAGING PERFORMED BY

Gudrun Gunther

HOSPITAL NAME

New Frontier AMC

REFERRING VET

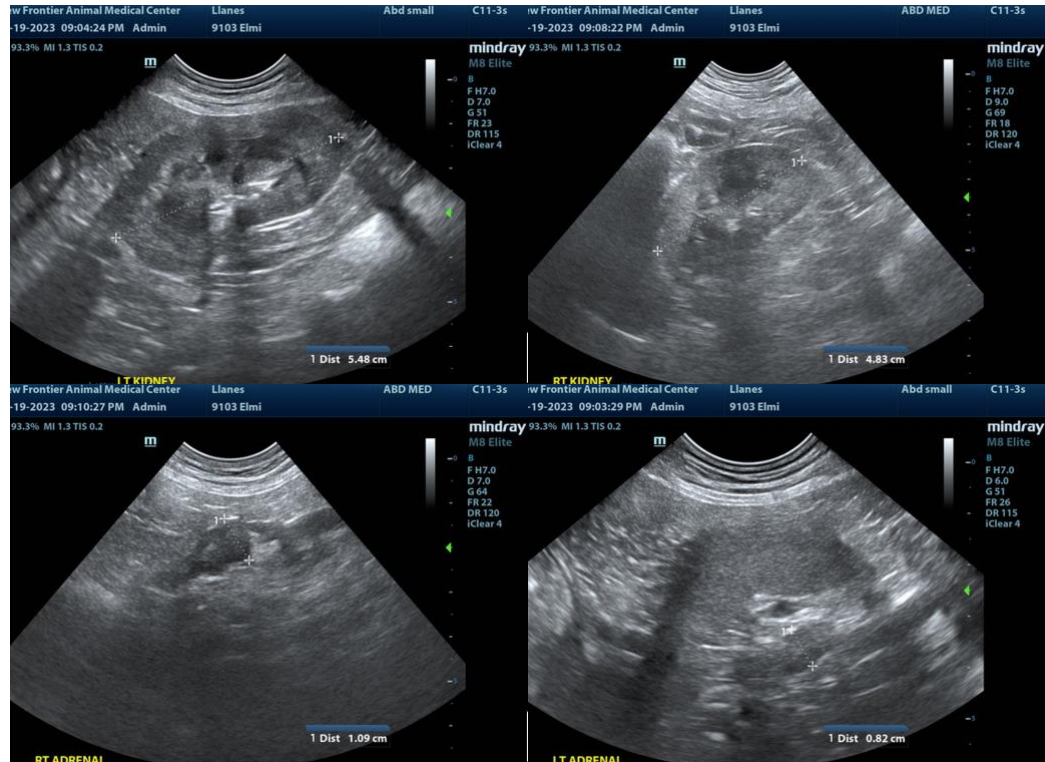
Gudrun Gunther

INVOICE

23489

DATE

7/19/23



The information and recommendations provided are based on the images presented by the referring veterinarian. No evaluation can be communicated regarding pathology that was not visible in the image/video clips provided.

Thank you for this referral. If the clinical or image interpretation does not parallel your findings or if I can be of any further assistance please contact me.

Eric Lindquist, DMV, DABVP, Cert. IVUSS, CEO of SonoPath.com
info@SonoPath.com