



**PATIENT**

Chester Velasco

**SPECIES**

Feline

**BREED**

DSH

**SEX**

Neutered Male

**AGE**

5 Years

**WEIGHT**

13.8 Pounds

**INTERPRETED BY**

Eric Lindquist, DMV

DABVP, Cert. IVUSS

**IMAGING PERFORMED BY**

Dr. A Rodriguez

**HOSPITAL NAME**

Foxfield Vet Services

**REFERRING VET**

Dr. A Rodriguez

**INVOICE**

44145

**DATE**

7/19/23

**PRESENTING CLINICAL SIGNS**

Monitoring progression of HCM. Prev echo 11/9/22 read by sonopath  
Abnormal PE/Chem/CBC/UA Results: N/A

**ULTRASONOGRAPHIC EXAMINATION OF THE HEART**

FELINE CARDIAC PARAMETERS	BODY WEIGHT (kg)	HR (BPM)	IVSd (cm)	LVIDd (cm)	LVWd (cm)	FS (%)	EF (%)
NORMAL PARAMETER	-----	150-240	0.3-0.6	1.0-2.1	0.25-0.6	35-67	80-100
PATIENT		NM	0.79	1.4	0.73	58	80
FELINE CARDIAC PARAMETERS	LA/AO (Boon)	LA/AO HEART BASE (Sisson)	LA 2D 4-chamber long axis AS to FW (Sisson) (cm)	LVOT VEL. (m/s)	RVOT VEL. (m/s)	IVRT (m/)	
NORMAL PARAMETER	<1.5	0.88-1.79	0.7-1.7	<1.6	<1.3	40-60	
PATIENT	1.31	1.3	1.4	1.8	0.7	NM	
Adapted from June Boon, Veterinary Echocardiography, 1998 Sisson D et al. JVIM 1991; 5: 232, Jacobs et al. Am J Vet Res 1985; 46:1705							

**Cardiac Presentation**

The cardiac presentation revealed persistent left ventricular hypertrophy with some level of remodeling. Contractility was compensatory and chamber sizes were normal. Mitral insufficiency and turbulence at the left ventricular outflow tract noted. The right heart was unremarkable with no significant disease. No pericardial or pleural effusion noted.

**ULTRASONOGRAPHIC FINDINGS**

- Compensated hypertrophic cardiomyopathy phenotype

**INTERPRETATION OF THE FINDINGS & FURTHER RECOMMENDATIONS**

No adjustment in medications warranted at this time. Recheck in 12 months unless clinical signs such as exercise intolerance or respiratory distress occur, or murmur grade increases.





**PATIENT**

Chester Velasco

**SPECIES**

Feline

**BREED**

DSH

**SEX**

Neutered Male

**AGE**

5 Years

**WEIGHT**

13.8 Pounds

**INTERPRETED BY**

Eric Lindquist, DMV  
DABVP, Cert. IVUSS

**IMAGING PERFORMED BY**

Dr. A Rodriguez

**HOSPITAL NAME**

Foxfield Vet Services

**REFERRING VET**

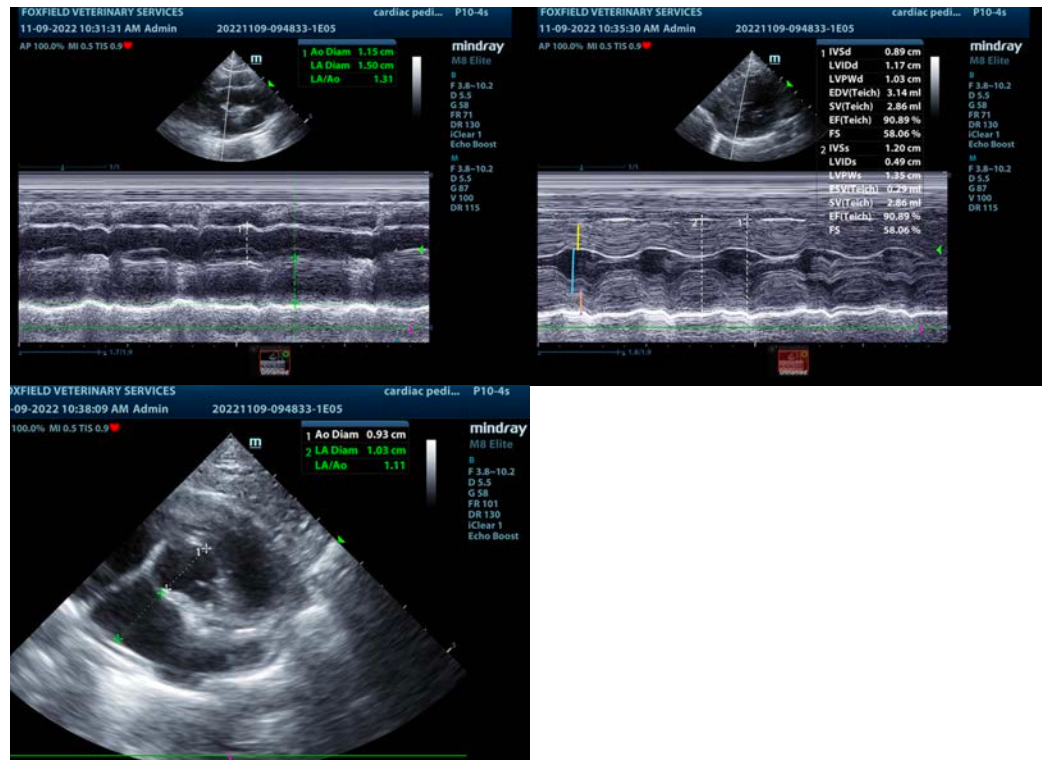
Dr. A Rodriguez

**INVOICE**

44145

**DATE**

7/19/23



The information and recommendations provided are based on the images presented by the referring veterinarian/sonographer. No evaluation can be communicated regarding pathology that was not visible in the image/video clips provided.

Thank you for this referral. If the clinical or image interpretation does not parallel your findings or if I can be of any further assistance please contact me.

**Eric Lindquist, DMV, DABVP, Cert. IVUSS, CEO of SonoPath.com**

[info@SonoPath.com](mailto:info@SonoPath.com)