



PATIENT PRESENTING CLINICAL SIGNS

Bruce Wigginton

Not eating or drinking for 2 days, lethargic and hiding, 103.2. Tender in abdomen. Position 11 positive murphy sign. Vomited overnight.

SPECIES

Feline

Abnormal PE/Chem/CBC/UA Results: CPLI=normal, WBC=16.08, Retics=0.9, suspected band cells, neutrophils=12.0, T4=1.6

BREED

DLH

SEX

Neutered Male

AGE

12 Years

WEIGHT

8.3

INTERPRETED BY

Eric Lindquist, DMV

DABVP, Cert. IVUSS

ULTRASONOGRAPHIC EXAMINATION OF THE HEART & ABDOMEN

FELINE CARDIAC PARAMETERS	BODY WEIGHT (kg)	HR (BPM)	IVSd (cm)	LVIDd (cm)	LVWd (cm)	FS (%)	EF (%)
NORMAL PARAMETER	-----	150-240	0.3-0.6	1.0-2.1	0.25-0.6	35-67	80-100
PATIENT		190	0.39	1.22	0.36	40	
FELINE CARDIAC PARAMETERS	LA/AO (Boon)	LA/AO HEART BASE (Sisson)	LA 2D 4-chamber long axis AS to FW (Sisson) (cm)	LVOT VEL. (m/s)	RVOT VEL. (m/s)	IVRT (m/)	
NORMAL PARAMETER	<1.5	0.88-1.79	0.7-1.7	<1.6	<1.3	40-60	
PATIENT	1.1	1.0	1.38	--	--	NM	
Adapted from June Boon, Veterinary Echocardiography, 1998 Sisson D et al. JVIM 1991; 5: 232, Jacobs et al. Am J Vet Res 1985; 46:1705							

IMAGING PERFORMED BY

Nicole Gotfredson

HOSPITAL NAME

Buffalo Vet Clinic

REFERRING VET

Dr. Garry Gotfredson

INVOICE

44148

DATE

7/19/23

Cardiac Presentation

The echocardiogram in this patient demonstrated normal **left atrial** size based on 3 separate LA measurements. The cranial and caudal **mitral** valve leaflets presented normal linear structure and kinetics. The **left ventricle** presented normal thicknesses with linear contour and was not dilated nor restricted. The **myocardium** presented normal echogenicity without subjective evidence of significant fibrotic or ischemic disease. **Contractility** of the ventricular walls was adequate and in normal range for this patient evidenced by the fractional shortening measurement and subjective evaluation of the different regions and angles of the myocardium. The **left ventricular outflow** tract demonstrated normal laminar flow and subjective structural integrity. The **right atrium** and auricle revealed normal size, structure and content. No evidence of masses was noted or chamber overload. **Tricuspid** valvular assessment demonstrated adequate linear morphology and kinetics. The **right ventricle** was of normal size (1/3 diameter of LV), chordae structure, myocardial echogenicity and thickness. **Pulmonic** tract assessment revealed normal valve structure, laminar flow, and diameter (approx. 1:1 pa/ao ratio). No visible **pericardial** or free pleura fluid was noted or extra cardiac pathology in the visible planes. The cranial **mediastinum** and **pericardial** regions were free of masses in the visible window.



PATIENT *Urinary System*

Bruce Wigginton

The **urinary bladder**, trigone, and pelvic urethra presented normal thicknesses and normal tone. The ureters were not visible which is normal. No uroliths or sediment were visualized and anechoic urine was present. No evidence of inflammatory or neoplastic changes were noted. Ureteral papillae were normal.

SPECIES

Feline

BREED

DLH

SEX

Neutered Male

The **kidneys** presented a relatively uniform cortical hyperechogenicity when compared to the renal medulla, spleen and liver. No overt masses were noted. Corticomedullary definition was nebulous and the ratio favored the cortex slightly. The ureters were not visible and assumed to be normal. These changes are most consistent with chronic interstitial nephritis yet infiltrative disease could not be entirely ruled out without biopsy though neoplasia is not suspected. Blood flow to the kidneys appeared to be moderately subnormal. The left kidney measured 3.9 cm. The right kidney measured 4.3 cm.

Adrenal Glands

The regions of the **adrenal glands** were unremarkable.

AGE

12 Years

Spleen

The **spleen** presented a smooth homogeneous parenchyma hyperechoic to liver and renal cortical parenchyma. The capsule was smooth without noticeable expansion or deviation from within the spleen or adjacent pathology. The splenic vasculature demonstrated normal volume without signs of congestion or thrombosis. No sonographic evidence of acute or chronic inflammatory, neoplastic, or infarctual changes were noted.

WEIGHT

8.3

INTERPRETED BY

Eric Lindquist, DMV

Liver

The **liver** images submitted revealed subjectively normal liver size, contour, and structure. Parenchymal echogenicity was naturally coarse and hypoechoic to the spleen. Vascular and biliary tracts were of normal volume with no evidence of congestion. The gallbladder presented acceptably thin walls with primarily anechoic content. The cystic and common bile ducts were normal. No pathological hepatic lymphadenopathy was evident. No overt structural evidence of inflammatory, infiltrative or regenerative pathology was evident.

DABVP, Cert. IVUSS

IMAGING PERFORMED BY

Nicole Gotfredson

HOSPITAL NAME

Buffalo Vet Clinic

Gastrointestinal

The **gastrointestinal tract** was structurally unremarkable. Minor amount of fluid-filled lumen and excessive gas noted.

REFERRING VET

Dr. Garry Gotfredson

Pancreas

The base and limbs of the **pancreas** were observed to be largely isoechoic to surrounding omental fat. Pancreatic duct and capsular contour were acceptably normal and parenchyma respected normal curvilinear patterns. No overt evidence of active inflammatory or neoplastic disease was noted.

INVOICE

44148

ULTRASONOGRAPHIC FINDINGS

DATE

7/19/23

- Normal echocardiogram, no evident of pathology
- Structurally unremarkable abdomen with moderate age related renal changes/interstitial nephrosis.
- Non-specific GI upset



PATIENT

Bruce Wigginton

SPECIES

Feline

BREED

DLH

SEX

Neutered Male

AGE

12 Years

WEIGHT

8.3

INTERPRETED BY

Eric Lindquist, DMV

DABVP, Cert. IVUSS

IMAGING PERFORMED BY

Nicole Gotfredson

HOSPITAL NAME

Buffalo Vet Clinic

REFERRING VET

Dr. Garry Gotfredson

INVOICE

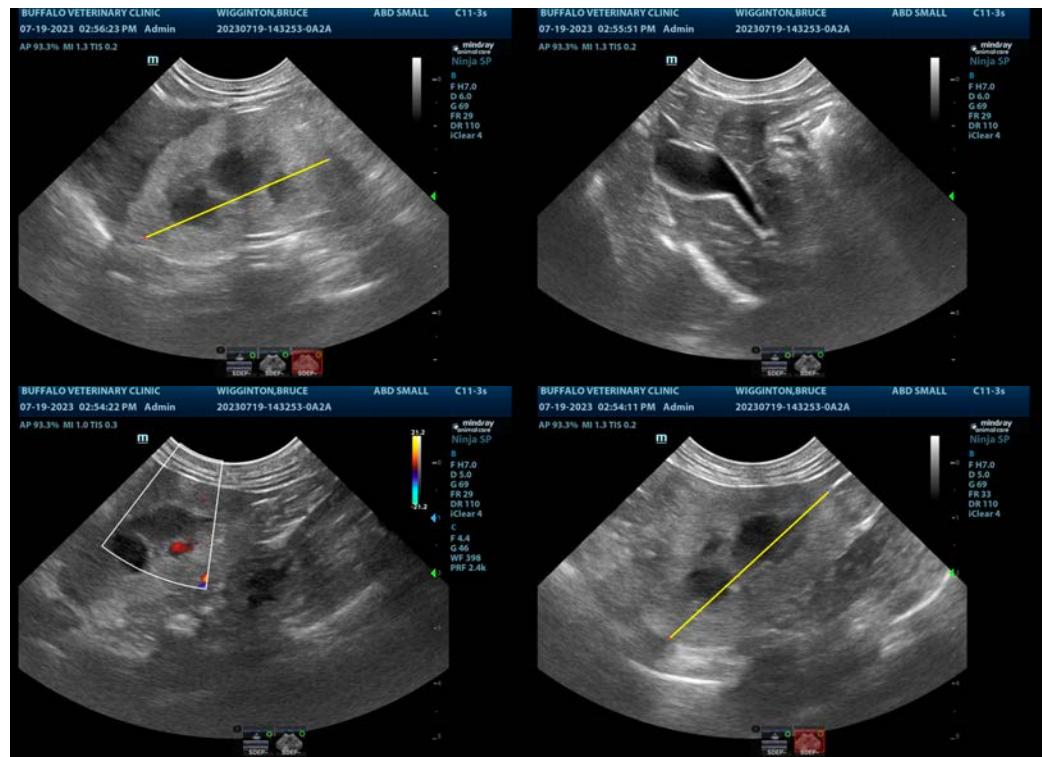
44148

DATE

7/19/23

INTERPRETATION OF THE FINDINGS & FURTHER RECOMMENDATIONS

There is no overt evidence of visceral disease that would be causing discomfort, but I cannot rule out low-grade pancreatitis that is not manifesting sonographically. Recommend assessing for potential referred back pain as cause of the tender abdomen in this patient. No evidence of significant disease. Supportive care should prove effective.





PATIENT

Bruce Wigginton

SPECIES

Feline

BREED

DLH

SEX

Neutered Male

AGE

12 Years

WEIGHT

8.3

INTERPRETED BY

Eric Lindquist, DMV

DABVP, Cert. IVUSS

IMAGING PERFORMED BY

Nicole Gotfredson

HOSPITAL NAME

Buffalo Vet Clinic

REFERRING VET

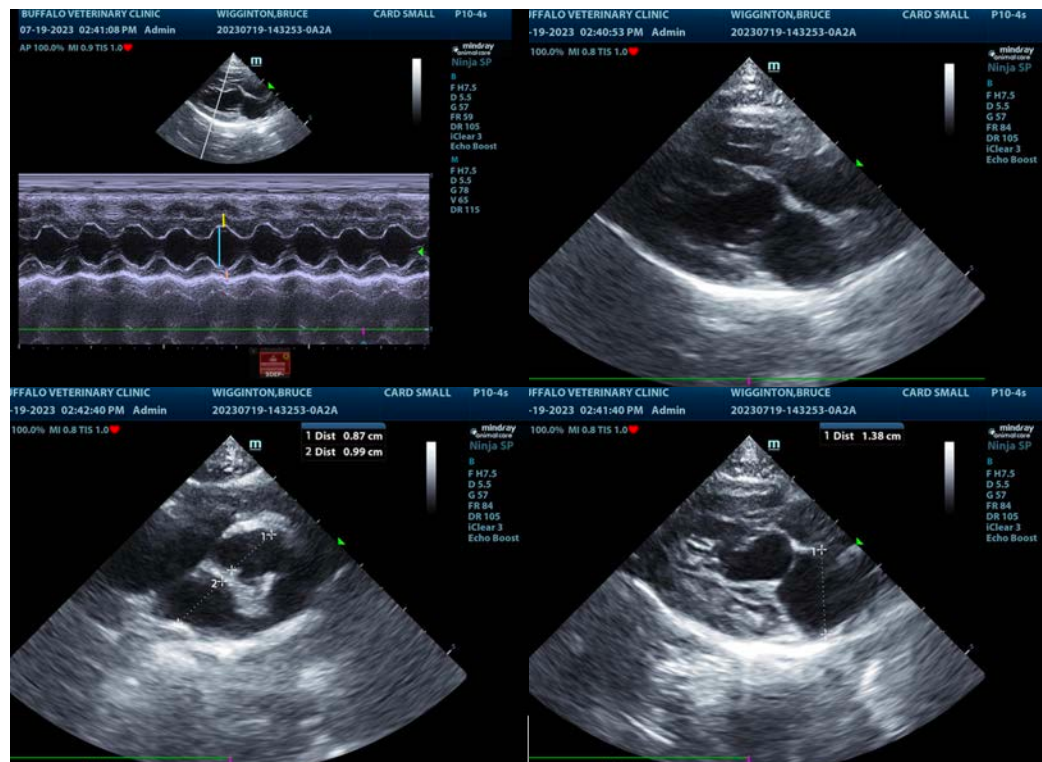
Dr. Garry Gotfredson

INVOICE

44148

DATE

7/19/23



The information and recommendations provided are based on the images presented by the referring veterinarian/sonographer. No evaluation can be communicated regarding pathology that was not visible in the image/video clips provided.

Thank you for this referral. If the clinical or image interpretation does not parallel your findings or if I can be of any further assistance please contact me.

Eric Lindquist, DMV, DABVP, Cert. IVUSS, CEO of SonoPath.com

info@SonoPath.com