SonoPath
Clinical Sonography & Telecytology

EDUCATIONAL TELECONSULTATION SERVICES™

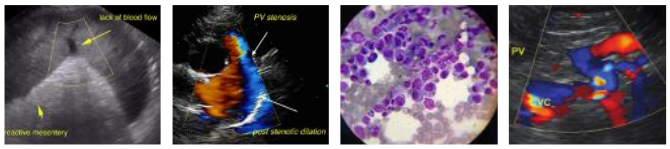

SonoPath.com
1-800-838-4268 info@sonopath.com

PATIENT

Zoey Velez

SPECIES

Canine

BREED

Yorkie

SEX

Spayed Female

AGE

9 Years

WEIGHT

9 Pounds

INTERPRETED BY

Eric Lindquist, DMV
DABVP, Cert. IVUSS

IMAGING PERFORMED BY

Eric Lindquist, DMV
DABVP, Cert. IVUSS

HOSPITAL NAME

Franklin Lakes AH

REFERRING VET

Dr. Ward

INVOICE

16701

DATE

7/19/22

PRESENTING CLINICAL SIGNS

History: Suspect nephrolithiasis + suspect left ureterolith (non-obstructive), hepatomegaly

Abnormal U/A findings: Protein 3+

Abnormal CBC/Chem Findings: Wnl

ULTRASONOGRAPHIC EXAMINATION OF THE ABDOMEN

Urinary System

The **urinary bladder** and visible pelvic urethra were unremarkable for the level of repletion presented. The urine, however, did present some mildly echogenic debris consistent with mucous, exfoliated cells from renal or bladder origin, and/or blood clots as these echogenic changes can all present similarly. This is often related to urinary tract infection but may represent simple evidence of exfoliated debris or sterile inflammation. Cystocentesis, urinalysis, +/- culture would be recommended to rule out and define any UTI.

The **kidneys** revealed largely normal size and structure, corticomedullary definition and ratio (cortex 1/3 of medulla) were essentially maintained with some age-related loss of curvilinear patterns regarding the capsule and C/M junction. The cortices presented largely uniform texture with some increased echogenicity expected for his age patient. Medullary structure differed distinctly from that of the cortex and no evidence of pelvic dilation was present. Mineralization was present in the kidneys. The largest calculus measured 4.0 mm. The left kidney measured 3.9 cm. The right kidney measured 3.7 cm.

Adrenal Glands

Both **adrenal glands** were visualized and recognized as having normal shape, size, position and echogenicity for this breed. The phrenic vasculature, glandular echogenicity and detail were unremarkable. Capsule, cortex, and medullary definition were normal for this age patient. The left adrenal gland measured 1.52 cm x 0.61 cm. The right adrenal gland measured 1.96 cm x 0.76 cm at the cranial pole and 0.63 cm at the caudal pole.

Spleen

The **spleen** presented a smooth homogeneous parenchyma hyperechoic to liver and renal cortical parenchyma. The capsule was smooth without noticeable expansion or deviation from within the spleen or adjacent pathology. The splenic vasculature demonstrated normal volume without signs of congestion or thrombosis. No sonographic evidence of acute or chronic inflammatory, neoplastic, or infarctual changes were noted.

Liver

The **liver** images submitted revealed subjectively normal liver size, contour, and structure. Parenchymal echogenicity was naturally coarse and hypoechoic to the spleen. Vascular and biliary tracts were of normal volume with no evidence of congestion. The gallbladder presented acceptably thin walls with primarily anechoic content. The cystic and common bile ducts were normal. No pathological hepatic lymphadenopathy was evident. No overt structural evidence of inflammatory, infiltrative or regenerative pathology was evident.

Gastrointestinal

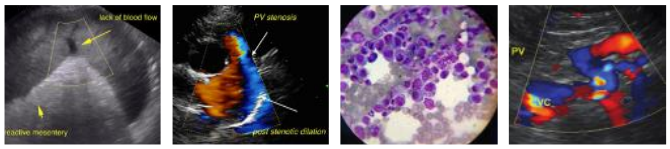

SonoPath.com
1-800-838-4268 info@sonopath.com

PATIENT

Zoey Velez

SPECIES

Canine

BREED

Yorkie

SEX

Spayed Female

AGE

9 Years

WEIGHT

9 Pounds

INTERPRETED BY

Eric Lindquist, DMV
DABVP, Cert. IVUSS

IMAGING PERFORMED BY

Eric Lindquist, DMV
DABVP, Cert. IVUSS

HOSPITAL NAME

Franklin Lakes AH

REFERRING VET

Dr. Ward

INVOICE

16701

DATE

7/19/22

Examination of the **gastrointestinal tract** revealed a stomach and intestine free of stasis, of normal wall thickness, acceptable curvilinear mural detail, and peristaltic activity. Small and large intestine demonstrated normal luminal chyme and stool consistency respectively. No obstructive or overt infiltrative disease was noted. No associated abnormal lymphatic activity was noted.

Pancreas

The base and limbs of the **pancreas** were observed to be largely isoechoic to surrounding omental fat. Pancreatic duct and capsular contour were acceptably normal and parenchyma respected normal curvilinear patterns. No overt evidence of active inflammatory or neoplastic disease was noted.

ULTRASONOGRAPHIC FINDINGS

- Nonobstructive renal calculi
- Urinary bladder debris

INTERPRETATION OF THE FINDINGS & FURTHER RECOMMENDATIONS

The patient may have passed a calculus recently given the patient history, however, the kidneys appear stable at this time.

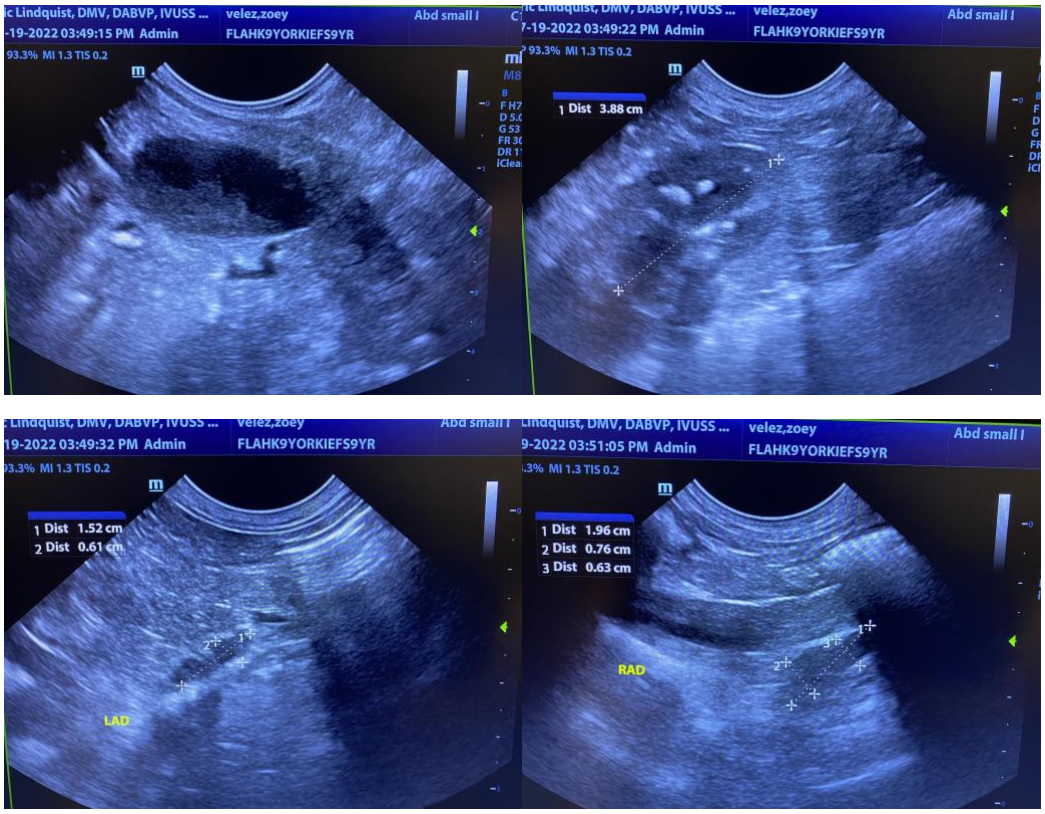

SonoPath
Clinical Sonography & Telecytology
EDUCATIONAL TELECONSULTATION SERVICES™

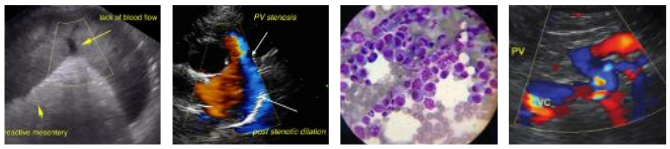

SonoPath.com
1-800-838-4268 info@sonopath.com

PATIENT

Zoey Velez

SPECIES

Canine

BREED

Yorkie

SEX

Spayed Female

AGE

9 Years

WEIGHT

9 Pounds

INTERPRETED BY

Eric Lindquist, DMV
DABVP, Cert. IVUSS

IMAGING PERFORMED BY

Eric Lindquist, DMV
DABVP, Cert. IVUSS

HOSPITAL NAME

Franklin Lakes AH

REFERRING VET

Dr. Ward

INVOICE

16701

DATE

7/19/22

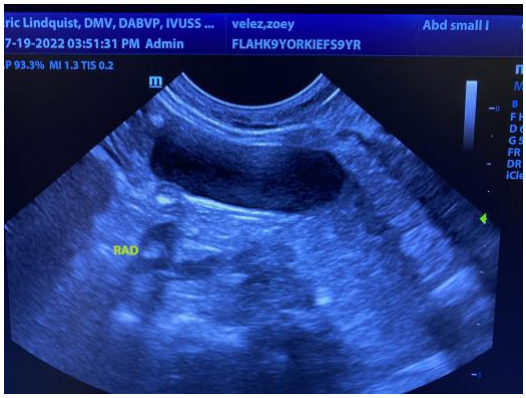

The information and recommendations provided are based on the images presented by the referring veterinarian. No evaluation can be communicated regarding pathology that was not visible in the image/video clips provided.

Thank you for this referral. If the clinical or image interpretation does not parallel your findings or if I can be of any further assistance please contact me.

Eric Lindquist, DMV, DABVP, Cert. IVUSS, CEO of SonoPath.com
info@SonoPath.com

Urolithiasis

http://www.sonopath.com/Urolithiasis

Description: Urolithiasis is defined as the formation of urinary calculi from the less soluble crystalloids present in urine as a result of multiple congenital and/or acquired physiological and pathological processes. Found in the urinary tract, uroliths are organized concretions comprised primarily of organic or inorganic crystalloids and a much smaller organic matrix. When 70% or more of the urolith is composed of one type of crystal, it is named for that crystal; secondary crystalloids can comprise up to 30% of its total weight. The urine is commonly supersaturated with crystalloids; however, evidence of individual crystals in the urine does not mean the animal is necessarily at risk for urolithiasis. Supersaturation of urine with crystalloids depends on the interaction of mineral elements in the urine, which are derived from the amount of solute ingested and excreted, as well as the volume of urine produced.

Urolithiasis should not be treated as a final diagnosis, but rather understood as a sequel of one or more underlying abnormalities. In dogs and cats, the majority of uroliths are found in the bladder

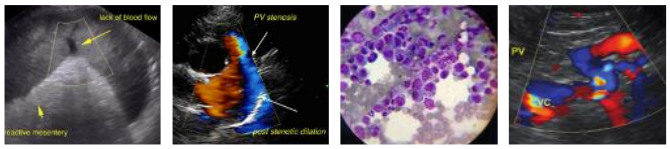

PATIENT
Zoey Velez

SPECIES
Canine

BREED
Yorkie

SEX
Spayed Female

AGE
9 Years

WEIGHT
9 Pounds

INTERPRETED BY
Eric Lindquist, DMV DABVP, Cert. IVUSS

IMAGING PERFORMED BY
Eric Lindquist, DMV DABVP, Cert. IVUSS

HOSPITAL NAME
Franklin Lakes AH

REFERRING VET
Dr. Ward

INVOICE
16701

DATE
7/19/22

or urethra. Urolith formation is often erratic and unpredictable, as several interrelated physiological and pathological factors are usually involved. Urolithiasis can also coexist with neoplasia. Bladder or urethral carcinoma often contains dystrophic mineralization within the neoplastic tissue that can be mistaken on radiographs for simple urolithiasis. Ultrasound examination can help differentiate urolithiasis form dystrophic mineralization associated with carcinoma. Conditions that contribute to crystallisation and urolith formation include:

- A high concentration of crystalloid material in the urine
- Urinary retention of crystalloid material
- Urinary stasis
- A urine pH that favors conditions for crystallisation
- UTIs, which can lead to the development of uroliths
- Diet
- Metabolic factors

Clinical Signs: Clinical signs are dependent on the number, type, and location of the urolith within the urinary tract. Because the majority of uroliths occur in the urinary bladder, one frequently observes signs of cystitis. In male dogs, small uroliths may lodge within the urethra, usually at the caudal end of the os penis. This results in complete or partial obstruction of the urethra, triggering bladder distension and postrenal azotemia. Occasionally, the urinary bladder or urethra may rupture resulting in ascites or subcutaneous perineal fluid accumulation, respectively, as well as postrenal azotemia. Unilateral renal uroliths may be asymptomatic or associated with hematuria and chronic pyelonephritis. Because bilateral renal uroliths are usually associated with pyelonephritis or obstruction, they often lead to renal failure.

Ureteral uroliths may be asymptomatic or associated with hematuria or abdominal pain. Unilateral, complete obstruction leads to a unilateral hydronephrosis with no evidence of decreased renal function.

Diagnostics: Because uroliths can cause trauma in the urinary tract, urinalysis often reveals proteinuria and hematuria. Crystalluria may be observed when uroliths are present and may also occur as an incidental finding without uroliths; however, if both exist concurrently, the identity of the crystal is usually the same as that of the urolith. Ultrasonography and survey and contrast radiographs can be used to diagnose and localize uroliths. Conducting a urine culture is important to exclude the possibility of a concurrent UTI. Once a urolith is collected, it must be quantitatively analyzed to determine its composition, which will help dictate preventative therapeutic measures. A retrospective review of 25,499 uroliths from 1985-2006 showed their composition to be comprised of one or more of the following: struvite, calcium oxalate, urate, apatite, brushite, cystine, silica, potassium magnesium pyrophosphate, sulfa drug, xanthine, and newberyite. Over

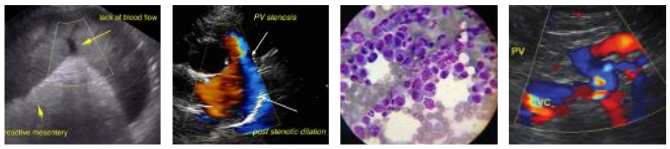

PATIENT

Zoey Velez

SPECIES

Canine

BREED

Yorkie

SEX

Spayed Female

AGE

9 Years

WEIGHT

9 Pounds

INTERPRETED BY

Eric Lindquist, DMV
DABVP, Cert. IVUSS

IMAGING PERFORMED BY

Eric Lindquist, DMV
DABVP, Cert. IVUSS

HOSPITAL NAME

Franklin Lakes AH

REFERRING VET

Dr. Ward

INVOICE

16701

DATE

7/19/22

the study period, there was a significant decrease in the proportion of struvite-containing uroliths and a significant increase in the proportion of oxalate-containing uroliths. There were also significant nonlinear decreases in the submission of urate-, silica-, and cystine-containing uroliths.

Treatment: Cystotomy and/or urethrotomy are often used in the management of urolithiasis. It is important to remember that surgery is often associated with a high rate of recurrence if the underlying cause is not addressed. The medical dissolution of struvite, urate, and cystine uroliths is often effective; however, it requires a high degree of owner compliance over a long period of time (weeks to months). Both dogs and cats should be fed diets appropriate to the type of urolith they have. In cases of ureteral stones, ureteral stenting can be performed to divert the urine from the renal pelvis into the urinary bladder. Stents are soft and biocompatible, made from a polyurethane-type material, and have a double pigtail shape, which allows the proximal pigtail loop to curl inside the renal pelvis. The shaft travels through the entire ureteral lumen, with the distal loop sitting inside the urinary bladder. These loops prevent stent migration and protect the entire ureter from obstruction. The ureteral stent results in passive ureteral dilation, which can permit passage of a previously obstructive ureterolith or allow urine to flow around the stones and the stent. A normal feline ureter is around 0.3-0.5 mm in diameter, and after a ureteral stent has been in place for some time (a few days up to approximately two weeks), the ureter diameter can reach up to 1.5 mm. In female cats, access is either attempted via cystoscopy in a retrograde manner or surgically in an antegrade manner; however, in most cats, the procedure is done surgically via a ventral midline incision. More recently, the subcutaneous urethral bypass (SUB) technique has also been employed to treat obstructive urolithiasis; it represents an even less invasive option.

References:

Berent A. Management of feline ureteral obstructions: an interventionalist's approach. Proceedings from the American College of Veterinary Surgeons Symposium, Chicago, IL, November 1-5, 2011.

Cannon AB, Ruby AL, Westropp JL, et al. Evaluation of trends in urolith composition in cats: 5,230 cases (1985-2004). *J Am Vet Med Assoc* 2007;231:570-76.

Fisher JR. Acute ureteral obstruction. In: August JR, ed. *Consultations in feline internal medicine, 5th ed*. Philadelphia PA: WB Saunders, 2005:379-87.

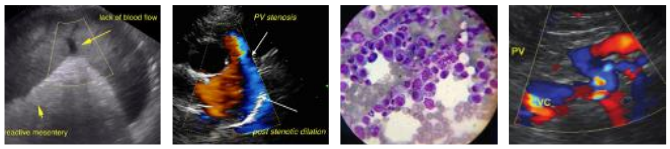

SonoPath.com
1-800-838-4268 info@sonopath.com

PATIENT

Zoey Velez

SPECIES

Canine

BREED

Yorkie

SEX

Spayed Female

AGE

9 Years

WEIGHT

9 Pounds

INTERPRETED BY

Eric Lindquist, DMV
DABVP, Cert. IVUSS

IMAGING PERFORMED BY

Eric Lindquist, DMV
DABVP, Cert. IVUSS

HOSPITAL NAME

Franklin Lakes AH

REFERRING VET

Dr. Ward

INVOICE

16701

DATE

7/19/22

Osborne CA, Lulich JP, Kruger JM, et al. Canine uroliths, feline uroliths, and feline urethral plugs from 1981 to 2007: perspectives from the Minnesota Urolith Center. *Vet Clin North Am Small Anim Pract* 2009;39:183-97.