



PATIENT

Shadow Enyart

SPECIES

Canine

BREED

Chihuahua Mix

SEX

Neutered Male

AGE

7 Years 10 Months

WEIGHT

13.6 Pounds

INTERPRETED BY

Eric Lindquist, DMV
DABVP, Cert. IVUSS

IMAGING PERFORMED BY

Leon Anderson, DVM

HOSPITAL NAME

Elizabeth AH

REFERRING VET

Leon Anderson, DVM

INVOICE

23464

DATE

7/18/23

PRESENTING CLINICAL SIGNS

Cardiac murmur discovered at wellness exam this month. Urolith discovered during ultrasound guided cystocentesis. No issues noted by owner.

Abnormal PE/Chem/CBC/UA Results: PE: Overweight, Left luxating patella, sclerosis of lenses normal for age. UA: Inflammatory, SG 1.040 CBC, Chem, cPL, BNP, Total and Free T4, Blood parasite, and Fecal all good. X-ray Abdomen: single bladder and single penile urethral stones

ULTRASONOGRAPHIC EXAMINATION OF THE HEART

CANINE CARDIAC PARAMETERS	MR VMAX (m/s)	TR VMAX (m/s)	LA/AO (Boon method)	LA/AO (Heart Base; Swe)	FS (%)	EF (%)	EPSS (cm)
NORMAL PARAMETER	4.5-5.5	<2.7	1.3	<1.6	28-40	40-100	<0.6
PATIENT	--	--	1.3	1.3	51	85	0.1
CANINE CARDIAC PARAMETERS	HR (BPM)	AV VMAX (m/s)	PV MAX (m/s)	BODY WEIGHT (kg)	LA 2D short axis Base view (cm)	LVIDd Avg; 2D and m-mode short axis (cm)	LVIDs Avg; 2D and m-mode short axis (cm)
NORMAL PARAMETER	50-100	0.7-1.7	0.7-1.6				
PATIENT	--	1.90	.94	--	1.9	1.79	--

Cardiac Presentation

The echocardiogram in this patient demonstrated normal **left atrial** size based on 3 different LA measurement methods. Chamber volumes and echogenicity were normal. Trivial turbulence was noted at the mitral valve, however, this is not clinically significant. The **left ventricle** presented thicknesses with linear contour and was not dilated nor restricted. The **myocardium** presented normal echogenicity without subjective evidence of significant fibrotic or ischemic disease. **Contractility** of the ventricular walls was adequate and in normal range for this patient evidenced by the fractional shortening measurement and subjective evaluation of the different regions of the myocardium. The **left ventricular outflow** tract demonstrated normal laminar flow and subjective structural integrity. The **right atrium** and auricle revealed normal size, structure and content. No evidence of masses was noted or chamber overload. **Tricuspid** valvular assessment demonstrated adequate linear morphology. The **right ventricle** was of normal size (1/3 diameter of LV), chordae structure, myocardial echogenicity and thickness. **Pulmonic** tract assessment revealed normal valve structure, laminar flow, and diameter (approx.1:1 pa/ao ratio). No visible **pericardial** or free pleura fluid was noted. No echographically detectable evidence of infiltrative disease was visible. The cranial **mediastinum and pericardial regions** were free of masses in the visible window.

ULTRASONOGRAPHIC FINDINGS



PATIENT

Shadow Enyart

- Essentially normal echocardiogram with trivial turbulence, likely mitral origin, yet barely detectable. No evidence of cardiac disease.

INTERPRETATION OF THE FINDINGS & FURTHER RECOMMENDATIONS

No contraindication to anesthetic procedure, if necessary.

SPECIES

Canine

BREED

Chihuahua Mix

SEX

Neutered Male

AGE

7 Years 10 Months

WEIGHT

13.6 Pounds

INTERPRETED BY

Eric Lindquist, DMV
DABVP, Cert. IVUSS

IMAGING PERFORMED BY

Leon Anderson, DVM

HOSPITAL NAME

Elizabeth AH

REFERRING VET

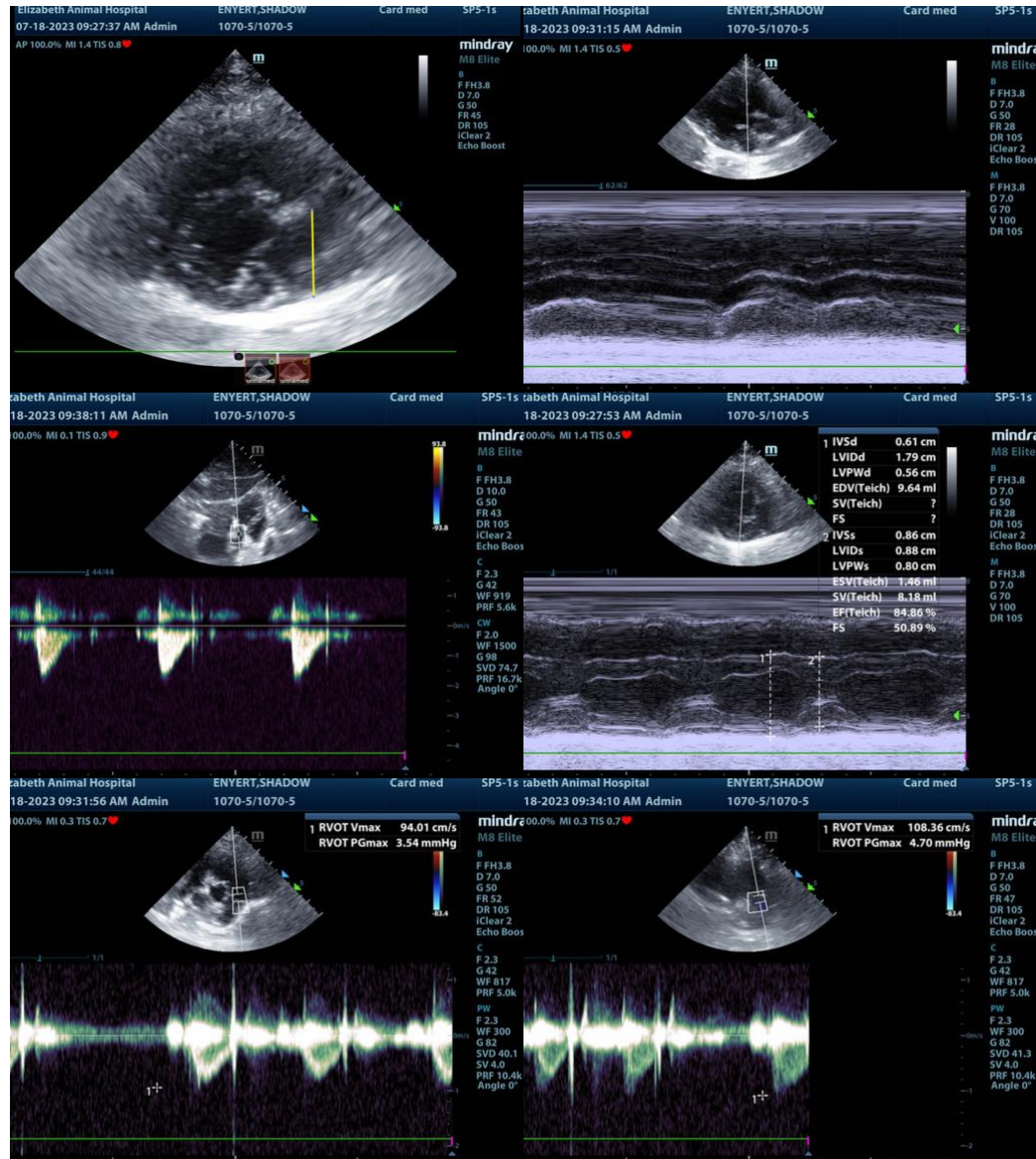
Leon Anderson, DVM

INVOICE

23464

DATE

7/18/23



The information and recommendations provided are based on the images presented by the referring veterinarian. No evaluation can be communicated regarding pathology that was not visible in the image/video clips provided.

Thank you for this referral. If the clinical or image interpretation does not parallel your findings or if I can be of any further assistance please contact me.



PATIENT

Shadow Enyart

Eric Lindquist, DMV, DABVP, Cert. IVUSS, CEO of SonoPath.com
info@SonoPath.com

SPECIES

Canine

BREED

Chihuahua Mix

SEX

Neutered Male

AGE

7 Years 10 Months

WEIGHT

13.6 Pounds

INTERPRETED BY

Eric Lindquist, DMV
DABVP, Cert. IVUSS

**IMAGING
PERFORMED BY**

Leon Anderson, DVM

HOSPITAL NAME

Elizabeth AH

REFERRING VET

Leon Anderson, DVM

INVOICE

23464

DATE

7/18/23