



**PATIENT**

Rusty Finnegan

**SPECIES**

Canine

**BREED**

Pomeranian Mix

**SEX**

Neutered Male

**AGE**

9 Years

**WEIGHT**

15 Pounds

**INTERPRETED BY**

Eric Lindquist, DMV  
DABVP, Cert. IVUS

**IMAGING PERFORMED BY**

Anthony Smatt

**HOSPITAL NAME**

The Pets I Love

**REFERRING VET**

Anthony Smatt

**INVOICE**

23479

**DATE**

7/18/23

**PRESENTING CLINICAL SIGNS**

History: patient seems to be very painful in the abdomen, panting and grunting. sometimes cranial abdomen would be hard.

**ULTRASONOGRAPHIC EXAMINATION OF THE ABDOMEN**

**Urinary System**

The **urinary bladder**, trigone, and pelvic urethra presented normal thicknesses and normal tone. The ureters were not visible which is normal. No uroliths or sediment were visualized and anechoic urine was present. No evidence of inflammatory or neoplastic changes were noted. Ureteral papillae were normal.

The **kidneys** revealed largely normal size and structure, corticomedullary definition and ratio (cortex 1/3 of medulla) were essentially maintained with some minor age-related loss of curvilinear patterns regarding the capsule and C/M junction. The cortices presented largely uniform texture with some increased echogenicity expected for his age patient. Medullary structure differed distinctly from that of the cortex and no evidence of pelvic dilation was present. The right kidney measured 4.0 cm. The left kidney measured 4.0 cm.

**Adrenal Glands**

The **left adrenal gland** was visualized and recognized as having normal shape, size, position and echogenicity for this breed. The phrenic vasculature, glandular echogenicity and detail were unremarkable. Capsule, cortex, and medullary definition were normal for this age patient. The left adrenal gland measured 0.52 cm at the cranial pole and 0.46 cm at the cranial pole.

The **right adrenal gland** measured the upper limits of normal at 0.8 cm at the cranial pole and 0.66 cm at the caudal pole.

**Spleen**

The **spleen** presented a smooth homogeneous parenchyma hyperechoic to liver and renal cortical parenchyma. The capsule was smooth without noticeable expansion or deviation from within the spleen or adjacent pathology. The splenic vasculature demonstrated normal volume without signs of congestion or thrombosis. No sonographic evidence of acute or chronic inflammatory, neoplastic, or infarctual changes were noted.

**Liver**

The **liver** images submitted revealed subjectively normal liver size, contour, and structure. Parenchymal echogenicity was naturally coarse and hypoechoic to the spleen. Vascular and biliary tracts were of normal volume with no evidence of congestion. The gallbladder presented acceptably thin walls with primarily anechoic content. The cystic and common bile ducts were normal. No pathological hepatic lymphadenopathy was evident. No overt structural evidence of inflammatory, infiltrative or regenerative pathology was evident.

**Gastrointestinal**

Examination of the **gastrointestinal tract** revealed a stomach and intestine free of stasis, of normal wall thickness, acceptable curvilinear mural detail, and peristaltic activity. Small and large intestine



## PATIENT

Rusty Finnegan

demonstrated normal luminal chyme and stool consistency respectively. No obstructive or overt infiltrative disease was noted. No associated abnormal lymphatic activity was noted.

## Pancreas

## SPECIES

Canine

The base and limbs of the **pancreas** were observed to be largely isoechoic to surrounding omental fat. Pancreatic duct and capsular contour were acceptably normal and parenchyma respected normal curvilinear patterns. No overt evidence of active inflammatory or neoplastic disease was noted.

## BREED

Pomeranian Mix

## ULTRASONOGRAPHIC FINDINGS

- Structurally normal abdomen
- Age-related renal changes
- Right adrenal gland measured the upper limits of normal.

## SEX

Neutered Male

## INTERPRETATION OF THE FINDINGS & FURTHER RECOMMENDATIONS

No evidence of visceral disease responsible for the abdominal pain. Referred back pain should be investigated in this patient.

## AGE

9 Years

## WEIGHT

15 Pounds

## INTERPRETED BY

Eric Lindquist, DMV  
DABVP, Cert. IVUSS

## IMAGING PERFORMED BY

Anthony Smatt

## HOSPITAL NAME

The Pets I Love

## REFERRING VET

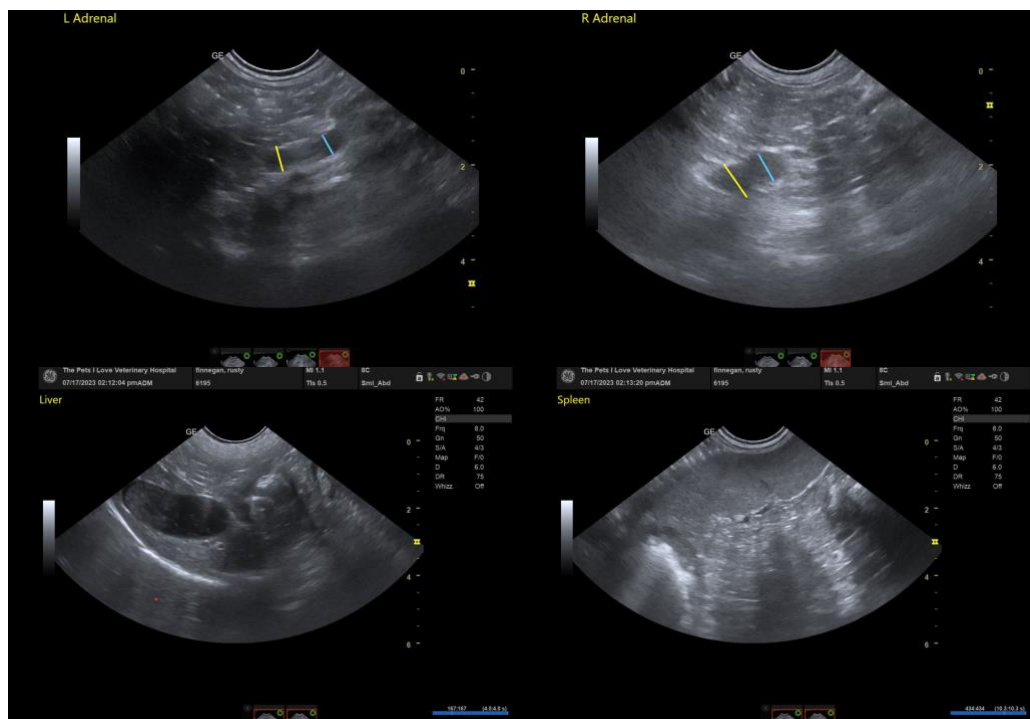
Anthony Smatt

## INVOICE

23479

## DATE

7/18/23





## PATIENT

Rusty Finnegan

## SPECIES

Canine

## BREED

Pomeranian Mix

## SEX

Neutered Male

## AGE

9 Years

## WEIGHT

15 Pounds

## INTERPRETED BY

Eric Lindquist, DMV  
DABVP, Cert. IVUSS

## IMAGING PERFORMED BY

Anthony Smatt

## HOSPITAL NAME

The Pets I Love

## REFERRING VET

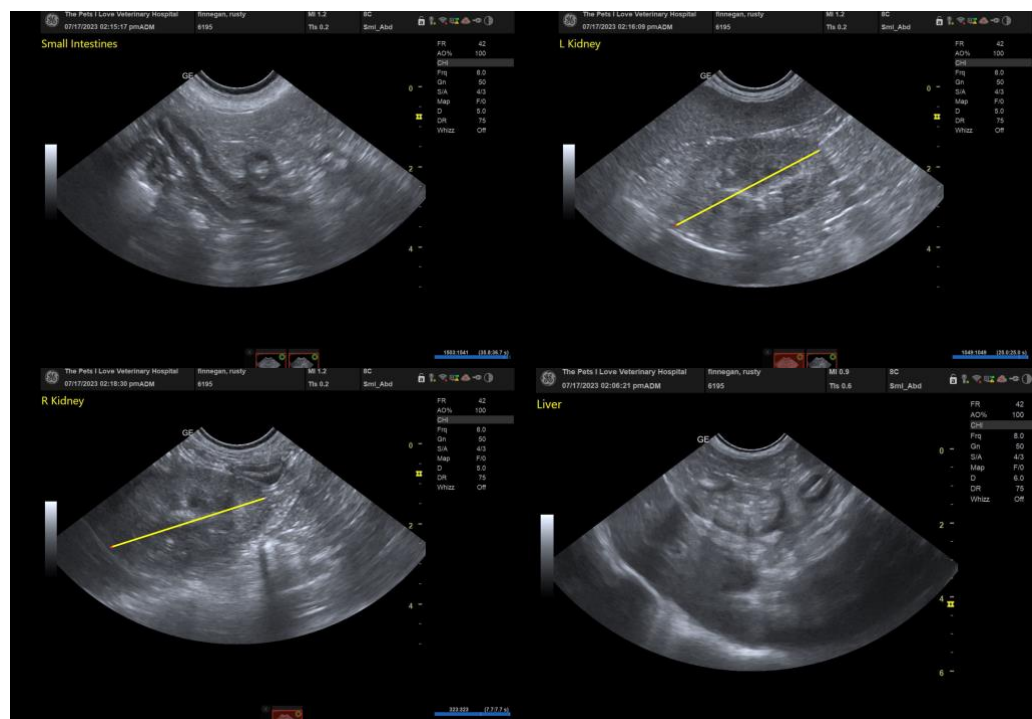
Anthony Smatt

## INVOICE

23479

## DATE

7/18/23



**The information and recommendations provided are based on the images presented by the referring veterinarian. No evaluation can be communicated regarding pathology that was not visible in the image/video clips provided.**

Thank you for this referral. If the clinical or image interpretation does not parallel your findings or if I can be of any further assistance please contact me.

**Eric Lindquist**, DMV, DABVP, Cert. IVUSS, CEO of SonoPath.com  
info@SonoPath.com