



PATIENT

Lily Bajaj

SPECIES

Canine

BREED

Golden Retriever

SEX

Female

AGE

15 Weeks

WEIGHT

16.4

INTERPRETED BY

Eric Lindquist, DMV

DABVP, Cert. IVUSS

IMAGING PERFORMED BY

Jenn

HOSPITAL NAME

Rockaway AH

REFERRING VET

Dr. Maniar

INVOICE

23442

DATE

6/18/23

PRESENTING CLINICAL SIGNS

Recheck yesterday showed gastric structure possible meds or foreign material.

RAPID RECHECK OF THE GI TRACT

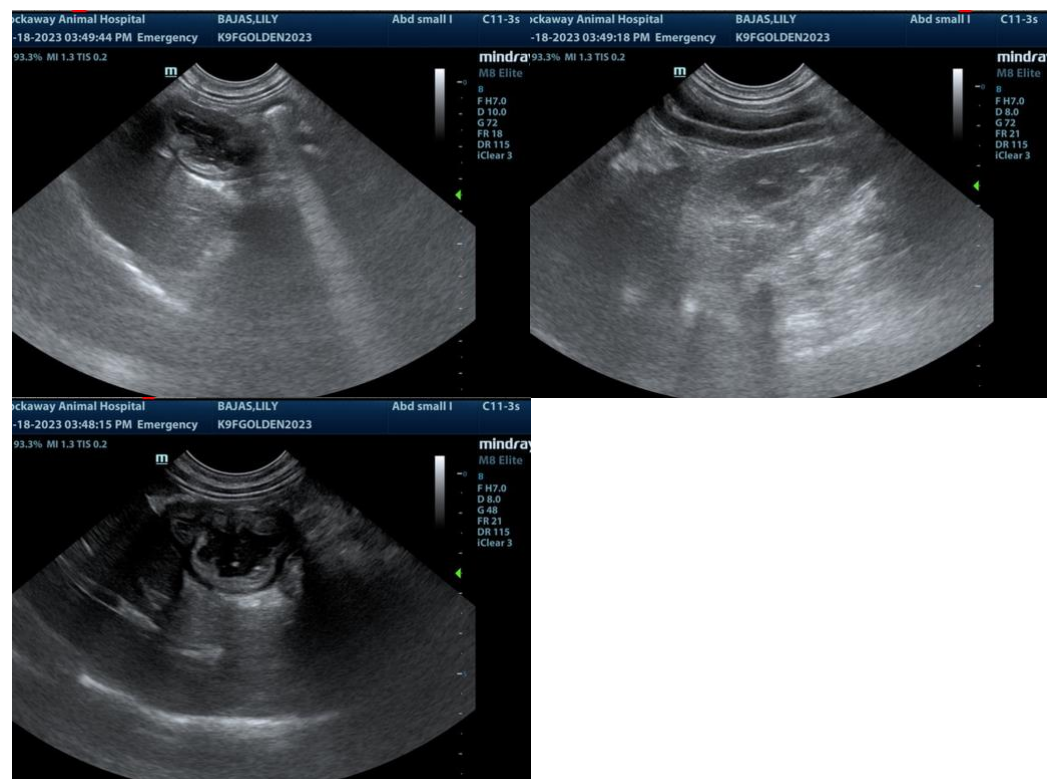
The stomach revealed fluid filled lumen with normal wall structure. The pylorus was patent, as was the small intestine. Soft stool was noted in the colon. Some transit of chyme appeared to be present in the small intestine.

ULTRASONOGRAPHIC FINDINGS

- Minor gastric fluid yet no obstructive disease noted.

INTERPRETATION OF THE FINDINGS & FURTHER RECOMMENDATIONS

Supportive care should prove effective.



The information and recommendations provided are based on the images presented by the referring veterinarian/sonographer. No evaluation can be communicated regarding pathology that was not visible in the image/video clips provided.

Thank you for this referral. If the clinical or image interpretation does not parallel your findings or if I can be of any further assistance please contact me.



PATIENT

Eric Lindquist, DMV, DABVP, Cert. IVUSS, CEO of SonoPath.com

Lily Bajaj

info@sonopath.com

SPECIES

Canine

BREED

Golden Retriever

SEX

Female

AGE

15 Weeks

WEIGHT

16.4

INTERPRETED BY

Eric Lindquist, DMV

DABVP, Cert. IVUSS

**IMAGING
PERFORMED BY**

Jenn

HOSPITAL NAME

Rockaway AH

REFERRING VET

Dr. Maniar

INVOICE

23442

DATE

6/18/23