



PATIENT PRESENTING CLINICAL SIGNS

Eros Stroker Increased urination, urinating outside of box.

SPECIES ULTRASONOGRAPHIC EXAMINATION OF THE ABDOMEN

Feline **Urinary System**

BREED The **urinary bladder**, trigone, and pelvic urethra presented normal thicknesses and normal tone. The ureters were not visible which is normal. No uroliths or sediment were visualized and anechoic urine was present. No evidence of inflammatory or neoplastic changes were noted. Ureteral papillae were normal. The pelvic urethra was imaged 2.0 cm beyond the cystourethral junction.

DSH

SEX

Neutered Male

AGE

3

The **kidneys** revealed normal size and structure, corticomedullary definition and ratio for this age. The cortices presented largely uniform texture with normal echogenic relationship to liver and spleen. Medullary structure differed distinctly from the cortex and no evidence of pelvic dilation was present. The capsules were acceptably uniform without significant irregularities. A cortical infarct was noted at the cranial pole of the left kidney. The right kidney measured 4.35 cm. The left kidney measured 3.74 cm. Blood flow to the kidneys appeared to be adequate on power doppler assessment.

WEIGHT

13.2

Adrenal Glands

The regions of the **adrenal glands** revealed no evident pathology.

INTERPRETED BY

Eric Lindquist, DMV

DABVP, Cert. IVUSS

Spleen

The **spleen** presented a smooth homogeneous parenchyma hyperechoic to liver and renal cortical parenchyma. The capsule was smooth without noticeable expansion or deviation from within the spleen or adjacent pathology. The splenic vasculature demonstrated normal volume without signs of congestion or thrombosis. No sonographic evidence of acute or chronic inflammatory, neoplastic, or infarctual changes were noted.

IMAGING PERFORMED BY

Jenn

HOSPITAL NAME

Rockaway AH

Liver

The **liver** images submitted revealed subjectively normal liver size, contour, and structure. Parenchymal echogenicity was naturally coarse and hypoechoic to the spleen. Vascular and biliary tracts were of normal volume with no evidence of congestion. Duplicated gallbladder was noted, not pathological.

REFERRING VET

Dr. Maniar

Gastrointestinal

Examination of the **gastrointestinal tract** revealed a stomach and intestine free of stasis, of normal wall thickness, acceptable curvilinear mural detail, and peristaltic activity. Small and large intestine demonstrated normal luminal chyme and stool consistency respectively. No obstructive or overt infiltrative disease was noted. No associated abnormal lymphatic activity was noted.

INVOICE

23443

DATE

7/18/23

Pancreas

The base and limbs of the **pancreas** were observed to be largely isoechoic to surrounding omental fat. Pancreatic duct and capsular contour were acceptably normal and parenchyma respected normal curvilinear patterns. No overt evidence of active inflammatory or neoplastic disease was noted.



PATIENT

Eros Stroker

SPECIES

Feline

BREED

DSH

SEX

Neutered Male

AGE

3

WEIGHT

13.2

INTERPRETED BY

Eric Lindquist, DMV

DABVP, Cert. IVUSS

IMAGING PERFORMED BY

Jenn

HOSPITAL NAME

Rockway AH

REFERRING VET

Dr. Maniar

INVOICE

23443

DATE

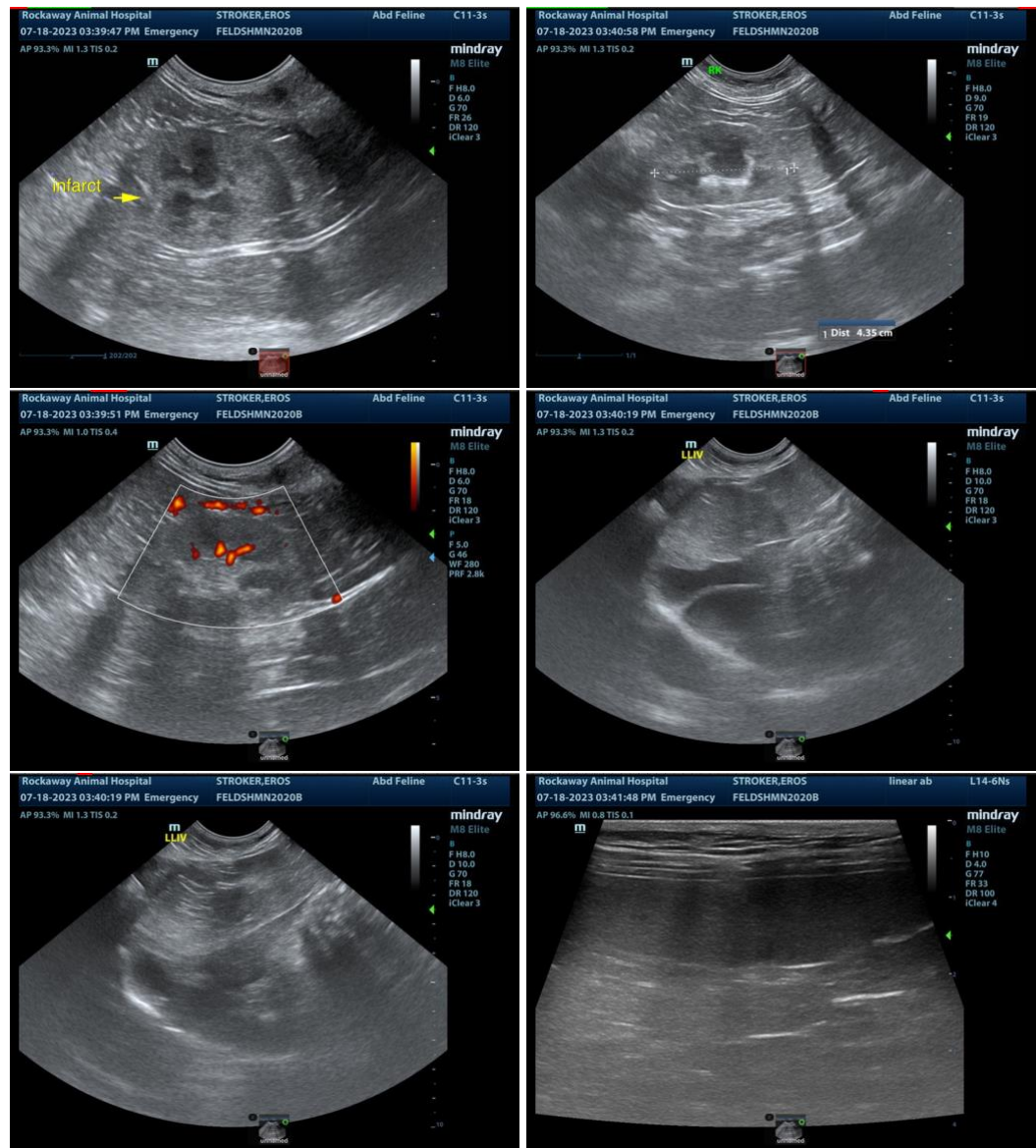
7/18/23

ULTRASONOGRAPHIC FINDINGS

- Stable left renal infarct
- Duplicated gallbladder, congenital variant- not pathological

INTERPRETATION OF THE FINDINGS & FURTHER RECOMMENDATIONS

No other evidence of pathology was noted. Full urinary work up is warranted if not already performed. Assessment for environmental stressors and UTI is indicated given the patient history.





PATIENT

Eros Stroker

The information and recommendations provided are based on the images presented by the referring veterinarian/sonographer. No evaluation can be communicated regarding pathology that was not visible in the image/video clips provided.

SPECIES

Feline

Thank you for this referral. If the clinical or image interpretation does not parallel your findings or if I can be of any further assistance please contact me.

BREED

DSH

Eric Lindquist, DMV, DABVP, Cert. IVUSS, CEO of SonoPath.com

info@SonoPath.com

SEX

Neutered Male

AGE

3

WEIGHT

13.2

INTERPRETED BY

Eric Lindquist, DMV

DABVP, Cert. IVUSS

IMAGING PERFORMED BY

Jenn

HOSPITAL NAME

Rockaway AH

REFERRING VET

Dr. Maniar

INVOICE

23443

DATE

7/18/23