



PATIENT

PRESENTING CLINICAL SIGNS

Broccoly Holub

Newly diagnosed 2/6 heart murmur within the last 3 months.

SPECIES

Abnormal PE/Chem/CBC/UA Results: WNL. On Origin Kibble and Farmers bog.

Canine

ULTRASONOGRAPHIC EXAMINATION OF THE HEART

BREED

Mix

SEX

Neutered Male

AGE

3

WEIGHT

65

CANINE CARDIAC PARAMETERS	MR VMAX (m/s)	TR VMAX (m/s)	LA/AO (Boon method)	LA/AO (Heart Base; Swe)	FS (%)	EF (%)	EPSS (cm)
NORMAL PARAMETER	4.5-5.5	<2.7	1.3	<1.6	28-40	40-100	<0.6
PATIENT	--	--	1.0	1.0	--	--	0.1
CANINE CARDIAC PARAMETERS	HR (BPM)	AV VMAX (m/s)	PV MAX (m/s)	BODY WEIGHT (kg)	LA 2D short axis Base view (cm)	LVIDd Avg; 2D and m-mode short axis (cm)	LVIDs Avg; 2D and m-mode short axis (cm)
NORMAL PARAMETER	50-100	0.7-1.7	0.7-1.6				
PATIENT	--	1.60	.90	--	4.3	3.6	--

INTERPRETED BY

Eric Lindquist, DMV
DABVP, Cert. IVUSS

Cardiac Presentation

The echocardiogram in this patient demonstrated normal **left atrial** size based on 3 separate methods of LA evaluation. The cranial and caudal **mitral** valve leaflets presented normal linear structure, extension in systole, and union in diastole with normal kinesis. The **left ventricle** presented thicknesses with linear contour and was not dilated nor restricted. The **myocardium** presented normal echogenicity without subjective evidence of significant fibrotic or ischemic disease.

Contractility of the ventricular walls was adequate and in normal range for this patient evidenced by the fractional shortening measurement and subjective evaluation of the different regions of the myocardium. The **left ventricular outflow** tract demonstrated normal laminar flow and subjective structural integrity. The **right atrium** and auricle revealed normal size, structure and content. No evidence of masses was noted. **Tricuspid** valvular assessment demonstrated adequate linear morphology and kinesis. The **right ventricle** was of normal size (1/3 diameter of LV), chordae structure, myocardial echogenicity and thickness. **Pulmonary outflow** tract assessment revealed normal valve structure, laminar flow, and diameter (approx.1:1 pa/ao ratio). No visible **pericardial** or free pleura fluid was noted. The cranial **mediastinum and pericardial and extra-cardiac regions** were free of masses in the visible window. Arrhythmogenic activity was noted.

IMAGING PERFORMED BY

Christensen

HOSPITAL NAME

Tranquility VC

REFERRING VET

House

INVOICE

23466

DATE

7/18/23

ULTRASONOGRAPHIC FINDINGS

- Arrhythmogenic activity
- Structurally normal heart
- Normal outflow velocities



PATIENT

Broccoly Holub

SPECIES

Canine

BREED

Mix

SEX

Neutered Male

AGE

3

WEIGHT

65

INTERPRETED BY

Eric Lindquist, DMV
DABVP, Cert. IVUSS

IMAGING PERFORMED BY

Christensen

HOSPITAL NAME

Tranquility VC

REFERRING VET

House

INVOICE

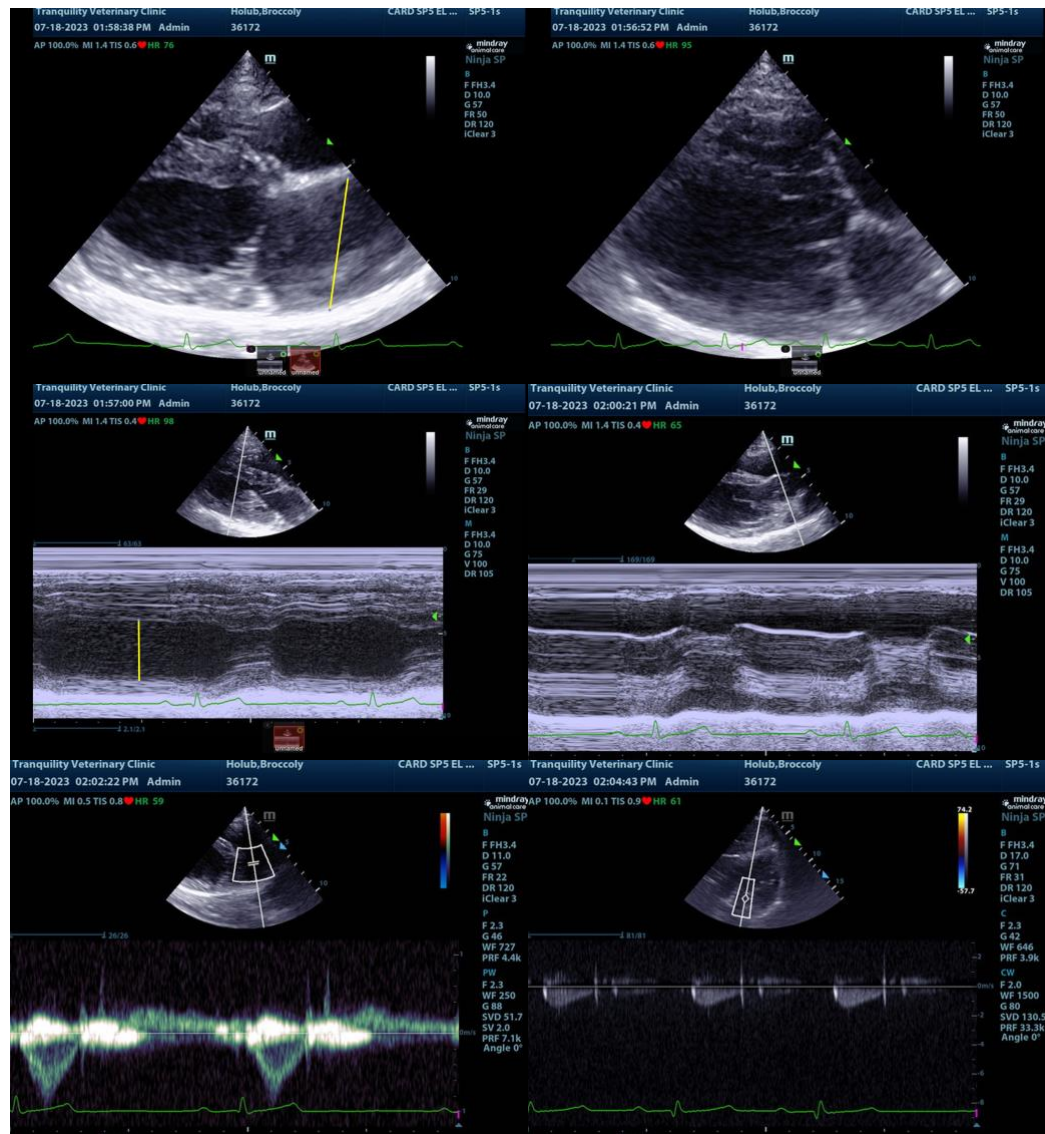
23466

DATE

7/18/23

INTERPRETATION OF THE FINDINGS & FURTHER RECOMMENDATIONS

The exact cause of the murmur is unclear. Potentially idiopathic flow murmur. No evidence of significant disease.





PATIENT

Broccoli Holub

SPECIES

Canine

BREED

Mix

SEX

Neutered Male

AGE

3

WEIGHT

65

INTERPRETED BY

Eric Lindquist, DMV
DABVP, Cert. IVUSS

IMAGING PERFORMED BY

Christensen

HOSPITAL NAME

Tranquility VC

REFERRING VET

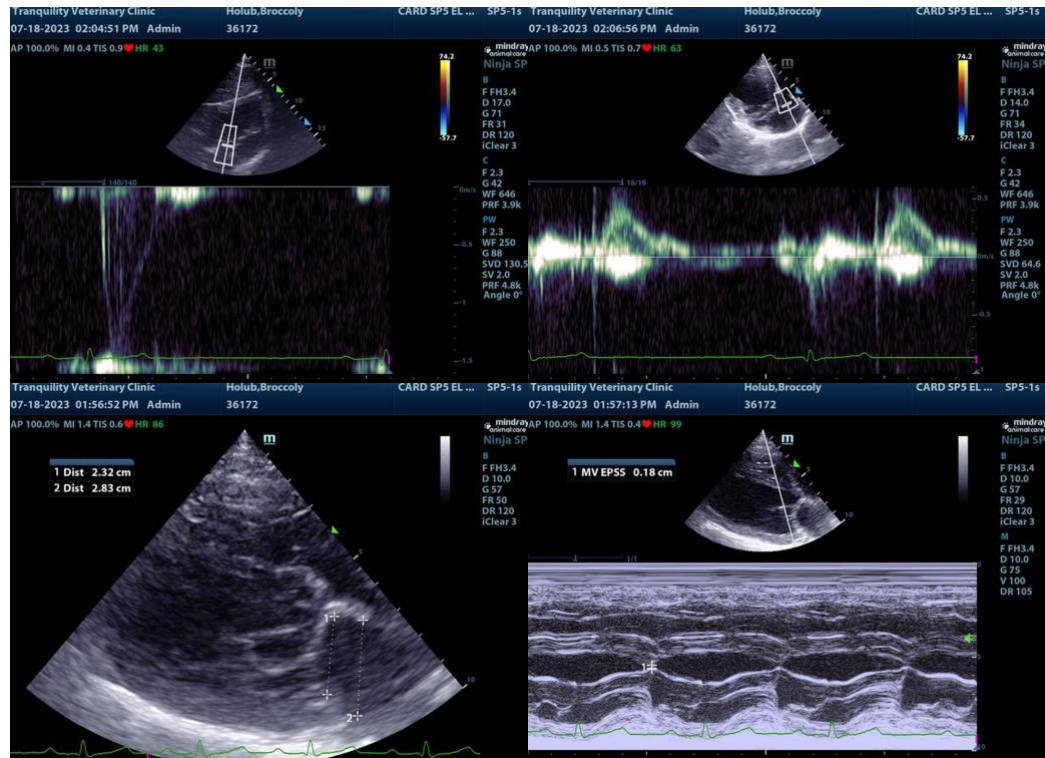
House

INVOICE

23466

DATE

7/18/23



The information and recommendations provided are based on the images presented by the referring veterinarian. No evaluation can be communicated regarding pathology that was not visible in the image/video clips provided.

Thank you for this referral. If the clinical or image interpretation does not parallel your findings or if I can be of any further assistance please contact me.

Eric Lindquist, DMV, DABVP, Cert. IVUSS, CEO of SonoPath.com
info@SonoPath.com