



PATIENT

Benji Jones

SPECIES

Canine

BREED

Rottweiler

SEX

Male

AGE

2

WEIGHT

83

INTERPRETED BY

Eric Lindquist, DMV

DABVP, Cert. IVUSS

IMAGING PERFORMED BY

Jenn

HOSPITAL NAME

Rockaway AH

REFERRING VET

Dr. Maniar

INVOICE

23439

DATE

7/18/23

PRESENTING CLINICAL SIGNS

Chronic intermittent diarrhea getting neutered tomorrow Hx of Addison's and chronic fb consumption

ULTRASONOGRAPHIC EXAMINATION OF THE ABDOMEN

Urinary System

The **urinary bladder** and visible pelvic urethra were unremarkable for the level of repletion presented. The urine, however, did present some mildly echogenic debris consistent with mucous, exfoliated cells from renal or bladder origin, and/or blood clots as these echogenic changes can all present similarly. This is often related to urinary tract infection but may represent simple evidence of exfoliated debris or sterile inflammation. Cystocentesis, urinalysis, +/- culture would be recommended to rule out and define any UTI. This is a mild change. The pelvic urethra was imaged 2.0 cm beyond the cystourethral junction.

The **kidneys** revealed normal size and structure, corticomedullary definition and ratio for this age. The cortices presented largely uniform texture with normal echogenic relationship to liver and spleen. Medullary structure differed distinctly from the cortex and no evidence of pelvic dilation was present. The capsules were acceptably uniform without significant irregularities. The right kidney measured 6.7 cm. The left kidney measured 9.0 cm.

Adrenal Glands

The **left adrenal gland** was flattened and isoechoic, measuring 1.5 cm x 0.29 cm at the caudal pole and 0.34 cm at the cranial pole.

The **right adrenal gland** was visualized and recognized as having normal shape, size, position and echogenicity for this breed. The phrenic vasculature, glandular echogenicity and detail were unremarkable. Capsule, cortex, and medullary definition were normal for this age patient. The right adrenal gland measured 1.78 cm x 0.8 cm at the cranial pole and 0.52 cm at the caudal pole.

Spleen

The **spleen** presented a smooth homogeneous parenchyma hyperechoic to liver and renal cortical parenchyma. The capsule was smooth without noticeable expansion or deviation from within the spleen or adjacent pathology. The splenic vasculature demonstrated normal volume without signs of congestion or thrombosis. No sonographic evidence of acute or chronic inflammatory, neoplastic, or infarctual changes were noted.

Liver

The **liver** images submitted revealed subjectively normal liver size, contour, and structure. Parenchymal echogenicity was naturally coarse and hypoechoic to the spleen. Vascular and biliary tracts were of normal volume with no evidence of congestion. The gallbladder presented acceptably thin walls with primarily anechoic content. The cystic and common bile ducts were normal. No pathological hepatic lymphadenopathy was evident. No overt structural evidence of inflammatory, infiltrative or regenerative pathology was evident.

Gastrointestinal



PATIENT

Benji Jones

SPECIES

Canine

BREED

Rottweiler

SEX

Male

AGE

2

WEIGHT

83

INTERPRETED BY

Eric Lindquist, DMV

DABVP, Cert. IVUSS

IMAGING PERFORMED BY

Jenn

HOSPITAL NAME

Rockaway AH

REFERRING VET

Dr. Maniar

INVOICE

23439

DATE

7/18/23

There was some residual chyme and gas was noted in the **stomach**, yet not pathological. This is consistent with end post prandial presentation. Transit of chyme into the small intestine was normal. Curvilinear patterns were maintained throughout the GI tract. No evidence of pathology. Small and large intestine demonstrated normal luminal chyme and stool consistency respectively. No obstructive or overt infiltrative disease was noted. No associated abnormal lymphatic activity was noted.

Pancreas

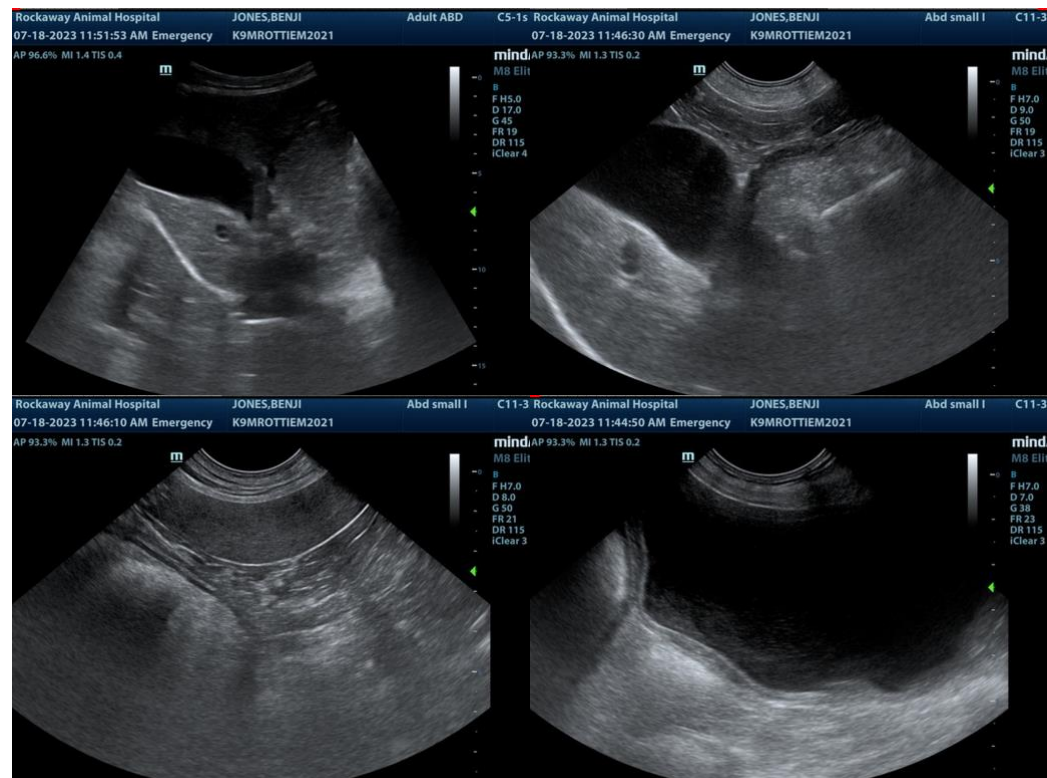
The base and limbs of the **pancreas** were observed to be largely isoechoic to surrounding omental fat. Pancreatic duct and capsular contour were acceptably normal and parenchyma respected normal curvilinear patterns. No overt evidence of active inflammatory or neoplastic disease was noted.

ULTRASONOGRAPHIC FINDINGS

- Flattened left adrenal gland.
- Urinary bladder debris
- Full stomach- post prandial presentation

INTERPRETATION OF THE FINDINGS & FURTHER RECOMMENDATIONS

No evidence of pathology. If foreign body consumption is suspected, then recheck sonogram at complete NPO status is indicated. No contraindication to anesthetic procedure, other than the Addisonian state.





PATIENT

Benji Jones

SPECIES

Canine

BREED

Rottweiler

SEX

Male

AGE

2

WEIGHT

83

INTERPRETED BY

Eric Lindquist, DMV

DABVP, Cert. IVUSS

IMAGING PERFORMED BY

Jenn

HOSPITAL NAME

Rockaway AH

REFERRING VET

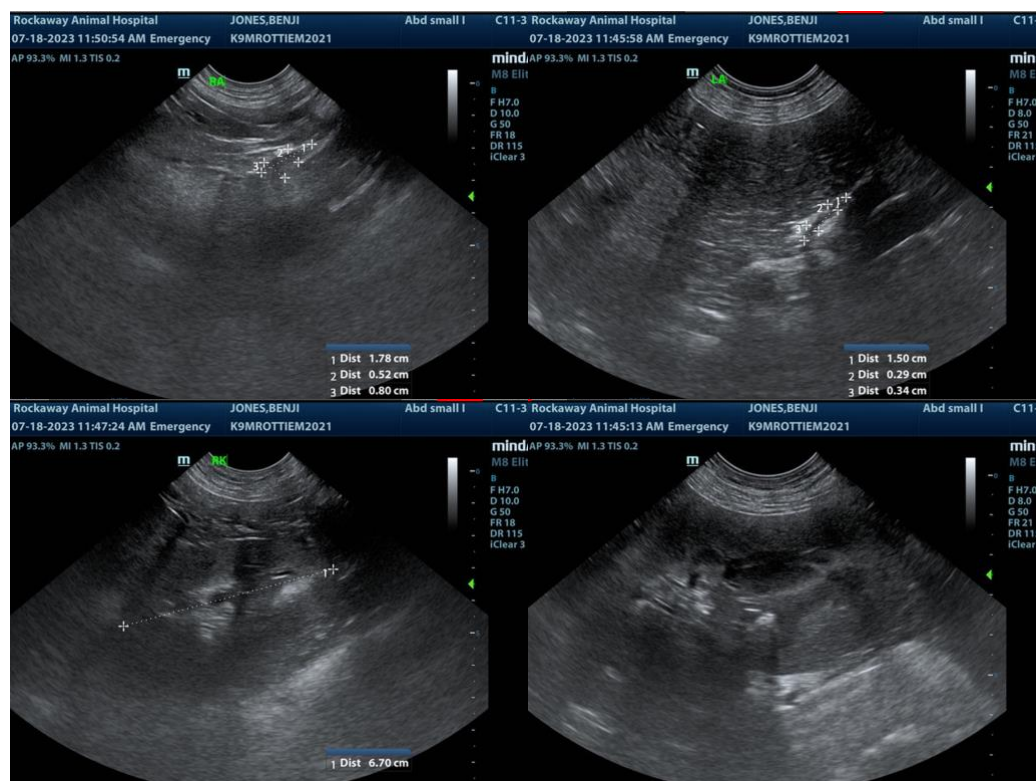
Dr. Maniar

INVOICE

23439

DATE

7/18/23



The information and recommendations provided are based on the images presented by the referring veterinarian/sonographer. No evaluation can be communicated regarding pathology that was not visible in the image/video clips provided.

Thank you for this referral. If the clinical or image interpretation does not parallel your findings or if I can be of any further assistance please contact me.

Eric Lindquist, DMV, DABVP, Cert. IVUSS, CEO of SonoPath.com

info@SonoPath.com