



PATIENT PRESENTING CLINICAL SIGNS

Vegas Borg re check prev u/s 7/14

SPECIES ULTRASONOGRAPHIC EXAMINATION OF THE ABDOMEN

Feline **Urinary System**

The **urinary bladder**, trigone, and pelvic urethra presented normal thicknesses and normal tone. The ureters were not visible which is normal. No uroliths or sediment were visualized and anechoic urine was present. No evidence of inflammatory or neoplastic changes were noted. Ureteral papillae were normal.

BREED

DSH

SEX

Female

The **kidneys** revealed normal size and structure, corticomedullary definition and ratio for this age. The cortices presented largely uniform texture with normal echogenic relationship to liver and spleen. Medullary structure differed distinctly from the cortex and no evidence of pelvic dilation was present. The capsules were acceptably uniform without significant irregularities. The right kidney measured 3.67 cm. The left kidney measured 4.08 cm.

AGE

7 Years

Adrenal Glands

The regions of the **adrenal glands** were unremarkable.

Spleen

WEIGHT

7.4 Pounds

The **spleen** presented a smooth homogeneous parenchyma hyperechoic to liver and renal cortical parenchyma. The capsule was smooth without noticeable expansion or deviation from within the spleen or adjacent pathology. The splenic vasculature demonstrated normal volume without signs of congestion or thrombosis. No sonographic evidence of acute or chronic inflammatory, neoplastic, or infarctual changes were noted.

INTERPRETED BY

Eric Lindquist, DMV

Liver

DABVP, Cert. IVUSS

The **liver** images submitted revealed subjectively normal liver size, contour, and structure. Parenchymal echogenicity was naturally coarse and hypoechoic to the spleen. Vascular and biliary tracts were of normal volume with no evidence of congestion. The gallbladder presented acceptably thin walls with primarily anechoic content. The cystic and common bile ducts were normal. No pathological hepatic lymphadenopathy was evident. No overt structural evidence of inflammatory, infiltrative or regenerative pathology was evident.

IMAGING PERFORMED BY

Jenn

HOSPITAL NAME

Rockaway AH

Gastrointestinal

Examination of the **gastrointestinal tract** revealed a stomach and intestine free of stasis, of normal wall thickness, acceptable curvilinear mural detail, and peristaltic activity. Small and large intestine demonstrated normal luminal chyme and stool consistency respectively. No obstructive or overt infiltrative disease was noted. No associated abnormal lymphatic activity was noted.

REFERRING VET

Dr. Maniar

Pancreas

INVOICE

39624

The **pancreas** was hypoechoic at the base in a region of approximately 1.5 cm of irregular tissue, suggestive for inflammation. Slightly enhanced surrounding mesentery noted.

PRIMARY FINDINGS

DATE

7/18/22

- Possible low-grade pancreatitis, unremarkable abdomen otherwise



PATIENT

Vegas Borg

INTERPRETATION OF THE FINDINGS & FURTHER RECOMMENDATIONS

Therapy should be based on residual clinical signs.

SPECIES

Feline

BREED

DSH

SEX

Female

AGE

7 Years

WEIGHT

7.4 Pounds

INTERPRETED BY

Eric Lindquist, DMV

DABVP, Cert. IVUSS

IMAGING PERFORMED BY

Jenn

HOSPITAL NAME

Rockaway AH

REFERRING VET

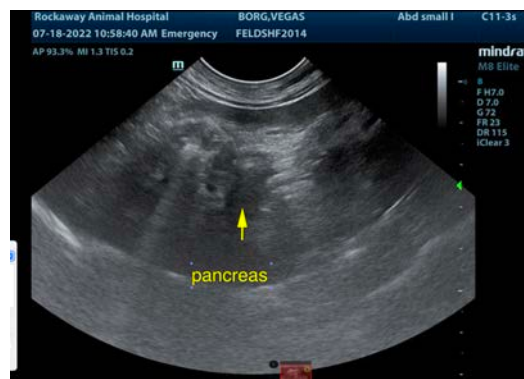
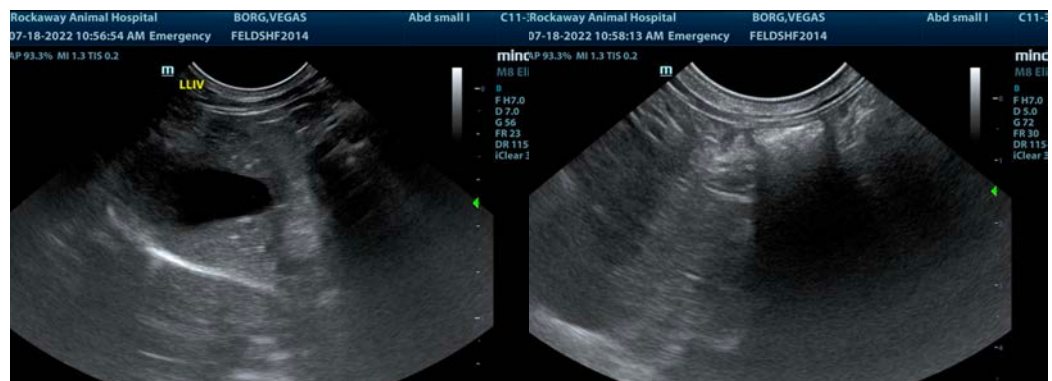
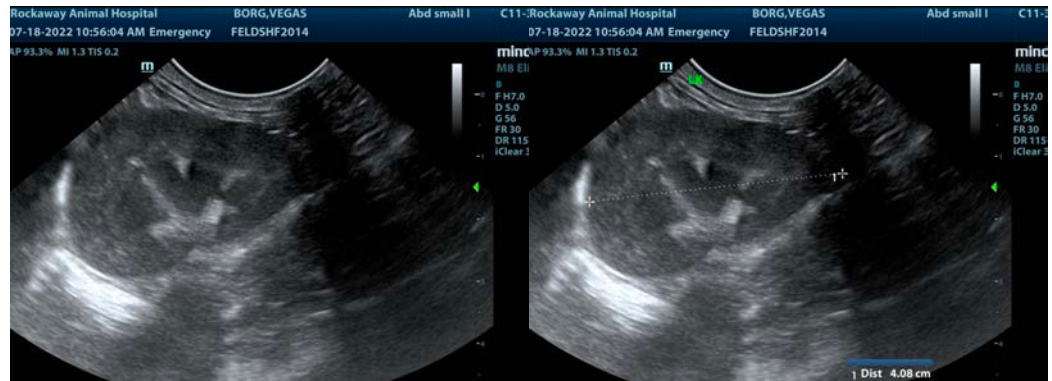
Dr. Maniar

INVOICE

39624

DATE

7/18/22



The information and recommendations provided are based on the images presented by the referring veterinarian/sonographer. No evaluation can be communicated regarding pathology that was not visible in the image/video clips provided.

Thank you for this referral. If the clinical or image interpretation does not parallel your findings or if I can be of any further assistance please contact me.

Eric Lindquist, DMV, DABVP, Cert. IVUSS, CEO of SonoPath.com

info@SonoPath.com