



PATIENT

Sophie Battista

SPECIES

Canine

BREED

Pomeranian

SEX

Spayed Female

AGE

13 Years

WEIGHT

15 Pounds

INTERPRETED BY

Eric Lindquist, DMV
DABVP, Cert. IVUSS

IMAGING PERFORMED BY

Eric Lindquist, DMV
DABVP, Cert. IVUSS

HOSPITAL NAME

Franklin Lakes AH

REFERRING VET

Dr. Pomerantz

INVOICE

16703

DATE

7/18/22

PRESENTING CLINICAL SIGNS

History: Recheck heart failure. First scan 6/29/22

Current meds: Triple tx, spironolactone

Abnormal CBC/Chem Findings: Pending

ULTRASONOGRAPHIC EXAMINATION OF THE HEART

CANINE CARDIAC PARAMETERS	MR VMAX (m/s)	TR VMAX (m/s)	LA/AO (Boon method)	LA/AO (Heart Base; Swe)	FS (%)	EF (%)	EPSS (cm)
NORMAL PARAMETER	4.5-5.5	<2.7	1.3	<1.3	28-40	40-100	<0.6
PATIENT	6.50	2.67	1.3	1.5	64	94	NM
CANINE CARDIAC PARAMETERS	HR (BPM)	AV VMAX (m/s)	PV MAX (m/s)	BODY WEIGHT (kg)	LA 2D short axis Base view (cm)	LVIDd Avg; 2D and m-mode short axis (cm)	LVIDs Avg; 2D and m-mode short axis (cm)
NORMAL PARAMETER	50-100	0.7-1.7	0.7-1.6				
PATIENT	155	--	.89	--	2.87	2.64	--

Cardiac Presentation

The cardiac presentation is significantly improved compared to the prior sonogram. Left atrial size was borderline to mildly enlarged. Contractility and left ventricular internal diameter were adequate. Mitral and tricuspid insufficiency were present. The pulmonary hypertension noted at the prior echocardiogram has reduced into an acceptable range to minor. The right atrium, right ventricle and pericardium were all unremarkable.

ULTRASONOGRAPHIC FINDINGS

- Significantly improved valvular disease, compensated at this time on current quadra therapy of Pimobendan, Ace-inhibitor, spironolactone and Lasix

INTERPRETATION OF THE FINDINGS & FURTHER RECOMMENDATIONS

I recommended continuation of this protocol and increasing Ace-inhibitor to BID dosing with recheck echo in three months. Periodic evaluation of sleeping respiration rate, target <25 per minute. BUN and creatinine should be monitored as well as blood pressures and periodic chest radiographs.



PATIENT

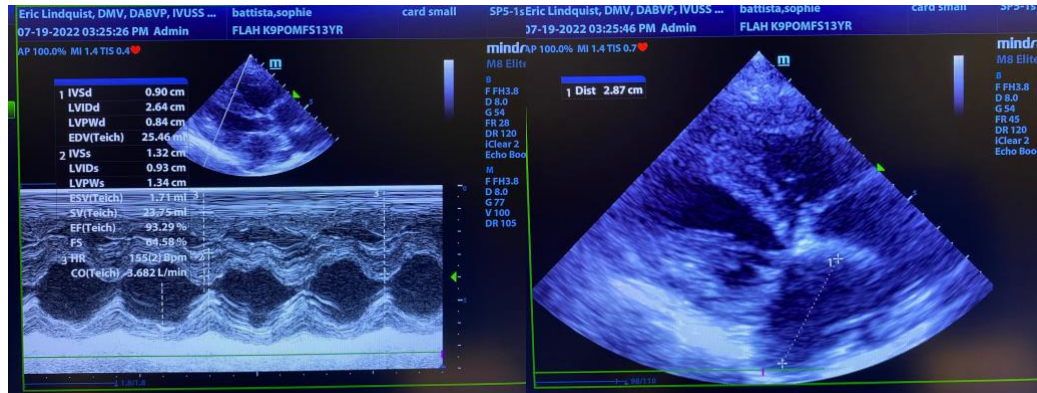
Sophie Battista

SPECIES

Canine

BREED

Pomeranian



SEX

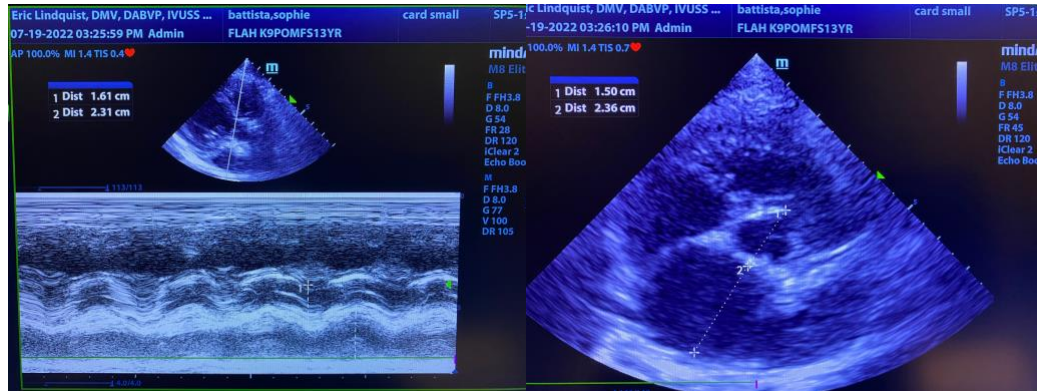
Spayed Female

AGE

13 Years

WEIGHT

15 Pounds

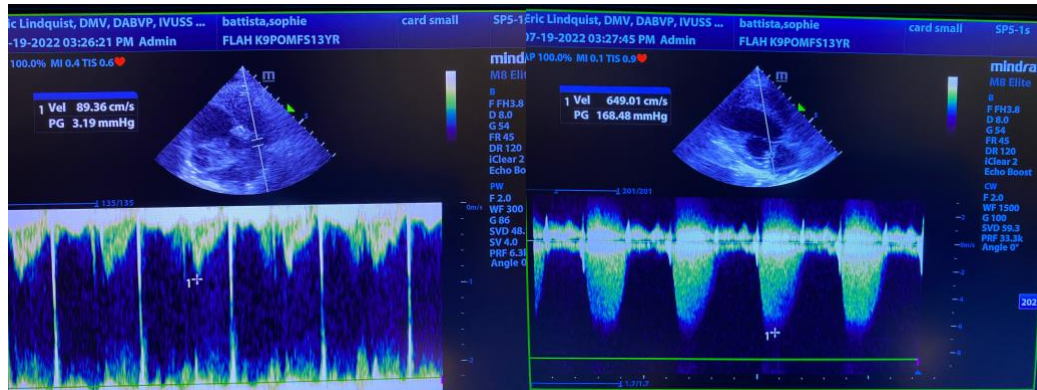


INTERPRETED BY

Eric Lindquist, DMV
DABVP, Cert. IVUSS

IMAGING PERFORMED BY

Eric Lindquist, DMV
DABVP, Cert. IVUSS



HOSPITAL NAME

Franklin Lakes AH

REFERRING VET

Dr. Pomerantz

INVOICE

16703

DATE

7/18/22

The information and recommendations provided are based on the images presented by the referring veterinarian. No evaluation can be communicated regarding pathology that was not visible in the image/video clips provided.

Thank you for this referral. If the clinical or image interpretation does not parallel your findings or if I can be of any further assistance please contact me.

Eric Lindquist, DMV, DABVP, Cert. IVUSS, CEO of SonoPath.com
info@SonoPath.com