



PATIENT

Annie Ferry

SPECIES

Canine

BREED

Cockapoo

SEX

Spayed Female

AGE

10

WEIGHT

12.9

INTERPRETED BY

Eric Lindquist, DMV

DABVP, Cert. IVUSS

IMAGING PERFORMED BY

Jenn

HOSPITAL NAME

Rockaway AH

REFERRING VET

Dr. Maniar

INVOICE

43891

DATE

7/17/23

PRESENTING CLINICAL SIGNS

Hx of diabetes anorexia.

ULTRASONOGRAPHIC EXAMINATION OF THE ABDOMEN

Urinary System

The **urinary bladder**, trigone, and pelvic urethra presented normal thicknesses and normal tone. The ureters were not visible which is normal. No uroliths or sediment were visualized and anechoic urine was present. No evidence of inflammatory or neoplastic changes were noted. Ureteral papillae were normal.

The **kidneys** revealed normal size and structure, corticomedullary definition and ratio for this age. The cortices presented largely uniform texture with normal echogenic relationship to liver and spleen. Medullary structure differed distinctly from the cortex and no evidence of pelvic dilation was present. The capsules were acceptably uniform without significant irregularities. The right kidney measured 4.3 cm. The left kidney measured 3.87 cm

Adrenal Glands

Both **adrenal glands** were visualized and recognized as having normal shape, size, position and echogenicity for this breed. The phrenic vasculature, glandular echogenicity and detail were unremarkable. Capsule, cortex, and medullary definition were normal for this age patient. The right adrenal gland measured 1.63 cm x 0.53 cm at the caudal pole and 0.70 cm at the cranial pole.

Spleen

The **spleen** revealed a hyperechoic lipogranulomatous type change. Other lipid plaques noted throughout the spleen.

Liver

The **liver** images from right and left intercostal as well as subcostal views revealed subjectively normal liver size, contour, and structure. Some age-related parenchymal remodeling was noted but likely not clinically significant at this time. Vascular and biliary tracts were of normal volume and no evidence of congestion was noted. The gallbladder presented some dependent debris with essentially normal contour. The cystic and common bile ducts were normal. No overt evidence of active inflammatory, infiltrative or regenerative pathology was noted but should be paired with current or past LE elevations regarding any clinical significance to this presentation. The hepatic lymph nodes were unremarkable.

Gastrointestinal

Examination of the **gastrointestinal tract** revealed a stomach and intestine free of stasis, of normal wall thickness, acceptable curvilinear mural detail, and peristaltic activity. Small and large intestine demonstrated normal luminal chyme and stool consistency respectively. No obstructive or overt infiltrative disease was noted. No associated abnormal lymphatic activity was noted.

Pancreas

The base and limbs of the **pancreas** were observed to be largely isoechoic to surrounding omental fat. Pancreatic duct and capsular contour were acceptably normal and parenchyma respected normal curvilinear patterns. No overt evidence of active inflammatory or neoplastic disease was noted.



PATIENT

Annie Ferry

SPECIES

Canine

BREED

Cockapoo

SEX

Spayed Female

AGE

10

WEIGHT

12.9

INTERPRETED BY

Eric Lindquist, DMV

DABVP, Cert. IVUSS

IMAGING PERFORMED BY

Jenn

HOSPITAL NAME

Rockaway AH

REFERRING VET

Dr. Maniar

INVOICE

43891

DATE

7/17/23

ULTRASONOGRAPHIC FINDINGS

- Structurally unremarkable abdomen with age related changes

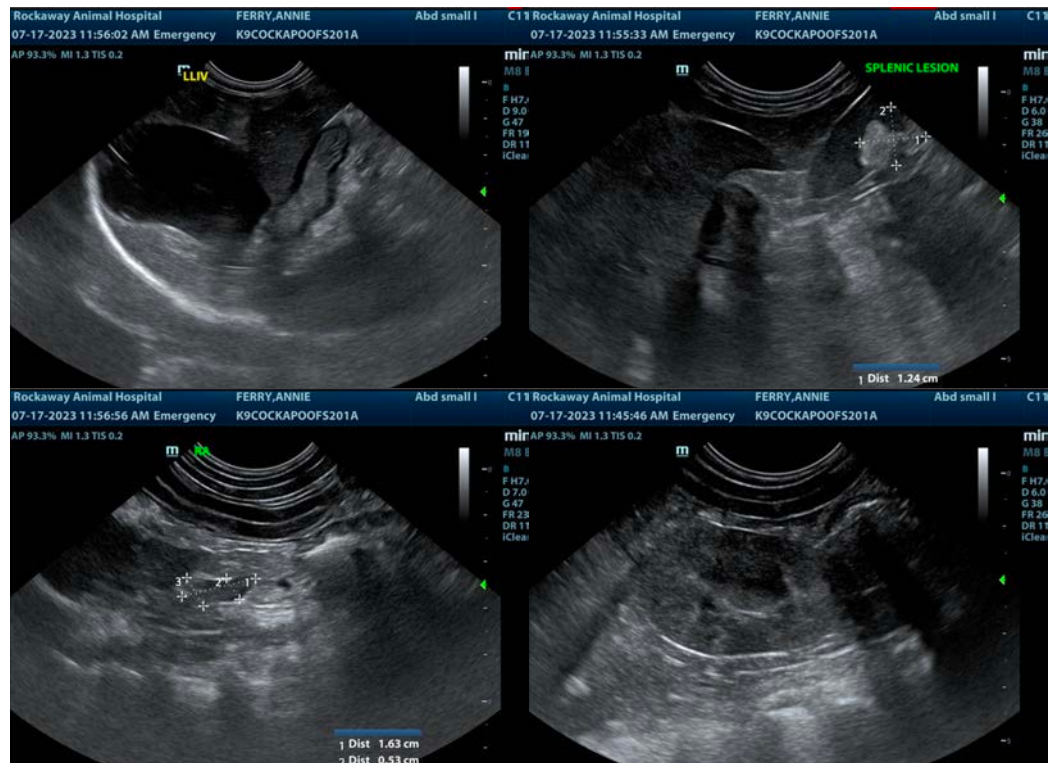
INTERPRETATION OF THE FINDINGS & FURTHER RECOMMENDATIONS

No evidence of direct cause of anorexia. Orthopedic pain, CNS or thoracic disease should be considered.

Potential Causes of Diabetic Dysregulation

This is a suggestive checkoff list when faced with an unregulated diabetic patient:

- UTI
- Dietary indiscretion/intolerance
- Pancreatitis
- Hyperthyroidism/hypothyroidism
- Exogenous steroids (including topical eye meds)
- Cushing's
- Acromegaly
- Owner compliance
- Insulin quality issues
- Antibodies to insulin
- Underlying Neoplasia
- Diffuse liver disease





PATIENT

Annie Ferry

The information and recommendations provided are based on the images presented by the referring veterinarian/sonographer. No evaluation can be communicated regarding pathology that was not visible in the image/video clips provided.

SPECIES

Canine

Thank you for this referral. If the clinical or image interpretation does not parallel your findings or if I can be of any further assistance please contact me.

BREED

Cockapoo

Eric Lindquist, DMV, DABVP, Cert. IVUSS, CEO of SonoPath.com

info@SonoPath.com

SEX

Spayed Female

AGE

10

WEIGHT

12.9

INTERPRETED BY

Eric Lindquist, DMV

DABVP, Cert. IVUSS

IMAGING PERFORMED BY

Jenn

HOSPITAL NAME

Rockaway AH

REFERRING VET

Dr. Maniar

INVOICE

43891

DATE

7/17/23