



PATIENT

Smokey Clifford

SPECIES

Feline

BREED

Persian

SEX

Neutered Male

AGE

8 Years

WEIGHT

10.94 Pounds

INTERPRETED BY

Eric Lindquist, DMV

DABVP, Cert. IVUSS

IMAGING PERFORMED BY

Dr. Saum Hadi

HOSPITAL NAME

Bethany Family PC

REFERRING VET

Dr. Saum Hadi

INVOICE

39614

DATE

7/17/22

PRESENTING CLINICAL SIGNS

P presented for a possible vaccine reaction on 6/6. An aFAST scan was performed and multifocal hyperechoic lesions were seen on the spleen. P doing great at home otherwise. History of HOCM, managed by a cardiologist. Chest rads clear of pulmonary metastasis.

Abnormal PE/Chem/CBC/UA Results: Chem 27, CBC, UA, T4 performed. NSF mostly... Creatinine 2.0 mg/dL, USG: 1.050.

ULTRASONOGRAPHIC EXAMINATION OF THE ABDOMEN

Urinary System

The **urinary bladder**, trigone, and pelvic urethra presented normal thicknesses and normal tone. The ureters were not visible which is normal. No uroliths or sediment were visualized and anechoic urine was present. No evidence of inflammatory or neoplastic changes were noted. Ureteral papillae were normal.

The **kidneys** revealed normal size and structure, corticomedullary definition and ratio for this age. The cortices presented largely uniform texture with normal echogenic relationship to liver and spleen. Medullary structure differed distinctly from the cortex and no evidence of pelvic dilation was present. The capsules were acceptably uniform without significant irregularities. The left kidney measured 4.0 cm. The right kidney measured 4.0 cm.

Adrenal Glands

The regions of the **adrenal glands** were unremarkable.

Spleen

The **spleen** presented multifocal hyperechoic lipogranulomatous type changes with slight scalloping contour. Likely benign. However, FNA could be considered for further definition.

Liver

The **liver** images submitted revealed subjectively normal liver size, contour, and structure. Parenchymal echogenicity was naturally coarse and hypoechoic to the spleen. Vascular and biliary tracts were of normal volume with no evidence of congestion. The gallbladder presented acceptably thin walls with primarily anechoic content. The cystic and common bile ducts were normal. No pathological hepatic lymphadenopathy was evident. No overt structural evidence of inflammatory, infiltrative or regenerative pathology was evident.

Gastrointestinal

The **gastrointestinal** presentation revealed mild uniform prominence of the gastric mucosa as well as areas of "ropey" small intestinal wall with slight disruption of the normal 1:3 muscularis/mucosal ratio. The intestinal submucosa was slightly irregular, thickened and hyperechoic suggestive of low grade, chronic disease. No concerning lymphadenopathy was visible. No evidence of obstruction was present. Chronic inflammatory bowel disease is likely with a low possibility of an early neoplastic event such as lymphoma. Full thickness tissue biopsies via open laparotomy, ideally guided by intraoperative ultrasound in order to obtain the most representative mural sample, would be necessary to rule out this possibility.



PATIENT

Smokey Clifford

Pancreas

The base and limbs of the **pancreas** were observed to be largely isoechoic to surrounding omental fat. Pancreatic duct and capsular contour were acceptably normal and parenchyma respected normal curvilinear patterns. No overt evidence of active inflammatory or neoplastic disease was noted.

SPECIES

Feline

ULTRASONOGRAPHIC FINDINGS

- Diffuse intestinal thickening
- Lipogranulomatous type splenic deposits with mild splenic fold and scalloping contour

BREED

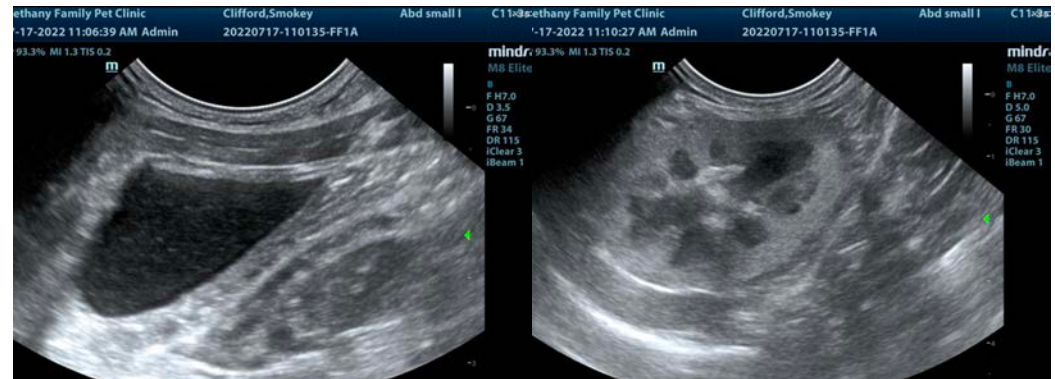
Persian

INTERPRETATION OF THE FINDINGS & FURTHER RECOMMENDATIONS

No evidence of significant disease other than intestinal thickening. FNA of the spleen could be considered for further definition, yet likely benign.

SEX

Neutered Male



AGE

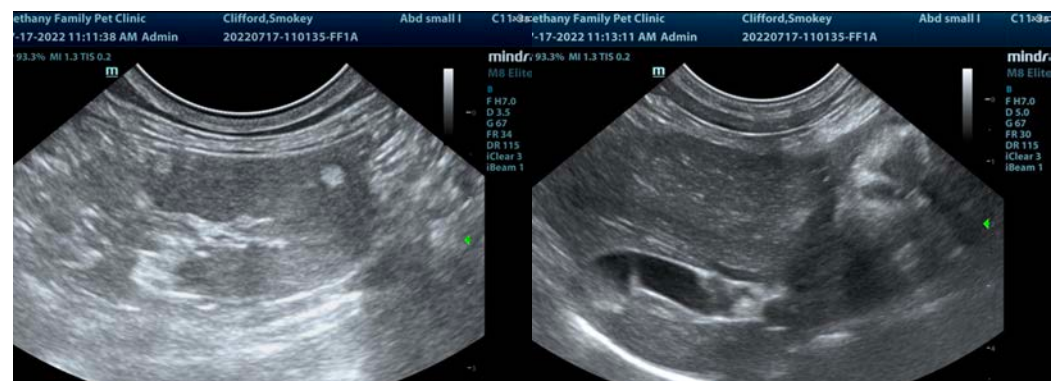
8 Years

WEIGHT

10.94 Pounds

INTERPRETED BY

Eric Lindquist, DMV



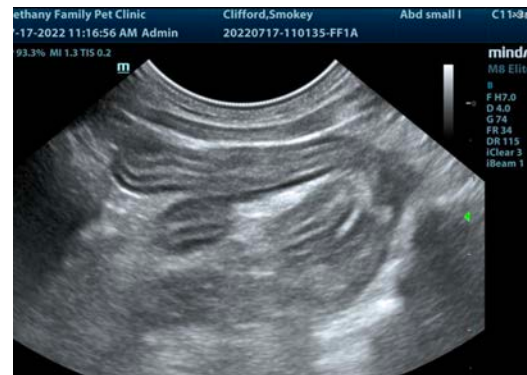DABVP, Cert. IVUSS

IMAGING PERFORMED BY

Dr. Saum Hadi

HOSPITAL NAME

Bethany Family PC



REFERRING VET

Dr. Saum Hadi

INVOICE

39614

DATE

7/17/22



PATIENT

Smokey Clifford

The information and recommendations provided are based on the images presented by the referring veterinarian/sonographer. No evaluation can be communicated regarding pathology that was not visible in the image/video clips provided.

SPECIES

Feline

Thank you for this referral. If the clinical or image interpretation does not parallel your findings or if I can be of any further assistance please contact me.

Eric Lindquist, DMV, DABVP, Cert. IVUSS, CEO of SonoPath.com

info@SonoPath.com

BREED

Persian

SEX

Neutered Male

AGE

8 Years

WEIGHT

10.94 Pounds

INTERPRETED BY

Eric Lindquist, DMV

DABVP, Cert. IVUSS

IMAGING PERFORMED BY

Dr. Saum Hadi

HOSPITAL NAME

Bethany Family PC

REFERRING VET

Dr. Saum Hadi

INVOICE

39614

DATE

7/17/22