



PATIENT

Rain Prestipino

SPECIES

Canine

BREED

Yorkshire Terrier

SEX

Neutered Male

AGE

10 Years

WEIGHT

14.4 Pounds

INTERPRETED BY

Eric Lindquist, DMV

DABVP, Cert. IVUSS

IMAGING PERFORMED BY

Dr. Travis Cerf

HOSPITAL NAME

Veterinary Center of
Hardyston

REFERRING VET

Dr. Travis Cerf

PRESENTING CLINICAL SIGNS

P presented for Annual visit 6/21/2022. P was coughing, was put on Hycodan (1/4 tablet orally every 8-12 hours as needed for cough). Cough got slightly better on Hycodan. DR suggested abdomen ultrasound due to hepatomegaly.

Abnormal PE/Chem/CBC/UA Results: Phosphorus: 6.5mg/dl Chloride: 105mmol/L ALP: 889 U/L Cholesterol: 35mg/dl Creatine Kinase: 264U/L

ULTRASONOGRAPHIC EXAMINATION OF THE ABDOMEN

Urinary System

The **urinary bladder**, trigone, and pelvic urethra presented normal thicknesses and normal tone. The ureters were not visible which is normal. No uroliths or sediment were visualized and anechoic urine was present. No evidence of inflammatory or neoplastic changes were noted. Ureteral papillae were normal.

The **kidneys** revealed normal size and structure, corticomedullary definition and ratio for this age. The cortices presented largely uniform texture with normal echogenic relationship to liver and spleen. Medullary structure differed distinctly from the cortex. The capsules were acceptably uniform without significant irregularities. Trace pyelectasia noted. The left kidney measured 4.6 cm. The right kidney measured 4.6 cm.

Adrenal Glands

Both **adrenal glands** were visualized and recognized as having normal shape, size, position and echogenicity for this breed. The phrenic vasculature, glandular echogenicity and detail were unremarkable. Capsule, cortex, and medullary definition were normal for this age patient. The left adrenal gland measured 0.50 cm. The right adrenal gland measured 0.5 cm.

Spleen

The **spleen** presented a smooth homogeneous parenchyma hyperechoic to liver and renal cortical parenchyma. The capsule was smooth without noticeable expansion or deviation from within the spleen or adjacent pathology. The splenic vasculature demonstrated normal volume without signs of congestion or thrombosis. No sonographic evidence of acute or chronic inflammatory, neoplastic, or infarctual changes were noted.

Liver

The **liver** images submitted revealed subjectively normal liver size, contour, and structure. Parenchymal echogenicity was naturally coarse and hypoechoic to the spleen. Vascular and biliary tracts were of normal volume with no evidence of congestion. The gallbladder presented acceptably thin walls with primarily anechoic content. The cystic and common bile ducts were normal. No pathological hepatic lymphadenopathy was evident. No overt structural evidence of inflammatory, infiltrative or regenerative pathology was evident.

Gastrointestinal

Examination of the **gastrointestinal tract** revealed a stomach and intestine free of stasis, of normal wall thickness, acceptable curvilinear mural detail, and peristaltic activity. Small and large intestine demonstrated normal luminal chyme and stool consistency respectively. No obstructive or overt infiltrative disease was noted. No associated abnormal lymphatic activity was noted.

INVOICE

39601

DATE

7/16/22



PATIENT

Pancreas

Rain Prestipino

The base and limbs of the **pancreas** were observed to be largely isoechoic to surrounding omental fat. Pancreatic duct and capsular contour were acceptably normal and parenchyma respected normal curvilinear patterns. No overt evidence of active inflammatory or neoplastic disease was noted.

SPECIES

Canine

ULTRASONOGRAPHIC FINDINGS

- Structurally unremarkable abdomen

BREED

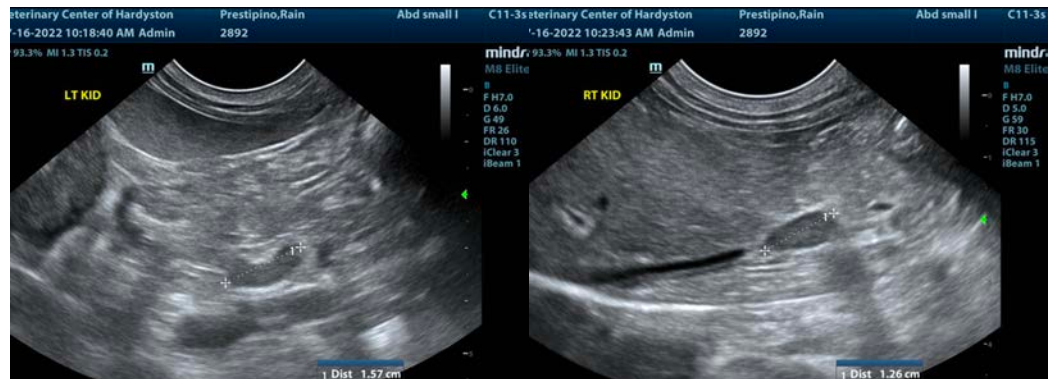
Yorkshire Terrier

INTERPRETATION OF THE FINDINGS & FURTHER RECOMMENDATIONS

No evidence of pathology.

SEX

Neutered Male



AGE

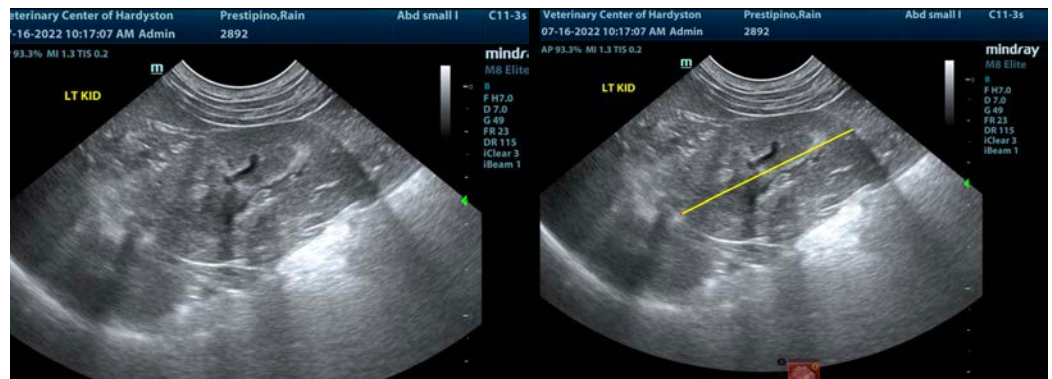
10 Years

WEIGHT

14.4 Pounds

INTERPRETED BY

Eric Lindquist, DMV
DABVP, Cert. IVUSS

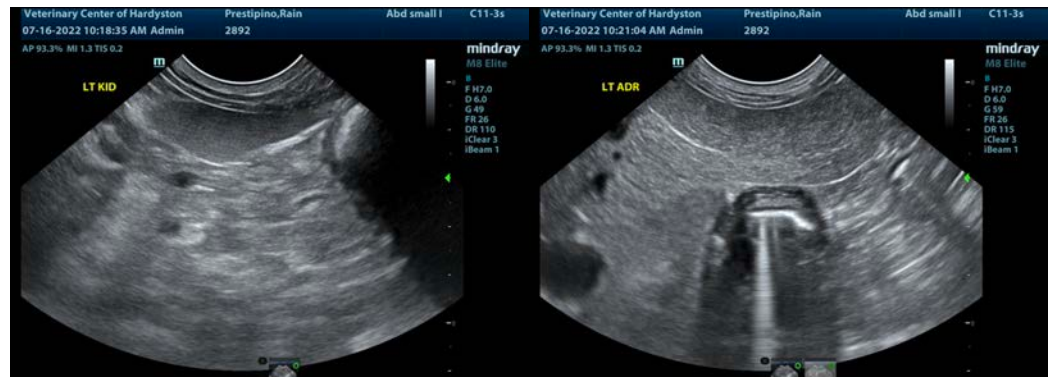


IMAGING PERFORMED BY

Dr. Travis Cerf

HOSPITAL NAME

Veterinary Center of Hardyston



REFERRING VET

Dr. Travis Cerf

INVOICE

39601

DATE

7/16/22



PATIENT

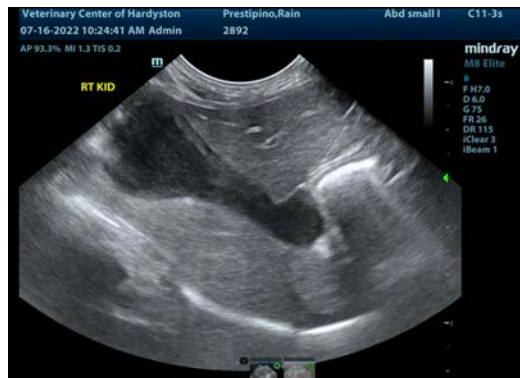Rain Prestipino

SPECIES

Canine

BREED

Yorkshire Terrier



SEX

Neutered Male

AGE

10 Years

WEIGHT

14.4 Pounds

INTERPRETED BY

Eric Lindquist, DMV

DABVP, Cert. IVUSS

IMAGING PERFORMED BY

Dr. Travis Cerf

HOSPITAL NAME

Veterinary Center of
Hardyston

REFERRING VET

Dr. Travis Cerf

INVOICE

39601

DATE

7/16/22

The information and recommendations provided are based on the images presented by the referring veterinarian/sonographer. No evaluation can be communicated regarding pathology that was not visible in the image/video clips provided.

Thank you for this referral. If the clinical or image interpretation does not parallel your findings or if I can be of any further assistance please contact me.

Eric Lindquist, DMV, DABVP, Cert. IVUSS, CEO of SonoPath.com

info@SonoPath.com