



PATIENT PRESENTING CLINICAL SIGNS

Tank Beals History: Tachycardia Chronic allergies, on apoquel

SPECIES Abnormal PE/Chem/CBC/UA Results: 186, rr 60 Blood Pressure Measurements None Current Medications
Apoquel 16 mg 1.5 Sid and furosemide 40 mg bid

Canine

ULTRASONOGRAPHIC EXAMINATION OF THE HEART

BREED

Lab Mix

SEX

Neutered Male

AGE

16 Years

WEIGHT

80.8 Pounds

CANINE CARDIAC PARAMETERS	MR VMAX (m/s)	TR VMAX (m/s)	LA/AO (Boon method)	LA/AO (Heart Base; Swe)	FS (%)	EF (%)	EPSS (cm)
NORMAL PARAMETER	4.5-5.5	<2.7	1.3	<1.3	28-40	40-100	<0.6
PATIENT	5.0	1.5	2.07	2.9	18	--	0.93
CANINE CARDIAC PARAMETERS	HR (BPM)	AV VMAX (m/s)	PV MAX (m/s)	BODY WEIGHT (kg)	LA 2D short axis Base view (cm)	LVIDd Avg; 2D and m-mode short axis (cm)	LVIDs Avg; 2D and m-mode short axis (cm)
NORMAL PARAMETER	50-100	0.7-1.7	0.7-1.6				
PATIENT	130	--	.64	--	7.67	7.2	--

INTERPRETED BY

Eric Lindquist, DMV
DABVP, Cert. IVUSS

IMAGING PERFORMED BY

Sara Hansen

HOSPITAL NAME

Countryside VS

REFERRING VET

Dr. Eichmann

INVOICE

16646

DATE

7/15/22

Cardiac Presentation

The cardiac presentation in this patient presented severe volume overload of the left atrium and left ventricle with poor contractility. Tricuspid insufficiency was noted. Centralized moderate mitral insufficiency was present. No pleural effusion noted. A comet tail lung pattern and B-lines were noted, consistent with pulmonary edema. Pulmonary edema lines were noted. Trace pericardial effusion was present. Hepatic veins were dilated, as was the vena cava, consistent with passive congestion and right sided failure.

ULTRASONOGRAPHIC FINDINGS

- Dilatative cardiomyopathy
- Left and right sided heart failure

INTERPRETATION OF THE FINDINGS & FURTHER RECOMMENDATIONS

Possible underlying nutritional cardiomyopathy or myocarditis. I recommend quadra therapy in this patient, Pimobendan at 0.3 mg/kg BID, Ace-inhibitor at 0.5 mg/kg SID, progressing to BID, Lasix at 3-4 mg/kg BID and Spironolactone at 1-2 mg/kg BID. Recheck echocardiogram in 10-14 days, recheck BUN and creatinine in 5-7 days. Urine specific gravity, chest radiographs and sleeping respiratory rate should be monitored. SRR <25-30 p/m. Taurine levels should also be evaluated and assessment for regional causes for myocarditis. Assessment for grain free diet issues is also warranted. Thyroid



PATIENT

assessment is also warranted to assess if hypothyroidism is playing a contributing role to the presentation.

Tank Beals

SPECIES

Canine

BREED

Lab Mix

SEX

Neutered Male

AGE

16 Years

WEIGHT

80.8 Pounds

INTERPRETED BY

Eric Lindquist, DMV
DABVP, Cert. IVUSS

IMAGING PERFORMED BY

Sara Hansen

HOSPITAL NAME

Countryside VS

REFERRING VET

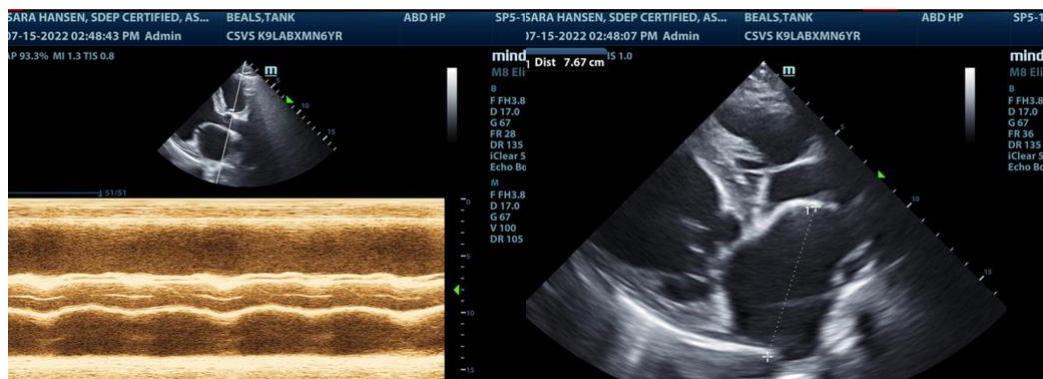
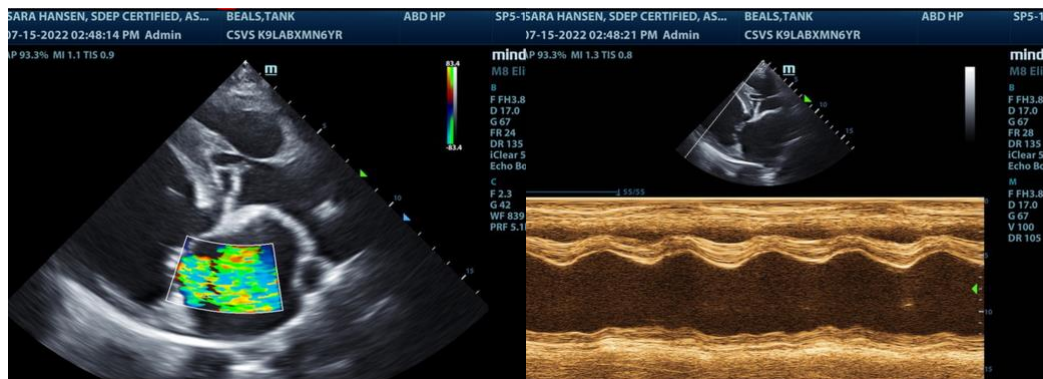
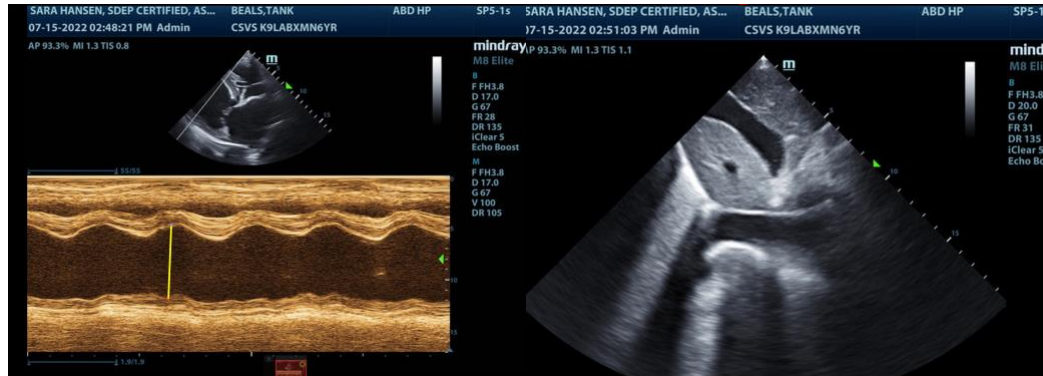
Dr. Eichmann

INVOICE

16646

DATE

7/15/22





PATIENT

Tank Beals

SPECIES

Canine

BREED

Lab Mix

SEX

Neutered Male

AGE

16 Years

WEIGHT

80.8 Pounds

INTERPRETED BY

Eric Lindquist, DMV
DABVP, Cert. IVUSS

IMAGING PERFORMED BY

Sara Hansen

HOSPITAL NAME

Countryside VS

REFERRING VET

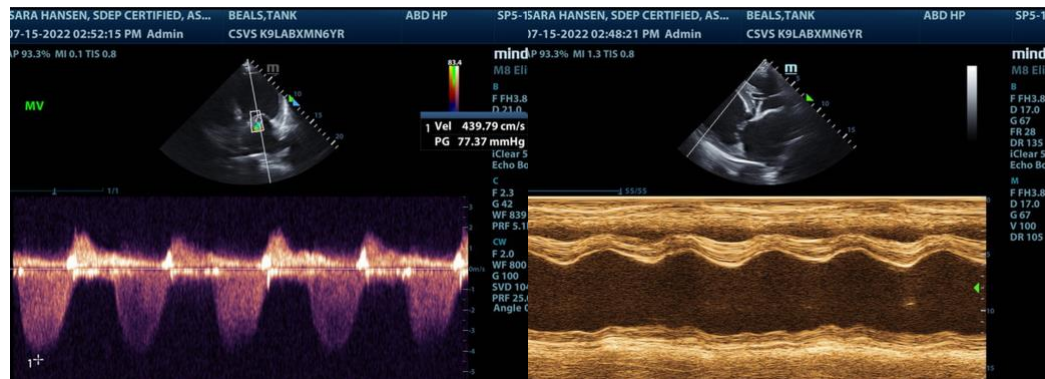
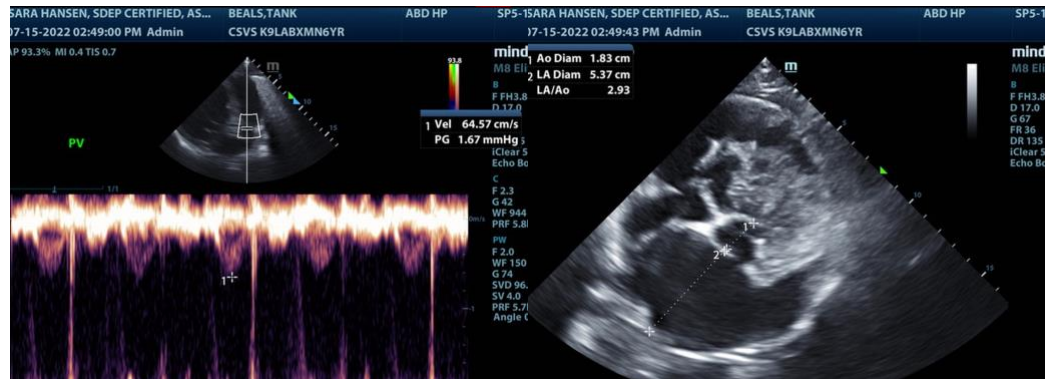
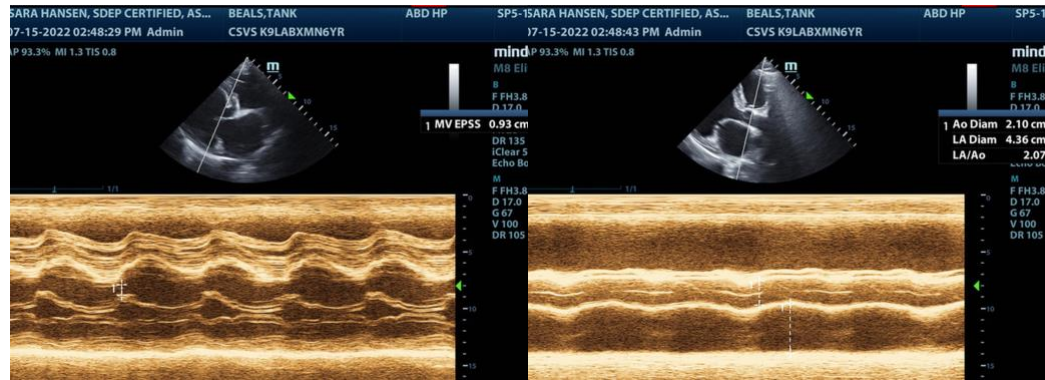
Dr. Eichmann

INVOICE

16646

DATE

7/15/22



The information and recommendations provided are based on the images presented by the referring veterinarian. No evaluation can be communicated regarding pathology that was not visible in the image/video clips provided.

Thank you for this referral. If the clinical or image interpretation does not parallel your findings or if I can be of any further assistance please contact me.

Eric Lindquist, DMV, DABVP, Cert. IVUSS, CEO of SonoPath.com
info@SonoPath.com

Canine Dilated Cardiomyopathy



PATIENT

<http://www.sonopath.com/DilatedCMY>

Tank Beals

SPECIES

Canine

BREED

Lab Mix

SEX

Neutered Male

AGE

16 Years

WEIGHT

80.8 Pounds

Description: Dilated cardiomyopathy (DCM) is the most significant acquired cardiac disease of large to giant breed dogs; it especially affects Doberman Pinschers, Great Danes, and Labrador Retrievers. DCM is primarily a systolic dysfunction caused by a progressive decrease in myocardial contractility. As contractility worsens, all chambers of the heart progressively dilate and the walls become increasingly stiff as intracardiac pressure rises. The net result is reduced cardiac output, which causes a decrease in muscle perfusion. As the disease progresses, the left ventricle continues to dilate, causing the mitral valve annulus to widen; cardiac output is further reduced as a result of mitral regurgitation. The reduced cardiac output stimulates the sympathetic nervous system to increase preload (diastolic volume), heart rate, and peripheral vascular resistance. Consequently, there is an increase in volume and pressure, and clinically, it is at this stage of the disease that most animals develop pulmonary edema.

Although the most common etiology is idiopathic, it can also be the result of hypothyroidism, taurine deficiency, L-carnitine deficiency, parvovirus, Lyme disease, and possibly myocarditis. In Doberman Pinschers there is some evidence that there may be a causative genetic mutation. Doxorubicin chemotherapy may induce a DCM-type presentation due to its myocardial toxicity. In Boxers, it is possible for primary myocarditis to precipitate DCM in the later stages of the condition. Hypothyroidism may also be a complicating factor in DCM as it has the potential to further aggravate the systolic dysfunction.

INTERPRETED BY

Eric Lindquist, DMV
DABVP, Cert. IVUSS

Clinical signs: Clinical signs include weakness, lethargy, exercise intolerance, coughing, anorexia, ascites, syncope, tachypnea, and dyspnea. Pulses are weak and rapid, and often there are pulse deficits. Pulmonary crackles may be auscultated. Jugular distention and muffled heart sounds may also be present.

IMAGING PERFORMED BY

Sara Hansen

Diagnostics: It is possible that NT-proBNP testing will be utilized in the future to detect occult DCM. One recent study showed that NT-proBNP levels were higher in dogs with DCM as well as apparently healthy patients that went on to develop DCM within 1.5 years of the samples being obtained.

HOSPITAL NAME

Countryside VS

The echocardiographic parameters for diagnosing DCM include an increased left ventricular (LV) diameter, depressed fractional shortening, and increased EPSS (> 0.8 cm); there is the possibility of an enlarged left atrium. A recent study showed that the best discriminating value for differentiating healthy Doberman Pinschers from those with DCM was the LV diastolic diameter (> 48mm for male dogs and > 46 mm for female dogs).

REFERRING VET

Dr. Eichmann

INVOICE

16646

Ideally, an ECG should be performed with a Holter monitor over a 24-hour period. Fifty to 100 VPCs are considered diagnostic for DCM in Doberman Pinschers when other systemic causes for arrhythmias have been excluded. The absence of detectable VPCs in the 5-minute ECG, however, should not lead to the assumption that the dog is healthy. Even one VPC in a 5-minute ECG strongly warrants further examination.

DATE

7/15/22



PATIENT

Tank Beals

When congestive heart failure (CHF) develops, patients will exhibit an increased respiratory rate and there will be evidence of pulmonary edema on survey radiographs. One might also note elevated NT-proBNP levels.

SPECIES

Canine

Treatment: Pimobendan (0.25-0.3 mg/kg PO BID) is a phosphodiesterase inhibitor and positive inotropic medication. (Note: The latter is a more powerful positive inotrope than digoxin.) Studies have shown that pimobendan significantly prolongs survivability in Dobermans with DCM and CHF; their mean survival time was 329 days compared to 50 days for those in the placebo group. There was also clinical improvement in dogs that had CHF.

BREED

Lab Mix

SEX

Neutered Male

Diuretics: Lasix should be administered at 2-4 mg/kg PO BID-TID as needed and subsequently reduced to the lowest tolerated dose to maintain respiratory comfort, which is approximately 2 mg/kg PO BID (higher doses will be required as the disease progresses). Spironolactone (0.5 mg/kg PO BID) is used primarily for its anti-aldosterone effect and to decrease remodeling of the heart. In human trials, the addition of spironolactone to standard therapy has been shown to increase life span in cases of CHF.

AGE

16 Years

Angiotensin-converting enzyme (ACE) inhibitors: Enalapril (0.5 mg/kg BID) or benazepril (0.5 mg/kg PO Q12-24hr) therapy decreases systemic afterload, which diminishes the chamber stretching effects on the myocardium and thereby improves oxygen carrying capacity. A recent retrospective study showed that the early use of benazepril prolonged the onset of overt DCM in Dobermans with occult DCM.

WEIGHT

80.8 Pounds

INTERPRETED BY

Eric Lindquist, DMV
DABVP, Cert. IVUSS

Anti-arrhythmics: These should be used as needed. In cases of ventricular tachycardia where severe systolic dysfunction is a possibility, amiodarone (10 mg/kg PO Q24hr until stabilized and then 8 mg/kg PO Q24hr) and mexilitine (5-8 mg/kg PO TID) can be used. Although beta blockers, such as sotalol, can be used, they must be prescribed with extreme caution in dogs with severe systolic dysfunction as they have a decreased inotropic effect. Therapy for atrial fibrillation would include diltiazem (start at 0.5 mg/kg PO TID and increase to a target dose of 2 mg/kg PO TID) and/or digoxin, or amiodarone.

IMAGING PERFORMED BY

Sara Hansen

HOSPITAL NAME

Countryside VS

Carvedilol: Carvedilol is a calcium channel blocker, acts as a positive inotrope and free radical scavenger, and has ACE inhibiting effects. The target dose is approximately 1 mg/kg BID; it should be titrated up gradually from 0.25 mg/kg with dose adjustments made every 2 weeks until the ideal dose is reached.

REFERRING VET

Dr. Eichmann

Morphine: Morphine (0.025-0.05 mg/kg IV) decreases anxiety and improves respiratory efficiency and oxygen consumption. Morphine also dilates splanchnic vasculature and increases venous capacitance thereby reducing pulmonary edema.

INVOICE

16646

Supplements: These may aid in some cases of DCM. In taurine-deficient patients (based on plasma or whole blood taurine levels), one should supplement taurine at 500 mg PO BID and L-carnitine at 175 mg/kg PO BID. Coenzyme Q10 is also used as a means of myocardial ischemic

DATE

7/15/22



PATIENT

Tank Beals

prevention (30-90mg BID). Omega-3 fatty acid supplements can help with cell membrane stabilization and be used as inflammatory mediators (EPA 40mg/kg, DHA 25mg/kg PO Q24hr).

SPECIES

Canine

Salt restriction: An optimized high-quality protein diet (4gm/100kcal) that is mildly restricted in salt should be considered to minimize the onset of sodium-induced volume overloads.

BREED

Lab Mix

Monitoring: Serum chemistry (i.e., BUN/creatinine, electrolytes), blood pressure, and thoracic radiographs should be performed as needed 5-7 days after therapy has been initiated. One should conduct a follow-up echocardiogram in 1-6 months to assess myocardial function and the possible progression of the systolic dysfunction; medication should be changed or modified as needed. An electrocardiogram should be repeated as needed to monitor arrhythmias and the patient's response to therapy. The best means of monitoring progress at home is to observe the resting respiratory rate. A study showed that the resting respiratory rate obtained at home was the strongest predictor of improving or worsening of CHF and/or pulmonary edema.

SEX

Neutered Male

AGE

16 Years

Prognosis: The prognosis is variable and largely dependent on the individual animal and its response to therapy.

WEIGHT

80.8 Pounds

References:

Fuentes VL, Corcoran B, French A, Schober KE, Kleemann R, Justus C. A double-blind, randomized, placebo-controlled study of pimobendan in dogs with dilated cardiomyopathy. *J Vet Intern Med.* 2002;16:255-261.

INTERPRETED BY

Eric Lindquist, DMV
DABVP, Cert. IVUSS

O'Grady MR, Minors SL, O'Sullivan ML, et al. Effect of pimobendan on case fatality rate in Doberman Pinschers with congestive heart failure caused by dilated cardiomyopathy. *J Vet Intern Med* 2008;22:897-904.

IMAGING PERFORMED BY

Sara Hansen

O'Grady MR, O'Sullivan ML, Minors SL, et al. Efficacy of benazepril hydrochloride to delay the progression of occult dilated cardiomyopathy in Doberman Pinschers. *J Vet Intern Med* 2009;23:977-83.

HOSPITAL NAME

Countryside VS

O'Grady MR, O'Sullivan ML, Pyle WG, et al. Evaluation of 10 genes encoding cardiac proteins in Doberman Pinschers with dilated cardiomyopathy. *Am J Vet Res* 2011;72:932-39.

REFERRING VET

Dr. Eichmann

Wess G, Butz V, Mahling M, et al. Evaluation of N-terminal pro-B-type natriuretic peptide as a diagnostic marker of various stages of cardiomyopathy in Doberman Pinschers. *Am J Vet Res* 2011;72:642-49.

INVOICE

16646

DATE

7/15/22