



PATIENT

Sushi Figueredo

SPECIES

Feline

BREED

Domestic Shorthair

SEX

Spayed female

AGE

15 years

WEIGHT

12.37 lbs

INTERPRETED BY

Eric Lindquist, DMV
DABVP, Cert. IVUSS

IMAGING PERFORMED BY

Michaleen

HOSPITAL NAME

DPC VH

REFERRING VET

Dr. White

INVOICE

31732

DATE

7/15/22

PRESENTING CLINICAL SIGNS

History: Reason for Visit: adr, NOT EATING VOMITING History: PET IS HERE TODAY FOR VOMITING PINK LIKE, NOT EATING FOR 2 DAYS- NO INTEREST/ ACTIVITY LEVEL SEEMED BETTER THIS MORNING PER O- DRANK A GOOD AMOUNT BUT THEN VOMITED AFTER
Abnormal PE/Chem/CBC/UA Results: Hydration: Appropriately hydrated Mentation: BAR, growling EENT: No nasal discharge; clear no discharge OU; clean no debris AU; No cough on tracheal palpation. Oral Cavity: mild to mod dental tartar present, mod gingivitis - worse on upper L arcade Lymph Nodes: Symmetrical, no changes in size, shape, consistency Skin: Good hair coat, no signs of ectoparasites. No lesions noted. CV/Respiratory: No murmur or crackles/wheezing auscultated. Normal bronchovesicular sounds. Abd/GI: tense abdomen, mildly distended Uro/Perineum: N Musculoskeletal: Ambulatory x4, no lameness noted. Painful hips BCS 8/9 Neurological: Appropriate Fecal: Diagnostic Testing Needed: AUS, bloodwork, UA Declined Diagnostics/Treatments: Findings: AUS - consult pending CBC/Chem/UA - WNL, seelabs Assessment: vomiting, anorexia; overweight; overweight; OA

ULTRASONOGRAPHIC EXAMINATION OF THE ABDOMEN

Urinary System

The **urinary bladder**, trigone, and pelvic urethra presented normal thicknesses and normal tone. The ureters were not visible which is normal. No uroliths or sediment were visualized and anechoic urine was present. No evidence of inflammatory or neoplastic changes was noted. Ureteral papillae were normal.

The **kidneys** revealed largely normal size and structure, corticomedullary definition and ratio (cortex 1/3 of medulla) were essentially maintained with some age-related loss of curvilinear patterns regarding the capsule and C/M junction. The cortices presented largely uniform texture with some increased echogenicity expected for his age patient. Medullary structure differed distinctly from that of the cortex and no evidence of pelvic dilatation was present. The left kidney revealed cortical infarcts and mineralization. The left kidney measured 3.0 cm with pinpoint, non-obstructive mineralization. The right kidney measured 3.0 cm.

Adrenal Glands

Both **adrenal glands** were visualized and recognized as having normal shape, size, position and echogenicity for this breed. The phrenic vasculature, glandular echogenicity and detail were unremarkable. Capsule, cortex, and medullary definition were normal for this age patient.

Spleen

The **spleen** presented a smooth homogeneous parenchyma hyperechoic to liver and renal cortical parenchyma. The capsule was smooth without noticeable expansion or deviation from within the spleen or adjacent pathology. The splenic vasculature demonstrated normal volume without signs of congestion or thrombosis. No sonographic evidence of acute or chronic inflammatory, neoplastic, or infarctual changes was noted.



PATIENT

Sushi Figueredo

SPECIES

Feline

BREED

Domestic Shorthair

SEX

Spayed female

AGE

15 years

WEIGHT

12.37 lbs

INTERPRETED BY

Eric Lindquist, DMV
DABVP, Cert. IVUSS

IMAGING PERFORMED BY

Michaleen

HOSPITAL NAME

DPC VH

REFERRING VET

Dr. White

INVOICE

31732

DATE

7/15/22

Liver

The **liver** images submitted revealed subjectively normal liver size, contour, and structure. Parenchymal echogenicity was naturally coarse and hypoechoic to the spleen. Vascular and biliary tracts were of normal volume with no evidence of congestion. The gallbladder presented acceptably thin walls with primarily anechoic content. The cystic and common bile ducts were normal. No pathological hepatic lymphadenopathy was evident. No overt structural evidence of inflammatory, infiltrative or regenerative pathology was evident.

Gastrointestinal

The **gastrointestinal tract** revealed minor variable thickening and echogenic submucosal changes most consistent with low grade end result of chronic GI disease such as IBD and may be related to malassimilation of nutrients if any weight loss is present. No obvious neoplastic patterns were noted and luminal content as unremarkable.

Pancreas

The base and limbs of the **pancreas** were observed to be largely isoechoic to surrounding omental fat. Some parenchymal remodeling, however, with mild deviation from curvilinear normalcy was observed. Pancreatic duct and capsular irregularities were present consistent with age related changes. If pain upon imaging (+ Murphy sign) was present or if the patient is focally painful in subxiphoid palpation then low-grade smoldering chronic pancreatitis should be suspected.

Free Abdomen

Mesenteric remodeling was noted around the ileocecal junction.

ULTRASONOGRAPHIC FINDINGS

Minor intestinal thickening.

Age related renal changes, occasional infarct.

INTERPRETATION OF THE FINDINGS & FURTHER RECOMMENDATIONS

There was no evidence of neoplastic criteria. Inflammatory bowel is likely. Endoscopy would be ideal or full thickness GI biopsies, yet no neoplastic criteria was met.



PATIENT

Sushi Figueredo

SPECIES

Feline

BREED

Domestic Shorthair

SEX

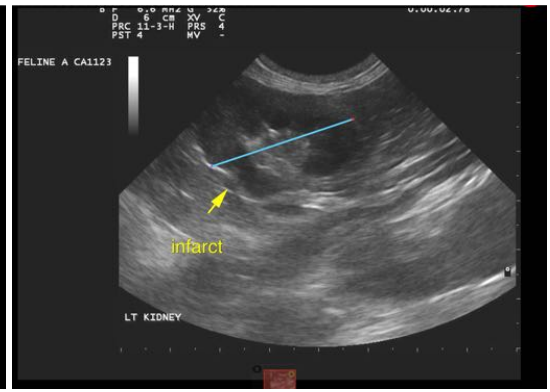
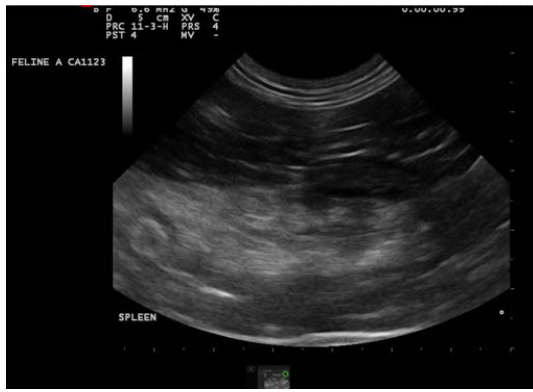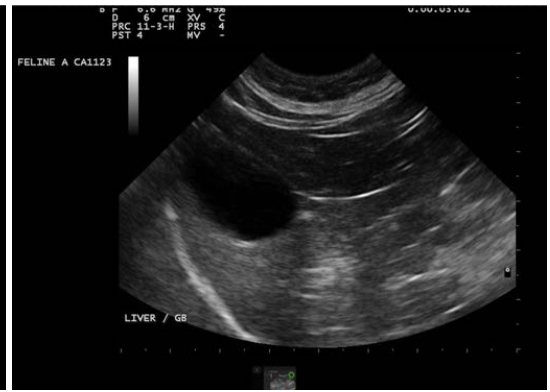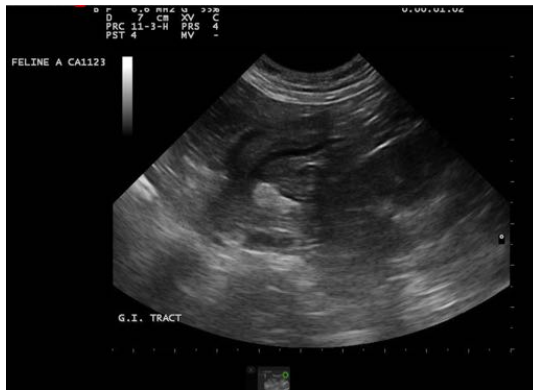Spayed female

AGE

15 years

WEIGHT

12.37 lbs



INTERPRETED BY

Eric Lindquist, DMV
DABVP, Cert. IVUSS

IMAGING PERFORMED BY

Michaleen

HOSPITAL NAME

DPC VH

REFERRING VET

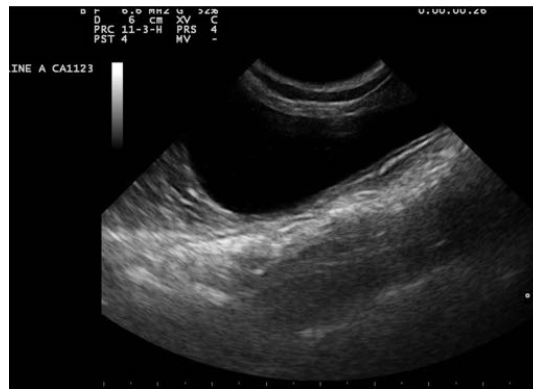Dr. White

INVOICE

31732

DATE

7/15/22



The information and recommendations provided are based on the images presented by the referring veterinarian/sonographer. No evaluation can be communicated regarding pathology that was not visible in the image/video clips provided.

Thank you for this referral. If the clinical or image interpretation does not parallel your findings or if I can be of any further assistance please contact me.

Eric Lindquist, DMV, DABVP, Cert. IVUSS, CEO of SonoPath.com
info@SonoPath.com