



PATIENT

Sammie Bearint

SPECIES

Feline

BREED

Domestic Shorthair

SEX

Spayed female

AGE

12 years

WEIGHT

3.69 lbs

INTERPRETED BY

Eric Lindquist, DMV
DABVP, Cert. IVUSS

IMAGING PERFORMED BY

Dr. Turner

HOSPITAL NAME

Pennsauken Animal
Hospital and Urgent
Care

REFERRING VET

Dr. Turner

INVOICE

31730

DATE

7/15/22

PRESENTING CLINICAL SIGNS

History: Hx diarrhea and significant weight loss along with hyperthyroidism which is uncontrolled. Pet is BAR at home, with normal appetite. No CSV/PU/PD noted at home. Pet is eating 8oz canned food per day.

Abnormal PE/Chem/CBC/UA Results: Abnormal: Mildly decreased muscle mass. No evidence of jaundice. Intestines uniformly thickened s palpable abdominal masses. BW offers T4 7.0 mg/dl, ALT 667, AST 153, ALP 208, GGT 13, T bili 1.4 (0 - 0.3). BW is attached.

ULTRASONOGRAPHIC EXAMINATION OF THE ABDOMEN

Urinary System

The **urinary bladder**, trigone, and pelvic urethra presented normal thicknesses and normal tone. The pelvic urethra was imaged 2.0 cm beyond the cystourethral junction and appeared normal. The ureters were not visible which is normal. No uroliths or sediment were visualized and anechoic urine was present. No evidence of inflammatory or neoplastic changes was noted. Ureteral papillae were normal.

The **kidneys** revealed largely normal size and structure, corticomedullary definition and ratio (cortex 1/3 of medulla) were essentially maintained with some age-related loss of curvilinear patterns regarding the capsule and C/M junction. The cortices presented largely uniform texture with some increased echogenicity expected for his age patient. Medullary structure differed distinctly from that of the cortex and no evidence of pelvic dilation was present. The left kidney measured 3.65 cm. The right kidney measured 3.86 cm.

Adrenal Glands

Both **adrenal glands** were visualized and recognized as having normal shape, size, position and echogenicity for this breed. The phrenic vasculature, glandular echogenicity and detail were unremarkable. Capsule, cortex, and medullary definition were normal for this age patient. The right adrenal gland measured 0.48 cm. The left adrenal gland measured 0.38 cm.

Spleen

The **spleen** presented a smooth homogeneous parenchyma hyperechoic to liver and renal cortical parenchyma. The capsule was smooth without noticeable expansion or deviation from within the spleen or adjacent pathology. The splenic vasculature demonstrated normal volume without signs of congestion or thrombosis. No sonographic evidence of acute or chronic inflammatory, neoplastic, or infarctual changes was noted.

Liver

The **liver** images submitted revealed subjectively normal liver size, contour, and structure. Parenchymal echogenicity was naturally coarse and hypoechoic to the spleen. Vascular and biliary tracts were of normal volume with no evidence of congestion. The gallbladder presented acceptably thin walls with primarily anechoic content. The cystic and common bile ducts were normal. No pathological hepatic



PATIENT	lymphadenopathy was evident. No overt structural evidence of inflammatory, infiltrative or regenerative pathology was evident.
Sammie Bearint	
SPECIES	Gastrointestinal
Feline	A minor amount of non-shadowing, non-obstructive ingesta was noted in the stomach. Transit of chyme into the small intestine was normal. Hairball type density was noted in the stomach. Curvilinear patterns were maintained throughout the GI tract. No evidence of pathology. Small and large intestine demonstrated normal luminal chyme and stool consistency respectively. No obstructive or overt infiltrative disease was noted. No associated abnormal lymphatic activity was noted.
BREED	
Domestic Shorthair	
SEX	
Spayed female	
AGE	
12 years	
WEIGHT	
3.69 lbs	
INTERPRETED BY	
Eric Lindquist, DMV DABVP, Cert. IVUSS	
IMAGING PERFORMED BY	
Dr. Turner	
HOSPITAL NAME	
Pennsauken Animal Hospital and Urgent Care	
REFERRING VET	
Dr. Turner	
INVOICE	
31730	
DATE	
7/15/22	

Pancreas

The left **pancreatic** limb revealed heterogenous, hypoechoic, nodular changes. The left pancreatic limb measured up to 1.0 cm.

ULTRASONOGRAPHIC FINDINGS

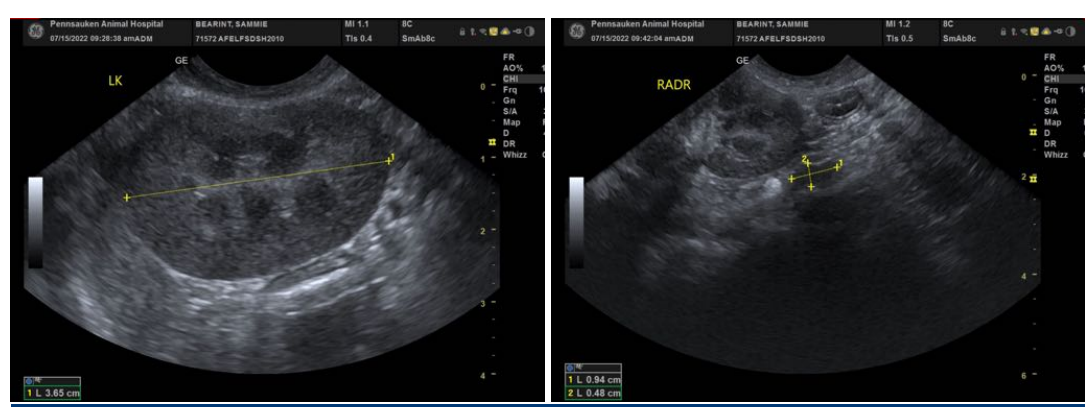
Heterogenous, hypoechoic pancreatic nodular changes. Inflammatory hepatopathy likely due to liver enzyme elevations. Chronic pancreatitis, cholangiohepatitis versus pancreatic carcinoma/nodular hyperplasia. Occult neoplasia is possible in the liver, but not suspected.

Hair density in the stomach and/or post prandial presentation.

Age related abdominal changes were noted elsewhere.

INTERPRETATION OF THE FINDINGS & FURTHER RECOMMENDATIONS

FNA of the pancreas is strongly encouraged. Left subxiphoid palpation is recommended to assess for any discomfort associated with the left pancreatic limb. Remodeling and nodular hyperplasia is likely. Emerging carcinoma is possible. If the patient is n.p.o. at the time of the sonogram then hairball therapy is indicated. FNA of the liver is warranted given the ALT elevations. The changes were minor. Inflammatory hepatopathy is likely given the liver enzyme elevations. The liver does not meet and neoplastic criteria at this time.





PATIENT

Sammie Bearint

SPECIES

Feline

BREED

Domestic Shorthair

SEX

Spayed female

AGE

12 years

WEIGHT

3.69 lbs

INTERPRETED BY

Eric Lindquist, DMV
DABVP, Cert. IVUSS

IMAGING PERFORMED BY

Dr. Turner

HOSPITAL NAME

Pennsauken Animal
Hospital and Urgent
Care

REFERRING VET

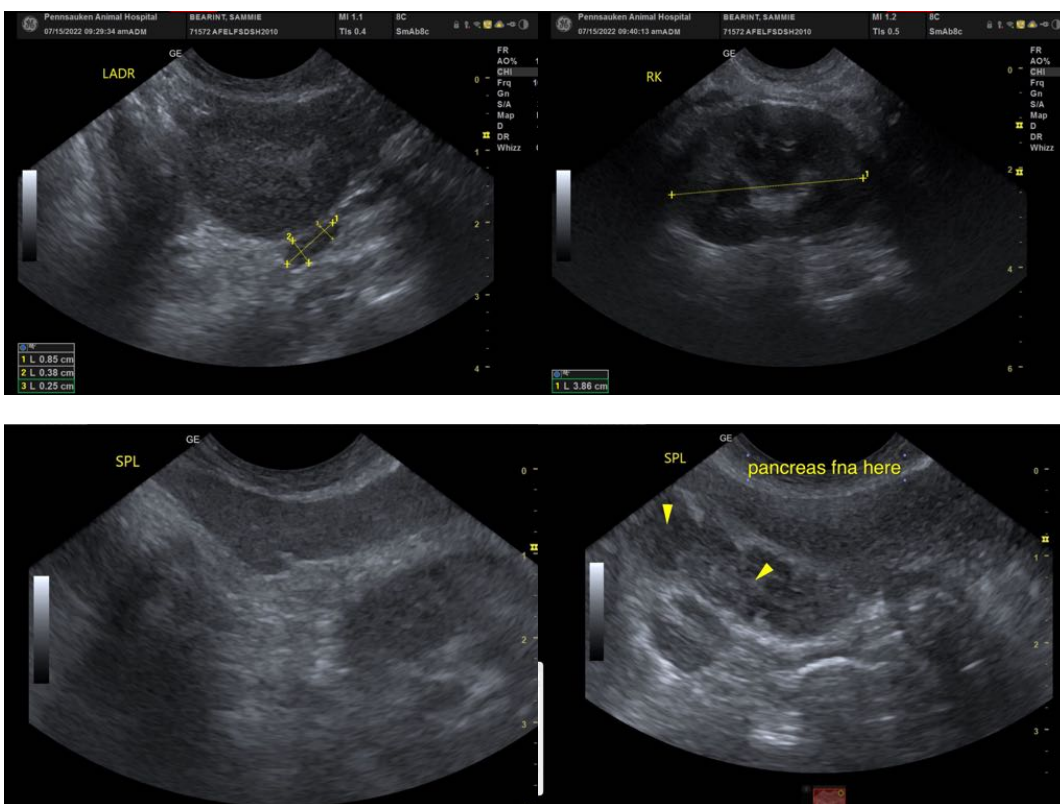
Dr. Turner

INVOICE

31730

DATE

7/15/22



The information and recommendations provided are based on the images presented by the referring veterinarian/sonographer. No evaluation can be communicated regarding pathology that was not visible in the image/video clips provided.

Thank you for this referral. If the clinical or image interpretation does not parallel your findings or if I can be of any further assistance please contact me.

Eric Lindquist, DMV, DABVP, Cert. IVUSS, CEO of SonoPath.com
info@SonoPath.com