



PATIENT PRESENTING CLINICAL SIGNS

Adele Hoffman Abdominal distention (suspect free fluid), prominent spine, peripheral edema extremities, systolic murmur 3/6. No current meds.
 Abnormal PE/Chem/CBC/UA Results: HCT 31% (regenerative).

SPECIES

Canine

ULTRASONOGRAPHIC EXAMINATION OF THE HEART & ABDOMEN

BREED

Mixed

SEX

Spayed Female

AGE

9 Years

WEIGHT

55 Pounds

CANINE CARDIAC PARAMETERS	MR VMAX (m/s)	TR VMAX (m/s)	LA/AO (Boon method)	LA/AO (Heart Base; Swe)	FS (%)	EF (%)	EPSS (cm)
NORMAL PARAMETER	4.5-5.5	<2.7	1.3	<1.6	28-40	40-100	<0.6
PATIENT	6.0		1.0	1.3	21	42	NM
CANINE CARDIAC PARAMETERS	HR (BPM)	AV VMAX (m/s)	PV MAX (m/s)	BODY WEIGHT (kg)	LA 2D short axis Base view (cm)	LVIDd Avg; 2D and m-mode short axis (cm)	LVIDs Avg; 2D and m-mode short axis (cm)
NORMAL PARAMETER	50-100	0.7-1.7	0.7-1.6	BELOW	BELOW	BELOW	BELOW
PATIENT	128	1.28	1.2		3.6	3.62	

INTERPRETED BY

Eric Lindquist, DMV
 DABVP, Cert. IVUSS

IMAGING PERFORMED BY

Kelly Vazquez

HOSPITAL NAME

North Jersey AH

REFERRING VET

Dr. Reidel

INVOICE

39539

DATE

7/15/22

Cardiac Presentation

The echocardiogram in this patient demonstrated normal **left atrial** size based on 3 different LA measurement methods. Chamber volumes and echogenicity were normal. The cranial and caudal **mitral** valve leaflets presented vegetative thickening consistent with endocardiosis. Doppler indicated measurable insufficiency. The **left ventricle** presented thicknesses with linear contour and was not dilated nor restricted. The **myocardium** presented normal echogenicity without subjective evidence of significant fibrotic or ischemic disease. **Contractility** of the ventricular walls was adequate and in normal range for this patient evidenced by the fractional shortening measurement and subjective evaluation of the different regions of the myocardium. The **left ventricular outflow** tract demonstrated normal laminar flow and subjective structural integrity. The **right atrium** and auricle revealed normal size, structure and content. No evidence of masses was noted or chamber overload. Minor **tricuspid** insufficiency noted at 2.2 m/sec. The **right ventricle** was of normal size (1/3 diameter of LV), chordae structure, myocardial echogenicity and thickness. **Pulmonic** tract assessment revealed normal valve structure, laminar flow, and diameter (approx. 1:1 pa/ao ratio). No visible **pericardial** or free pleura fluid was noted. No echographically detectable evidence of infiltrative disease was visible. The cranial **mediastinum and pericardial regions** were free of masses in the visible window.

Urinary System

The **urinary bladder**, trigone, and pelvic urethra presented normal thicknesses and normal tone. The ureters were not visible which is normal. No uroliths or sediment were visualized and anechoic urine was present. No evidence of inflammatory or neoplastic changes were noted. Ureteral papillae were normal.



PATIENT

Adele Hoffman

The **kidneys** revealed largely normal size and structure, corticomedullary definition and ratio (cortex 1/3 of medulla) were essentially maintained with some age-related loss of curvilinear patterns regarding the capsule and C/M junction. The cortices presented largely uniform texture with some increased echogenicity expected for his age patient. Medullary structure differed distinctly from that of the cortex and no evidence of pelvic dilation was present. The left kidney measured 5.92 cm. The right kidney measured 5.6 cm.

SPECIES

Canine

Adrenal Glands

BREED

Mixed

Both **adrenal glands** were visualized and recognized as having normal shape, size, position and echogenicity for this breed. The phrenic vasculature, glandular echogenicity and detail were unremarkable. Capsule, cortex, and medullary definition were normal for this age patient. The left adrenal gland measured 2.73 cm x 0.86 cm at the caudal pole and 0.63 cm at the cranial pole.

SEX

Spayed Female

Spleen

The **spleen** revealed multiple complex masses up to 16.5 cm with free fluid.

AGE

9 Years

Liver

The **liver** presented minor heterogeneous nodular changes with mild disruption of architecture. The gallbladder was unremarkable.

WEIGHT

55 Pounds

Gastrointestinal

Examination of the **gastrointestinal tract** revealed a stomach and intestine free of stasis, of normal wall thickness, acceptable curvilinear mural detail, and peristaltic activity. Small and large intestine demonstrated normal luminal chyme and stool consistency respectively. No obstructive or overt infiltrative disease was noted. No associated abnormal lymphatic activity was noted.

INTERPRETED BY

Eric Lindquist, DMV

Pancreas

DABVP, Cert. IVUSS

The base and limbs of the **pancreas** were observed to be largely isoechoic to surrounding omental fat. Pancreatic duct and capsular contour were acceptably normal and parenchyma respected normal curvilinear patterns. No overt evidence of active inflammatory or neoplastic disease was noted.

IMAGING PERFORMED BY

Kelly Vazquez

Free Abdomen

Free fluid noted in the abdomen with expansion of the splenic pathology into the regional omentum, rendering this presentation non-resectable.

HOSPITAL NAME

North Jersey AH

ULTRASONOGRAPHIC FINDINGS

- Stage B1 valvular disease
- Multiple splenic masses with regional omental spread and free fluid – strong potential for hepatic spread.

REFERRING VET

Dr. Reidel

INTERPRETATION OF THE FINDINGS & FURTHER RECOMMENDATIONS

Prognosis is poor. Hemangiosarcoma likely.

INVOICE

39539

DATE

7/15/22



PATIENT

Adele Hoffman

SPECIES

Canine

BREED

Mixed

SEX

Spayed Female

AGE

9 Years

WEIGHT

55 Pounds

INTERPRETED BY

Eric Lindquist, DMV
DABVP, Cert. IVUSS

IMAGING PERFORMED BY

Kelly Vazquez

HOSPITAL NAME

North Jersey AH

REFERRING VET

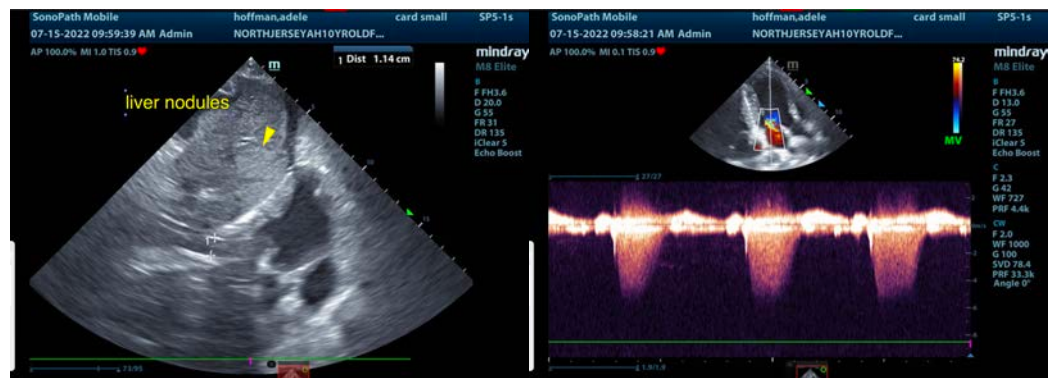
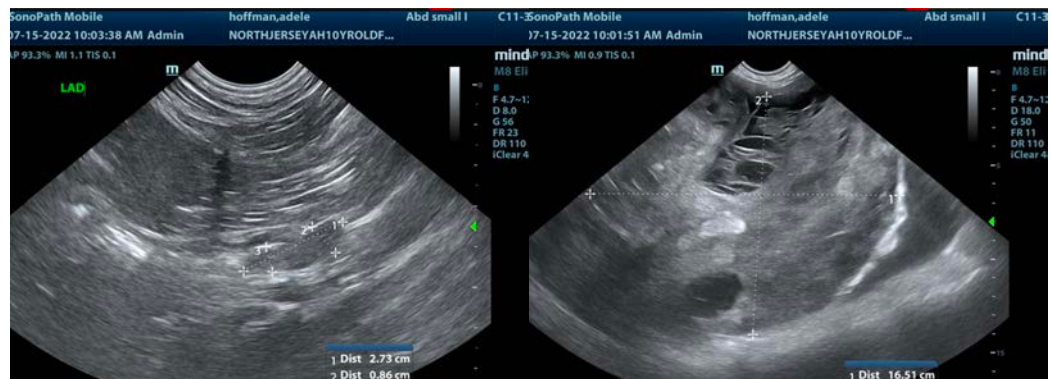
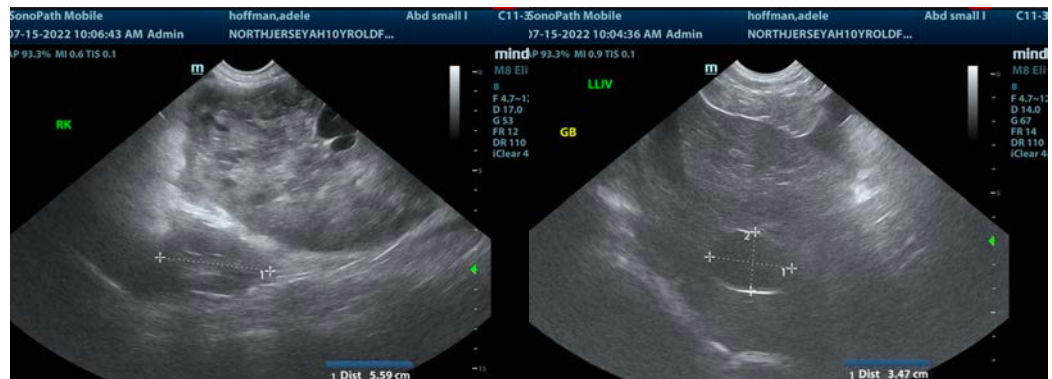
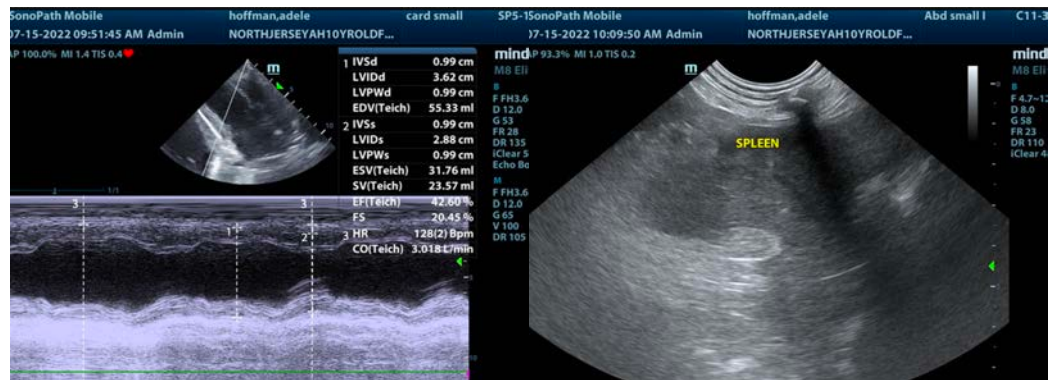
Dr. Reidel

INVOICE

39539

DATE

7/15/22





PATIENT

Adele Hoffman

SPECIES

Canine

BREED

Mixed

SEX

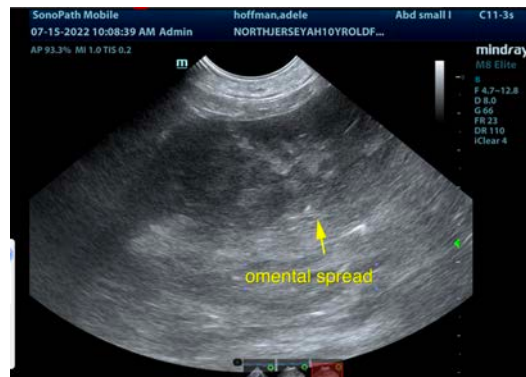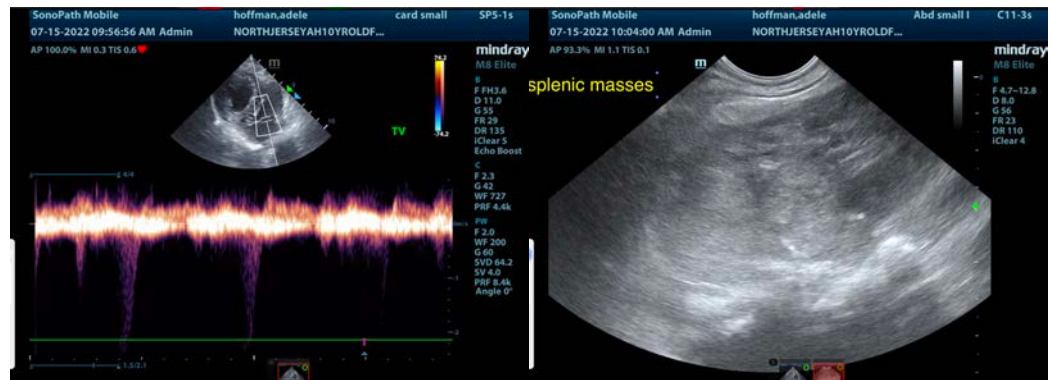
Spayed Female

AGE

9 Years

WEIGHT

55 Pounds



INTERPRETED BY

Eric Lindquist, DMV
DABVP, Cert. IVUSS

IMAGING PERFORMED BY

Kelly Vazquez

HOSPITAL NAME

North Jersey AH

REFERRING VET

Dr. Reidel

INVOICE

39539

DATE

7/15/22

The information and recommendations provided are based on the images presented by the referring veterinarian/sonographer. No evaluation can be communicated regarding pathology that was not visible in the image/video clips provided.

Thank you for this referral. If the clinical or image interpretation does not parallel your findings or if I can be of any further assistance please contact me.

Eric Lindquist, DMV, DABVP, Cert. IVUSS, CEO of SonoPath.com

info@SonoPath.com