



PATIENT

Saige Dulude

PRESENTING CLINICAL SIGNS

History: She's a Doberman Current meds: Prozac- Gaba+Torb for scan today

SPECIES

Canine

ULTRASONOGRAPHIC EXAMINATION OF THE HEART

BREED

Doberman

CANINE CARDIAC PARAMETERS	MR VMAX (m/s)	TR VMAX (m/s)	LA/AO (Boon method)	LA/AO (Heart Base; Swe)	FS (%)	EF (%)	EPSS (cm)
NORMAL PARAMETER	4.5-5.5	<2.7	1.3	<1.6	28-40	40-100	<0.6
PATIENT	--	--	1.0	1.0	35	66	0.27
CANINE CARDIAC PARAMETERS	HR (BPM)	AV VMAX (m/s)	PV MAX (m/s)	BODY WEIGHT (kg)	LA 2D short axis Base view (cm)	LVIDd Avg; 2D and m-mode short axis (cm)	LVIDs Avg; 2D and m-mode short axis (cm)
NORMAL PARAMETER	50-100	0.7-1.7	0.7-1.6				
PATIENT	118	1.50	.83	--	4.25	3.97	--

SEX

Spayed Female

AGE

9 Years

WEIGHT

70 Pounds

E-wave velocity = 80

Cardiac Presentation

The echocardiogram in this patient demonstrated normal **left atrial** size based on 3 separate methods of LA evaluation. The cranial and caudal **mitral** valve leaflets presented normal linear structure, extension in systole, and union in diastole with normal kinesis. The **left ventricle** presented thicknesses with linear contour and was not dilated nor restricted. The **myocardium** presented normal echogenicity without subjective evidence of significant fibrotic or ischemic disease. **Contractility** of the ventricular walls was adequate and in normal range for this patient evidenced by the fractional shortening measurement and subjective evaluation of the different regions of the myocardium. The **left ventricular outflow** tract demonstrated normal laminar flow and subjective structural integrity. The **right atrium** and auricle revealed normal size, structure and content. No evidence of masses was noted. **Tricuspid** valvular assessment demonstrated adequate linear morphology and kinesis. The **right ventricle** was of normal size (1/3 diameter of LV), chordae structure, myocardial echogenicity and thickness. Minor pulmonic insufficiency was noted at 2.0 m/s. No visible **pericardial** or free pleura fluid was noted. The cranial **mediastinum and pericardial and extra-cardiac regions** were free of masses in the visible window.

INTERPRETED BY

Eric Lindquist, DMV
DABVP, Cert. IVUSS

IMAGING PERFORMED BY

Jessica Miller

HOSPITAL NAME

The Gentle Vet

REFERRING VET

Dr. Dulude

ULTRASONOGRAPHIC FINDINGS

- Normal echocardiogram with trivial pulmonic insufficiency

INVOICE

23382

INTERPRETATION OF THE FINDINGS & FURTHER RECOMMENDATIONS

This is a largely normal variant for this breed. No evidence of DCM or other pathology. If Further DCM screening is desired, then Holter monitor would be indicated to assess the arrhythmogenic form, even though no arrhythmogenic activity was noted during the echocardiogram.

DATE

7/14/23



PATIENT

Saige Dulude

SPECIES

Canine

BREED

Doberman

SEX

Spayed Female

AGE

9 Years

WEIGHT

70 Pounds

INTERPRETED BY

Eric Lindquist, DMV
DABVP, Cert. IVUSS

IMAGING PERFORMED BY

Jessica Miller

HOSPITAL NAME

The Gentle Vet

REFERRING VET

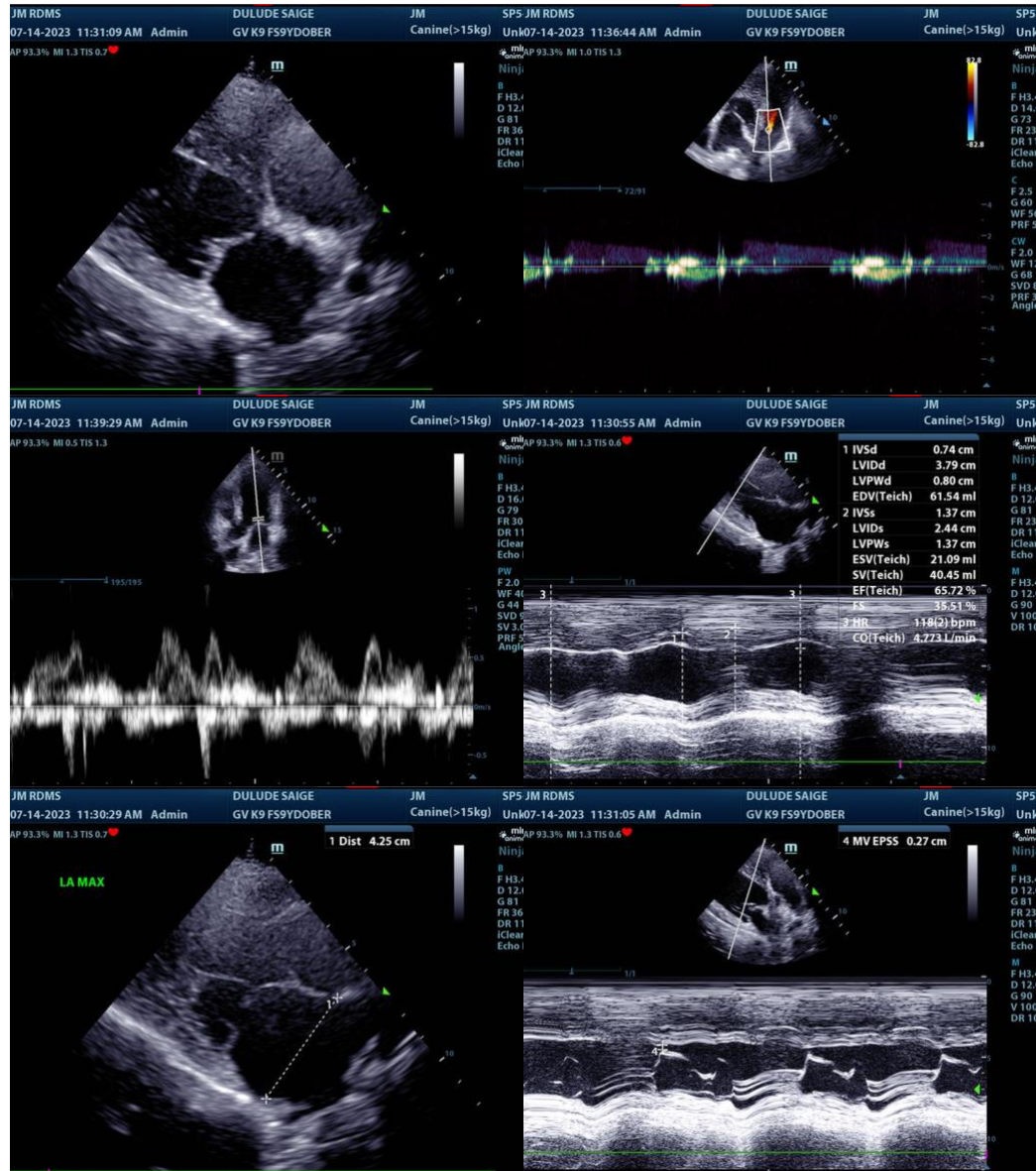
Dr. Dulude

INVOICE

23382

DATE

7/14/23





PATIENT

Saige Dulude

SPECIES

Canine

BREED

Doberman

SEX

Spayed Female

AGE

9 Years

WEIGHT

70 Pounds

INTERPRETED BY

Eric Lindquist, DMV
DABVP, Cert. IVUSS

IMAGING PERFORMED BY

Jessica Miller

HOSPITAL NAME

The Gentle Vet

REFERRING VET

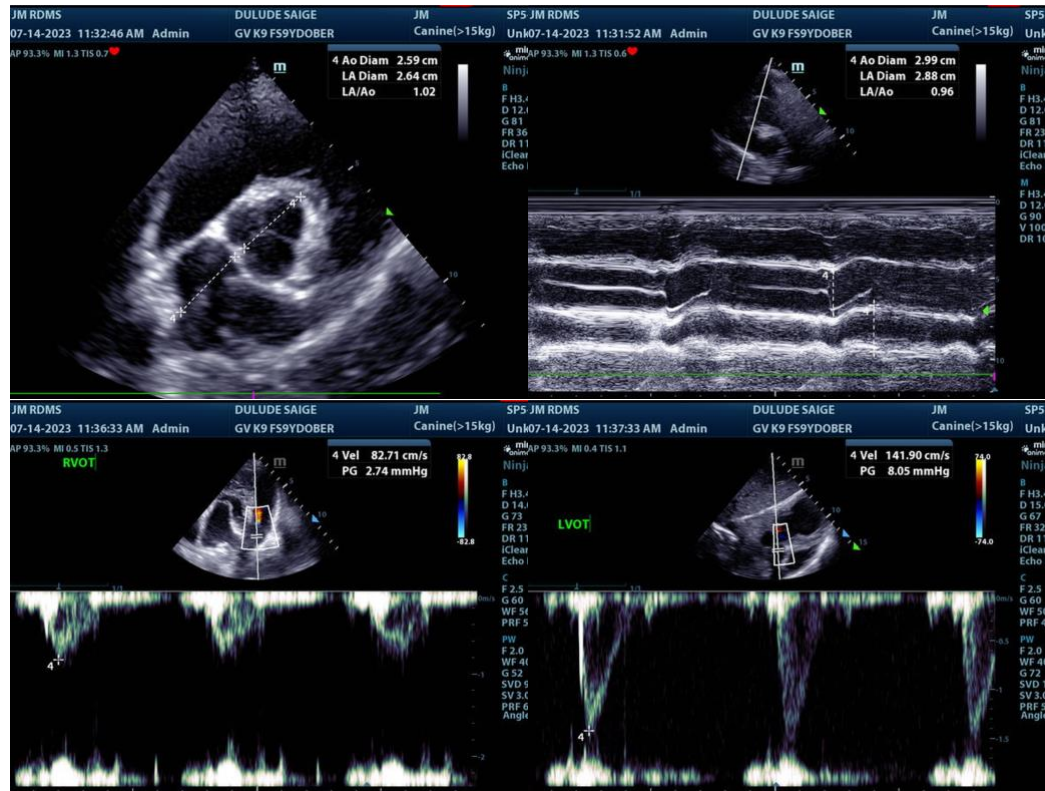
Dr. Dulude

INVOICE

23382

DATE

7/14/23



The information and recommendations provided are based on the images presented by the referring veterinarian. No evaluation can be communicated regarding pathology that was not visible in the image/video clips provided.

Thank you for this referral. If the clinical or image interpretation does not parallel your findings or if I can be of any further assistance please contact me.

Eric Lindquist, DMV, DABVP, Cert. IVUSS, CEO of SonoPath.com
info@SonoPath.com