



**PATIENT**

Romeo Thorpe

**SPECIES**

Canine

**BREED**

Maltese

**SEX**

Neutered Male

**AGE**

11 Years

**WEIGHT**

6.5 Pounds

**PRESENTING CLINICAL SIGNS**

History: 6 month recheck Echo. Current meds: Apoquel, Betagen, Pimobendan, Furosemide, Enalapril  
Abnormal PE/Chem/CBC/UA Results: Phos 2.4, CI 107, K+ 3.3 UA SG: 1.011

**ULTRASONOGRAPHIC EXAMINATION OF THE HEART**

CANINE CARDIAC PARAMETERS	MR VMAX (m/s)	TR VMAX (m/s)	LA/AO (Boon method)	LA/AO (Heart Base; Swe)	FS (%)	EF (%)	EPSS (cm)
<b>NORMAL PARAMETER</b>	4.5-5.5	<2.7	1.3	<1.6	28-40	40-100	<0.6
<b>PATIENT</b>	5.12	2.27	1.1	1.3	56	89	NM
CANINE CARDIAC PARAMETERS	HR (BPM)	AV VMAX (m/s)	PV MAX (m/s)	BODY WEIGHT (kg)	LA 2D short axis Base view (cm)	LVIDd Avg; 2D and m-mode short axis (cm)	LVIDs Avg; 2D and m-mode short axis (cm)
<b>NORMAL PARAMETER</b>	50-100	0.7-1.7	0.7-1.6				
<b>PATIENT</b>	125	1.10	1.50	--	2.65	2.05	--

E-wave=0.82 cm.

**INTERPRETED BY**

Eric Lindquist, DMV  
DABVP, Cert. IVUSS

**IMAGING PERFORMED BY**

Jessica Miller

**HOSPITAL NAME**

The Gentle Vet

**REFERRING VET**

Dr. Dulude

**INVOICE**

23381

**DATE**

7/14/23

**Cardiac Presentation**

The cardiac presentation presented normal volumes in all four chambers with adequate contractility. Mitral and tricuspid insufficiency were noted, persistent. Pericardial and pleural spaces were unremarkable. The mitral insufficiency was moderate with central to eccentric jet- this is consistent with compensated valvular disease on the current protocol.

**ULTRASONOGRAPHIC FINDINGS**

- Compensated mitral and tricuspid insufficiency on the current protocol.

**INTERPRETATION OF THE FINDINGS & FURTHER RECOMMENDATIONS**

No adjustments to medications is recommended. Recheck echo in 6-12 months.



**PATIENT**

Romeo Thorpe

**SPECIES**

Canine

**BREED**

Maltese

**SEX**

Neutered Male

**AGE**

11 Years

**WEIGHT**

6.5 Pounds

**INTERPRETED BY**

Eric Lindquist, DMV  
DABVP, Cert. IVUSS

**IMAGING PERFORMED BY**

Jessica Miller

**HOSPITAL NAME**

The Gentle Vet

**REFERRING VET**

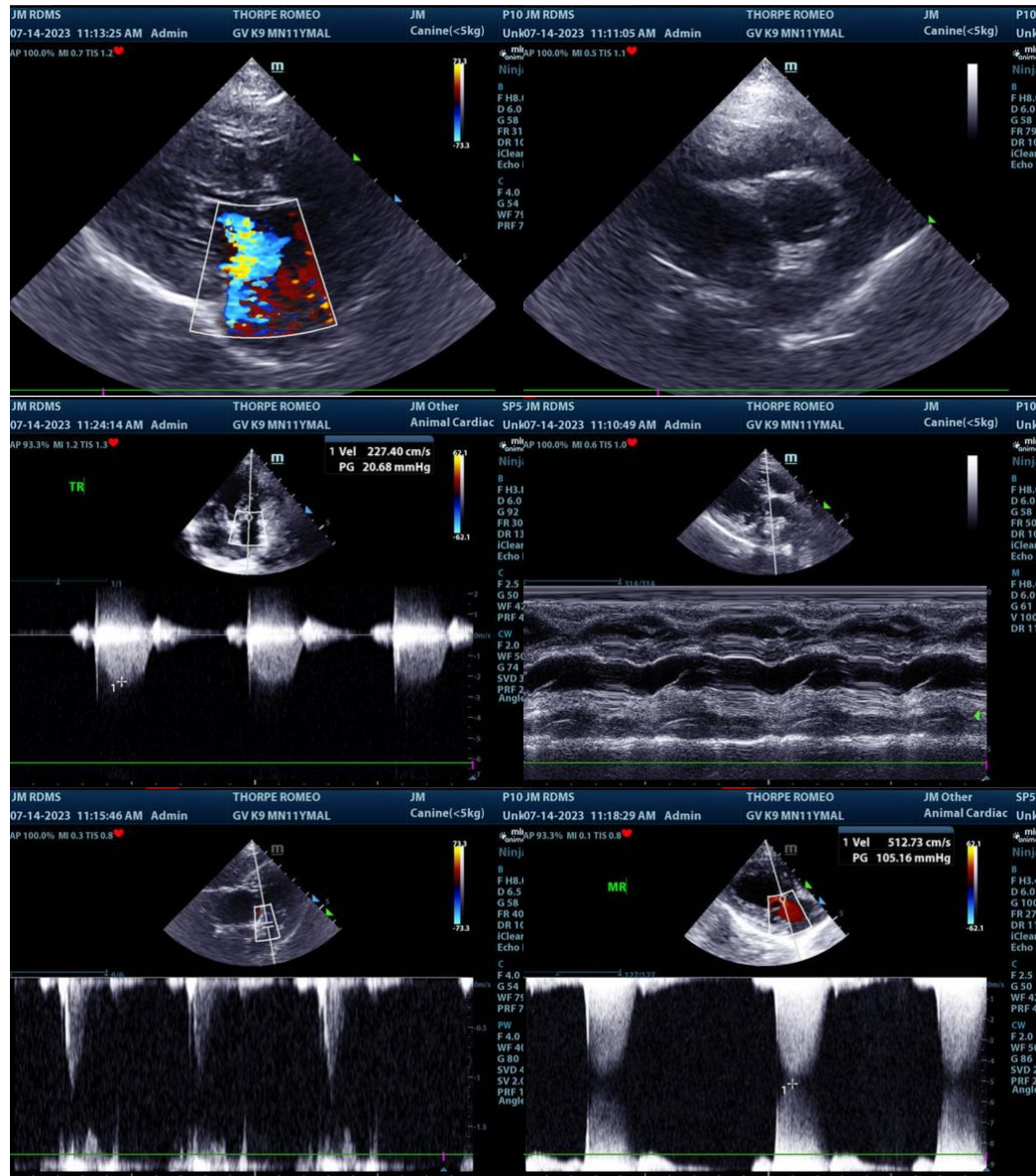
Dr. Dulude

**INVOICE**

23381

**DATE**

7/14/23





**PATIENT**

Romeo Thorpe

**SPECIES**

Canine

**BREED**

Maltese

**SEX**

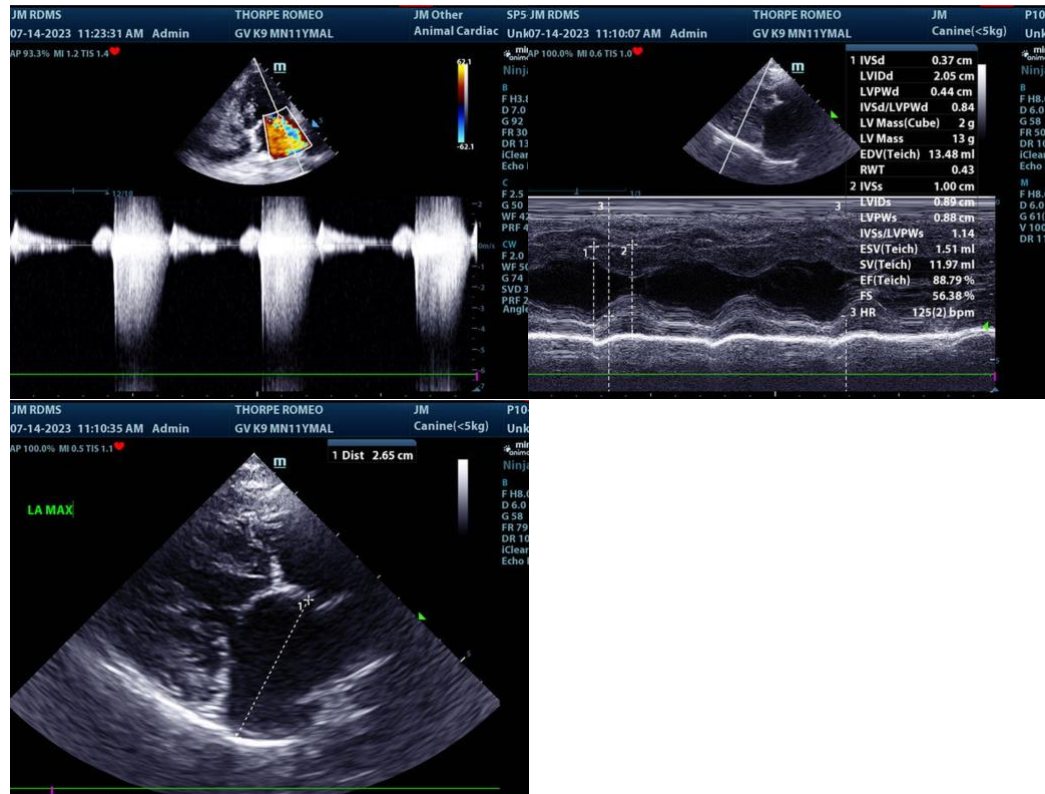
Neutered Male

**AGE**

11 Years

**WEIGHT**

6.5 Pounds



The information and recommendations provided are based on the images presented by the referring veterinarian. No evaluation can be communicated regarding pathology that was not visible in the image/video clips provided.

Thank you for this referral. If the clinical or image interpretation does not parallel your findings or if I can be of any further assistance please contact me.

**Eric Lindquist**, DMV, DABVP, Cert. IVUSS, CEO of SonoPath.com  
info@SonoPath.com

**INTERPRETED BY**

Eric Lindquist, DMV  
DABVP, Cert. IVUSS

**IMAGING PERFORMED BY**

Jessica Miller

**HOSPITAL NAME**

The Gentle Vet

**REFERRING VET**

Dr. Dulude

**INVOICE**

23381

**DATE**

7/14/23