



PATIENT

Parker Guerriero

SPECIES

Canine

BREED

Beagle Mix

SEX

Neutered Male

AGE

10 Years

WEIGHT

50.9 Pounds

INTERPRETED BY

Eric Lindquist, DMV
DABVP, Cert. IVUSS

IMAGING PERFORMED BY

Heather

HOSPITAL NAME

ACC Flanders

REFERRING VET

Dr. Hallihan

INVOICE

23358

DATE

7/14/23

PRESENTING CLINICAL SIGNS

History: recheck from yesterday - ileus - delayed outflow

LIMITED ULTRASONOGRAPHIC EXAMINATION

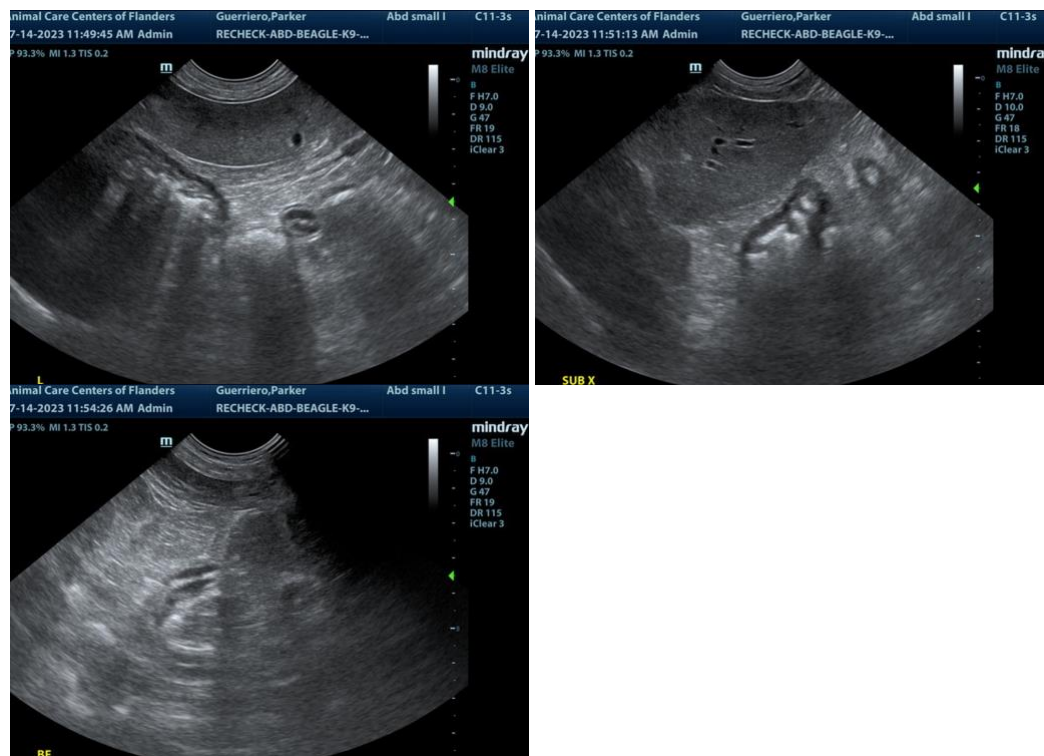
Examination of the stomach revealed empty GI tract. No residual stasis was present. The small intestine and colon were unremarkable. The GI presentation appears to have resolved.

ULTRASONOGRAPHIC FINDINGS

- Resolved GI presentation.

INTERPRETATION OF THE FINDINGS & FURTHER RECOMMENDATIONS

No residual pathology.



The information and recommendations provided are based on the images presented by the referring veterinarian. No evaluation can be communicated regarding pathology that was not visible in the image/video clips provided.

Thank you for this referral. If the clinical or image interpretation does not parallel your findings or if I can be of any further assistance please contact me.

Eric Lindquist, DMV, DABVP, Cert. IVUSS, CEO of SonoPath.com
info@SonoPath.com