



**PATIENT PRESENTING CLINICAL SIGNS**

Lilly Winters History: Grade 3/6 murmur, difficulty breathing occasionally

**SPECIES** Abnormal PE/Chem/CBC/UA Results: BP 137/113(122),111/91(97), 134/111(121). Blood pending

Canine

**ULTRASONOGRAPHIC EXAMINATION OF THE HEART**

**BREED**

Yorkie Mix

**SEX**

Spayed Female

**AGE**

16 Years

**WEIGHT**

7.4

CANINE CARDIAC PARAMETERS	MR VMAX (m/s)	TR VMAX (m/s)	LA/AO (Boon method)	LA/AO (Heart Base; Swe)	FS (%)	EF (%)	EPSS (cm)
NORMAL PARAMETER	4.5-5.5	<2.7	1.3	<1.6	28-40	40-100	<0.6
PATIENT	5.73	2.4	1.4	2.0	58	89	NM
CANINE CARDIAC PARAMETERS	HR (BPM)	AV VMAX (m/s)	PV MAX (m/s)	BODY WEIGHT (kg)	LA 2D short axis Base view (cm)	LVIDd Avg; 2D and m-mode short axis (cm)	LVIDs Avg; 2D and m-mode short axis (cm)
NORMAL PARAMETER	50-100	0.7-1.7	0.7-1.6				
PATIENT	119	1.20	.60	--	--	2.21	--

**INTERPRETED BY**

Eric Lindquist, DMV DABVP, Cert. IVUSS

**IMAGING PERFORMED BY**

JK

**HOSPITAL NAME**

Hamburg VC

**REFERRING VET**

Dr. Branning

**INVOICE**

23390

**DATE**

7/14/23

**Cardiac Presentation**

The cardiac presentation in this patient presented mild volume overload in the right and left atrium. Mitral and tricuspid insufficiency were noted. Hepatic vein dilation was present. No pericardial or pleural effusion was noted. Prolapse of both mitral and tricuspid apparatuses were noted. The LA max and LA/AO heart base views are excessive. Given the hepatic vein dilation, I believe that tricuspid insufficiency velocity is likely underestimated owing to angular interference.

**ULTRASONOGRAPHIC FINDINGS**

- Stage B-2 valvular disease with potential pulmonary hypertension

**INTERPRETATION OF THE FINDINGS & FURTHER RECOMMENDATIONS**

There is likely a primary respiratory component to this patient, as the patient is not in overt heart failure. However, I do recommend initiating Pimobendan 0.3 mg/kg BID, ace-inhibitor 0.5 mg/kg SID, progressing to BID and spironolactone 1-2 mg/kg BID, then reassessment of the clinical signs. Blood pressure measurements are warranted. Recheck echo in 3-6 months.



**PATIENT**

Lilly Winters

**SPECIES**

Canine

**BREED**

Yorkie Mix

**SEX**

Spayed Female

**AGE**

16 Years

**WEIGHT**

7.4

**INTERPRETED BY**

Eric Lindquist, DMV  
DABVP, Cert. IVUSS

**IMAGING  
PERFORMED BY**

JK

**HOSPITAL NAME**

Hamburg VC

**REFERRING VET**

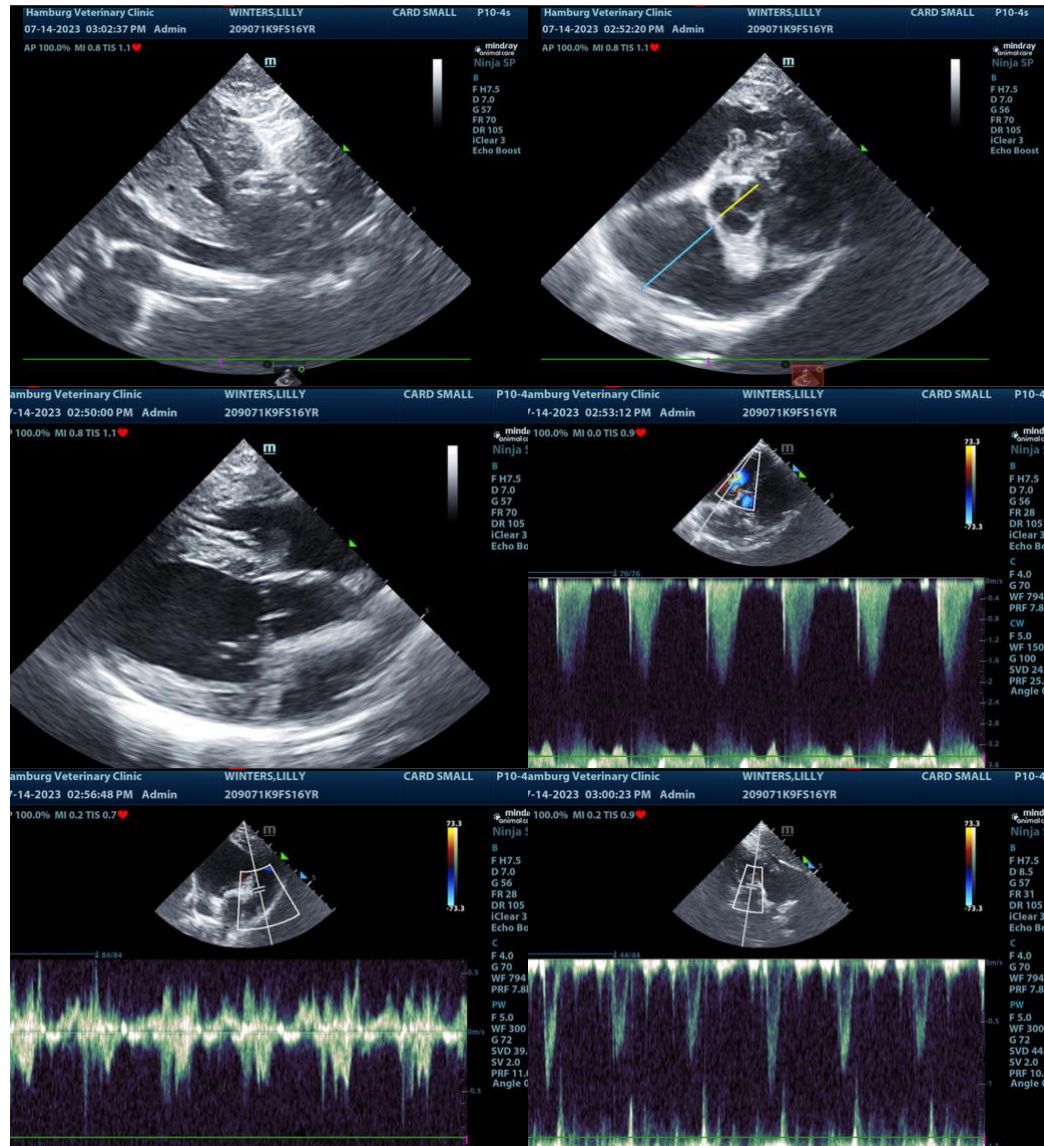
Dr. Branning

**INVOICE**

23390

**DATE**

7/14/23





**PATIENT**

Lilly Winters

**SPECIES**

Canine

**BREED**

Yorkie Mix

**SEX**

Spayed Female

**AGE**

16 Years

**WEIGHT**

7.4

**INTERPRETED BY**

Eric Lindquist, DMV  
DABVP, Cert. IVUSS

**IMAGING PERFORMED BY**

JK

**HOSPITAL NAME**

Hamburg VC

**REFERRING VET**

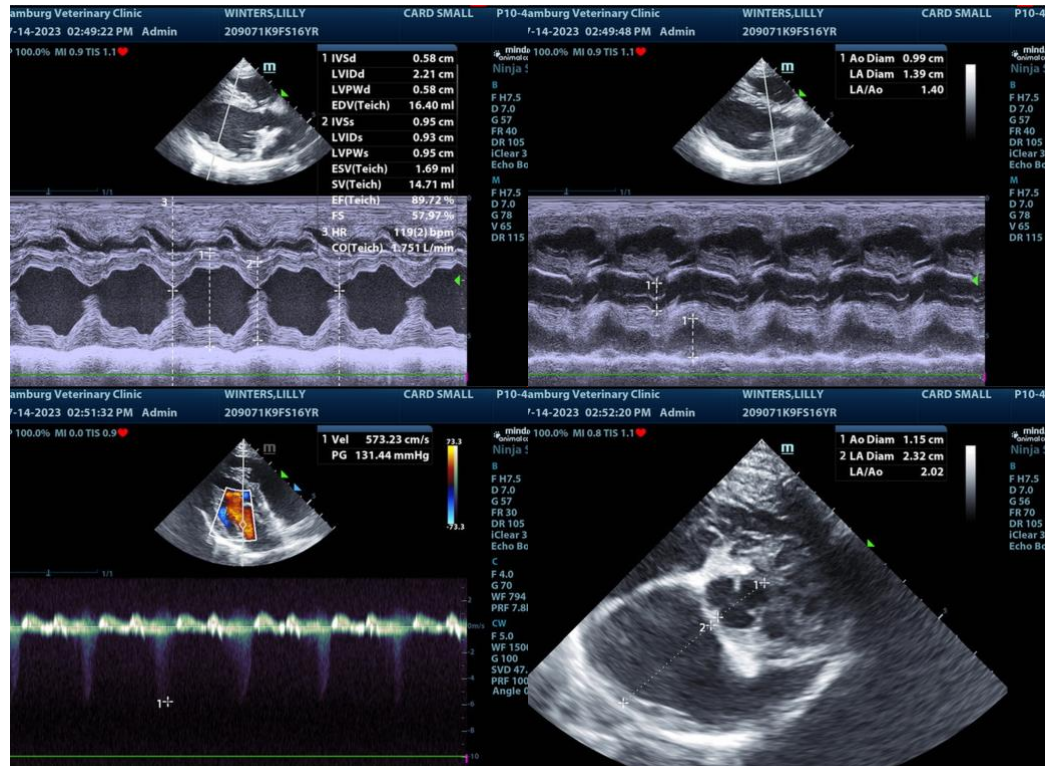
Dr. Branning

**INVOICE**

23390

**DATE**

7/14/23



The information and recommendations provided are based on the images presented by the referring veterinarian. No evaluation can be communicated regarding pathology that was not visible in the image/video clips provided.

Thank you for this referral. If the clinical or image interpretation does not parallel your findings or if I can be of any further assistance please contact me.

**Eric Lindquist**, DMV, DABVP, Cert. IVUSS, CEO of SonoPath.com  
info@SonoPath.com