



PATIENT PRESENTING CLINICAL SIGNS

Iris Daly History of diabetes mellitus, previously well controlled. Seen over the weekend for ADR, hyporexia. Cranial abdominal mass palpated on exam. Radiographs revealed a mid-abdominal mass without a defined origin. Doing well on appetite stimulants.

SPECIES

Feline Abnormal PE/Chem/CBC/UA Results: Bloodwork - Chem: inc BG, ALT 305; CBC - HCT 72%, Hg 23
Radiologist report: FINDINGS: Abdomen, July 9, 2023: 3 images (3 view study) are available for review.

BREED

DSH

SEX

Spayed Female

AGE

15 Years

WEIGHT

4.47 kg

The images are correctly labeled. The patient is adequately positioned and the pertinent anatomy is completely included. There is a continuous glucose monitoring device observed in the caudal thoracic left dorsolateral soft tissues. There is a large mass of lobulated appearance and undulating margins observed in the mid-abdomen ventrally. It results in displacement of the small intestinal loops caudally as well as caudal and right-sided displacement of the colon. The seventh sternebra is abnormally foreshortened and there is ventral deviation of the xiphoid. These findings are compatible with a congenital anatomic abnormality. There is a mild bronchial pattern observed in the visible portion of the pulmonary parenchyma. There are no significant findings in the abdominal wall soft tissues, visible skeletal structures, peritoneal cavity, gastrointestinal tract, liver, kidneys, urinary bladder, and visible portion of the thorax. CONCLUSIONS AND RECOMMENDATIONS: Large ventrally located mid-abdominal mass as described. The lesion may be originating from the ventral aspect of the spleen, from the pancreas, a lymph node, mesentery, or less likely from the intestinal tract. It may also represent a pedunculated hepatic mass. Neoplasia is the primary concern but the presence of a large pancreatic pseudocyst or a benign biliary cystadenoma cannot be ruled out. An abdominal ultrasound is recommended for further evaluation. The mild bronchial pulmonary pattern may be the result of age-related changes.

INTERPRETED BY ULTRASONOGRAPHIC EXAMINATION OF THE ABDOMEN

Eric Lindquist, DMV
DABVP, Cert. IVUSS

Urinary System

The **urinary bladder**, trigone, and pelvic urethra presented normal thicknesses and normal tone. The ureters were not visible which is normal. No uroliths or sediment were visualized and anechoic urine was present. No evidence of inflammatory or neoplastic changes were noted. Ureteral papillae were normal. The pelvic urethra was imaged 2.0 cm beyond the cystourethral junction.

IMAGING PERFORMED BY

Megan Odgers, VMD

HOSPITAL NAME

Pennsauken AH & UC

The **kidneys** revealed normal size and structure, corticomedullary definition and ratio for this age. The cortices presented largely uniform texture with normal echogenic relationship to liver and spleen. Medullary structure differed distinctly from the cortex and no evidence of pelvic dilation was present. The capsules were acceptably uniform without significant irregularities. The right kidney measured 4.16 cm. The left kidney measured 3.9 cm.

REFERRING VET

Katie Dorph

Adrenal Glands

Both **adrenal glands** were visualized and recognized as having normal shape, size, position and echogenicity for this breed. The phrenic vasculature, glandular echogenicity and detail were unremarkable. Capsule, cortex, and medullary definition were normal for this age patient. The right adrenal gland measured 0.22 cm. The left adrenal gland measured 0.2 cm.

INVOICE

23355

Spleen

DATE

7/14/23

The **spleen** presented a smooth homogeneous parenchyma hyperechoic to liver and renal cortical parenchyma. The capsule was smooth without noticeable expansion or deviation from within the



PATIENT

Iris Daly

spleen or adjacent pathology. The splenic vasculature demonstrated normal volume without signs of congestion or thrombosis. No sonographic evidence of acute or chronic inflammatory, neoplastic, or infarctual changes were noted.

SPECIES

Feline

Liver

The **liver** images submitted revealed subjectively normal liver size, contour, and structure. Parenchymal echogenicity was naturally coarse and hypoechoic to the spleen. Vascular and biliary tracts were of normal volume with no evidence of congestion. The gallbladder presented acceptably thin walls with primarily anechoic content. The cystic and common bile ducts were normal. No pathological hepatic lymphadenopathy was evident. No overt structural evidence of inflammatory, infiltrative or regenerative pathology was evident.

BREED

DSH

SEX

Spayed Female

Gastrointestinal

The **gastrointestinal** presentation revealed mild uniform prominence of the gastric mucosa as well as areas of "ropey" small intestinal wall with slight disruption of the normal 1:3 muscularis/mucosal ratio. The intestinal submucosa was slightly irregular, thickened and hyperechoic suggestive of low grade, chronic disease. No concerning lymphadenopathy was visible. No evidence of obstruction was present. Chronic inflammatory bowel disease is likely with a low possibility of an early neoplastic event such as lymphoma. Full thickness tissue biopsies via open laparotomy, ideally guided by intraoperative ultrasound in order to obtain the most representative mural sample, would be necessary to rule out this possibility. This is a mild change.

AGE

15 Years

WEIGHT

4.47 kg

Pancreas

The base and limbs of the **pancreas** were observed to be largely isoechoic to surrounding omental fat. Pancreatic duct and capsular contour were acceptably normal and parenchyma respected normal curvilinear patterns. No overt evidence of active inflammatory or neoplastic disease was noted.

INTERPRETED BY

Eric Lindquist, DMV
DABVP, Cert. IVUSS

Free Abdomen

The mid abdomen revealed a large **cystic structure** of unknown origin, that impinges upon the intestine. The cystic structure measured approximately 8.0 cm in width with echogenic debris.

IMAGING PERFORMED BY

Megan Odgers, VMD

Free fluid was noted in the abdomen, which would suggest potential cyst rupture.

HOSPITAL NAME

Pennsauken AH & UC

ULTRASONOGRAPHIC FINDINGS

- Mid abdominal cyst- omental or pancreatic is possible, abscessation is possible.
- Free fluid
- IBD GI pattern
- Nonspecific inflammatory hepatopathy given the patient history

REFERRING VET

Katie Dorph

INTERPRETATION OF THE FINDINGS & FURTHER RECOMMENDATIONS

INVOICE

I recommend exploratory surgery in this patient with removal or drainage of the large cystic structure. The exact origin of the cyst is unclear.

23355

DATE

7/14/23



PATIENT

Iris Daly

SPECIES

Feline

BREED

DSH

SEX

Spayed Female

AGE

15 Years

WEIGHT

4.47 kg

INTERPRETED BY

Eric Lindquist, DMV
DABVP, Cert. IVUSS

IMAGING PERFORMED BY

Megan Odgers, VMD

HOSPITAL NAME

Pennsauken AH & UC

REFERRING VET

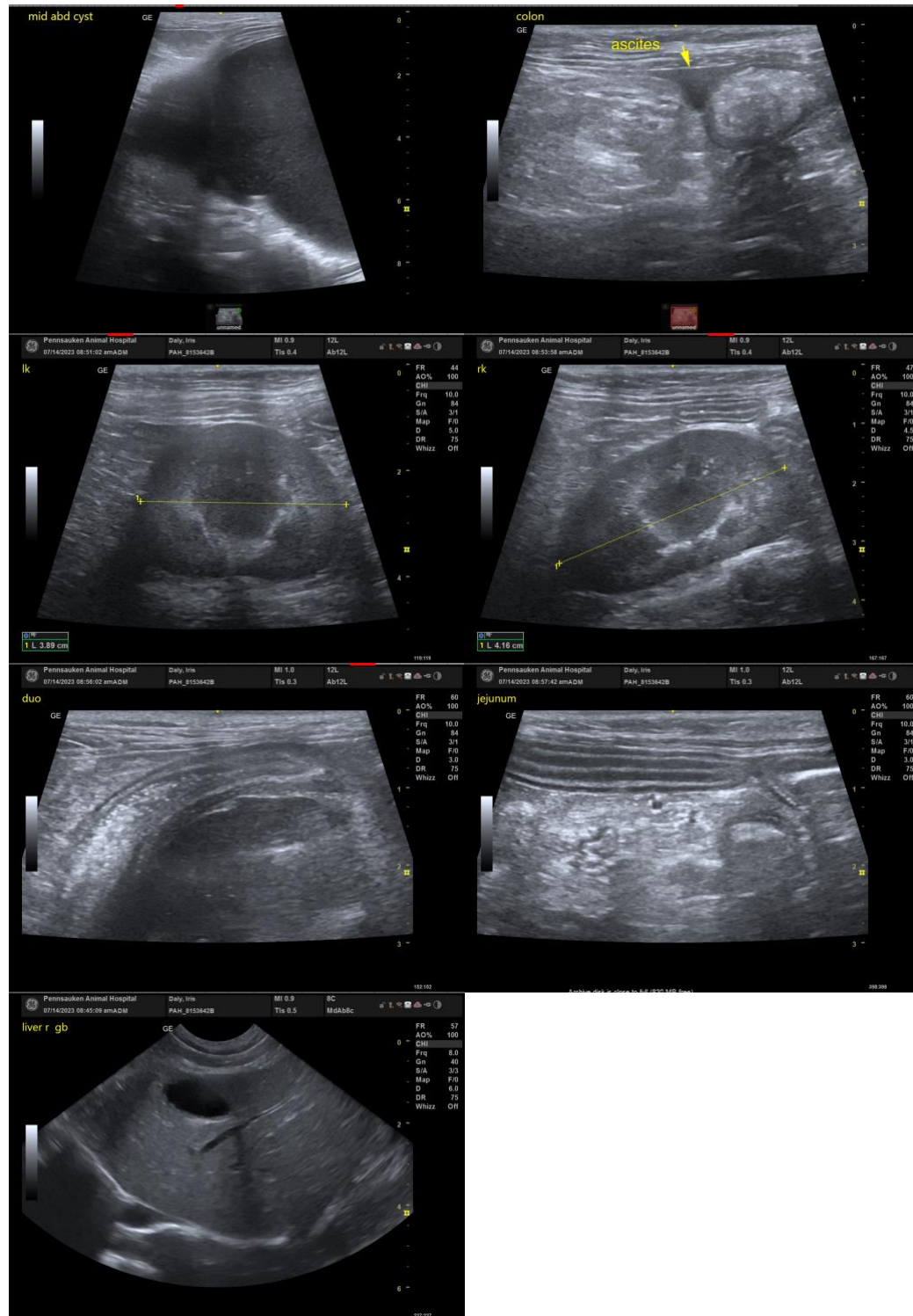
Katie Dorph

INVOICE

23355

DATE

7/14/23



The information and recommendations provided are based on the images presented by the referring veterinarian. No evaluation can be communicated regarding pathology that was not visible in the image/video clips provided.



PATIENT

Iris Daly

Thank you for this referral. If the clinical or image interpretation does not parallel your findings or if I can be of any further assistance please contact me.

SPECIES

Feline

Eric Lindquist, DMV, DABVP, Cert. IVUSS, CEO of SonoPath.com
info@SonoPath.com

BREED

DSH

SEX

Spayed Female

AGE

15 Years

WEIGHT

4.47 kg

INTERPRETED BY

Eric Lindquist, DMV
DABVP, Cert. IVUSS

**IMAGING
PERFORMED BY**

Megan Odgers, VMD

HOSPITAL NAME

Pennsauken AH & UC

REFERRING VET

Katie Dorph

INVOICE

23355

DATE

7/14/23