



<b>PATIENT</b>	<b>PRESENTING CLINICAL SIGNS</b>
Declan Krahenbuhl	Recurrent diarrhea - P repeatedly breaks with soft stools, improves on GI supportive care, dietary changes, but diarrhea soon recurs. Patient currently being fed Hill's I/D, previous trial with hydrolyzed food unsuccessful.
<b>SPECIES</b>	Abnormal PE/Chem/CBC/UA Results:      Recent lab panel in April 2023 unremarkable Texas A&M GI Panel pending
Canine	
<b>BREED</b>	<b>ULTRASONOGRAPHIC EXAMINATION OF THE ABDOMEN</b>
Beagle	<b>Urinary System</b>
<b>SEX</b>	The <b>urinary bladder</b> , trigone, and pelvic urethra presented normal thicknesses and normal tone. The ureters were not visible which is normal. No uroliths or sediment were visualized and anechoic urine was present. No evidence of inflammatory or neoplastic changes were noted. Ureteral papillae were normal. The pelvic urethra was imaged 2.0 cm beyond the cystourethral junction
Neutered Male	
<b>AGE</b>	The <b>kidneys</b> revealed normal size and structure, corticomedullary definition and ratio for this age. The cortices presented largely uniform texture with normal echogenic relationship to liver and spleen. Medullary structure differed distinctly from the cortex and no evidence of pelvic dilation was present. The capsules were acceptably uniform without significant irregularities. The right kidney measured 5.0 cm. The left kidney measured 4.4 cm.
12 Years	
<b>WEIGHT</b>	<b>Adrenal Glands</b>
28 Pounds	Both <b>adrenal glands</b> were visualized and recognized as having normal shape, size, position and echogenicity for this breed. The phrenic vasculature, glandular echogenicity and detail were unremarkable. Capsule, cortex, and medullary definition were normal for this age patient. The left adrenal gland measured 0.68 cm at the cranial pole and 0.66 cm at the caudal pole. The right adrenal gland measured 1.1 cm at the cranial pole and 0.45 cm at the caudal pole.
<b>INTERPRETED BY</b>	<b>Spleen</b>
Eric Lindquist, DMV DABVP, Cert. IVUSS	The <b>spleen</b> presented a smooth homogeneous parenchyma hyperechoic to liver and renal cortical parenchyma. The capsule was smooth without noticeable expansion or deviation from within the spleen or adjacent pathology. The splenic vasculature demonstrated normal volume without signs of congestion or thrombosis. No sonographic evidence of acute or chronic inflammatory, neoplastic, or infarctual changes were noted.
<b>IMAGING PERFORMED BY</b>	<b>Liver</b>
Jack Reese	The <b>liver</b> images submitted revealed subjectively normal liver size, contour, and structure. Parenchymal echogenicity was naturally coarse and hypoechoic to the spleen. Vascular and biliary tracts were of normal volume with no evidence of congestion. The gallbladder presented acceptably thin walls with primarily anechoic content. The cystic and common bile ducts were normal. No pathological hepatic lymphadenopathy was evident. No overt structural evidence of inflammatory, infiltrative or regenerative pathology was evident.
<b>HOSPITAL NAME</b>	
Willow Run VC	
<b>REFERRING VET</b>	<b>Gastrointestinal</b>
Dr. Molly Arnold	Examination of the <b>gastrointestinal tract</b> revealed a stomach and intestine free of stasis, of normal wall thickness, acceptable curvilinear mural detail, and peristaltic activity. Small and large intestine
<b>INVOICE</b>	
23397	
<b>DATE</b>	
7/14/23	



## PATIENT

Declan Krahenbuhl

demonstrated normal luminal chyme and stool consistency respectively. No obstructive or overt infiltrative disease was noted. No associated abnormal lymphatic activity was noted.

## Pancreas

## SPECIES

Canine

The base and limbs of the **pancreas** were observed to be largely isoechoic to surrounding omental fat. Pancreatic duct and capsular contour were acceptably normal and parenchyma respected normal curvilinear patterns. No overt evidence of active inflammatory or neoplastic disease was noted.

## BREED

Beagle

## ULTRASONOGRAPHIC FINDINGS

- Structurally unremarkable abdomen

## SEX

Neutered Male

## INTERPRETATION OF THE FINDINGS & FURTHER RECOMMENDATIONS

Differentials for diarrhea include occult parasitism. Dietary indiscretion, dietary intolerance, antibiotic responsive colitis, intestinal dysbiosis and occult Addison's should all be considered as causes of diarrhea in this patient. A hydrolyzed diet trial may be in this patient's best interest +/- probiotics. 24-hour NPO and reintroduction of bland diet indicated. I recommend a baseline cortisol or ACTH stimulation test, a fresh fecal smear and fecal floatation analysis if not already performed.

## AGE

12 Years

## WEIGHT

28 Pounds

## INTERPRETED BY

Eric Lindquist, DMV  
DABVP, Cert. IVUSS

## IMAGING PERFORMED BY

Jack Reese

## HOSPITAL NAME

Willow Run VC

## REFERRING VET

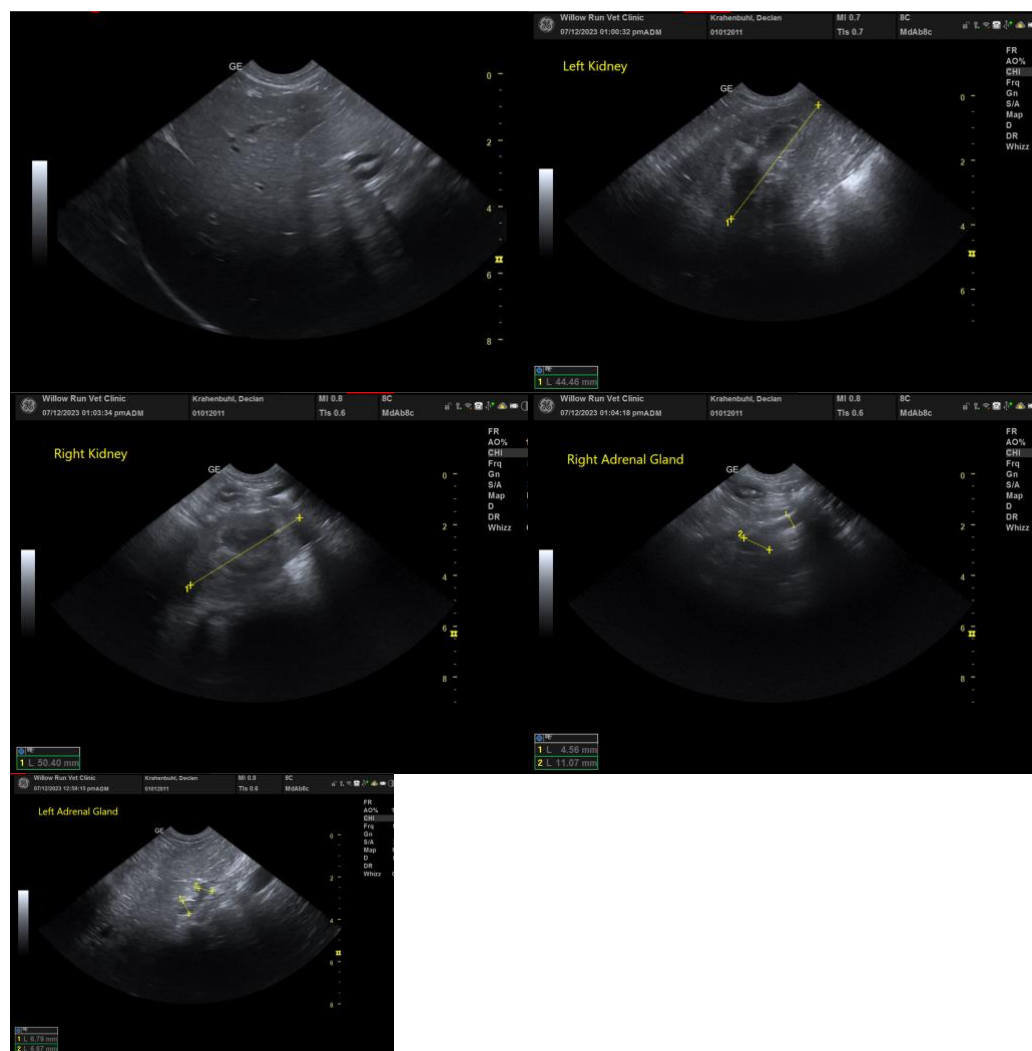
Dr. Molly Arnold

## INVOICE

23397

## DATE

7/14/23





**PATIENT**

Declan Krahenbuhl

**SPECIES**

Canine

**The information and recommendations provided are based on the images presented by the referring veterinarian. No evaluation can be communicated regarding pathology that was not visible in the image/video clips provided.**

**BREED**

Beagle

Thank you for this referral. If the clinical or image interpretation does not parallel your findings or if I can be of any further assistance please contact me.

**SEX**

Neutered Male

**Eric Lindquist**, DMV, DABVP, Cert. IVUSS, CEO of SonoPath.com  
info@SonoPath.com

**AGE**

12 Years

**WEIGHT**

28 Pounds

**INTERPRETED BY**

Eric Lindquist, DMV  
DABVP, Cert. IVUSS

**IMAGING  
PERFORMED BY**

Jack Reese

**HOSPITAL NAME**

Willow Run VC

**REFERRING VET**

Dr. Molly Arnold

**INVOICE**

23397

**DATE**

7/14/23