



PATIENT

Cooper Papcun

SPECIES

Canine

BREED

GSP

SEX

Neutered Male

AGE

11

WEIGHT

50

INTERPRETED BY

Eric Lindquist, DMV
DABVP, Cert. IVUSS

IMAGING PERFORMED BY

Torch River VMS

HOSPITAL NAME

TLVC

REFERRING VET

Dr. Waffle

INVOICE

23384

DATE

7/14/23

PRESENTING CLINICAL SIGNS

History of anorexia, vomiting, and weight loss for 1 week duration. owner began feeding chicken and rice, which patient has been eating well. Patient will vomit 6-8 hours after eating

Abnormal PE/Chem/CBC/UA Results: CBC/CHem - unremarkable 4DX - negative Chest/abdominal rads - unremarkable cPL - normal

ULTRASONOGRAPHIC EXAMINATION OF THE ABDOMEN

Urinary System

The **urinary bladder**, trigone, and pelvic urethra presented normal thicknesses and normal tone. The ureters were not visible which is normal. No uroliths or sediment were visualized and anechoic urine was present. No evidence of inflammatory or neoplastic changes were noted. Ureteral papillae were normal.

The **kidneys** revealed normal size and structure, corticomedullary definition and ratio for this age. The cortices presented largely uniform texture with normal echogenic relationship to liver and spleen. Medullary structure differed distinctly from the cortex and no evidence of pelvic dilation was present. The capsules were acceptably uniform without significant irregularities. The left kidney measured 5.77 cm. The right kidney measured 6.24 cm.

Adrenal Glands

Both **adrenal glands** were visualized and recognized as having normal shape, size, position and echogenicity for this breed. The phrenic vasculature, glandular echogenicity and detail were unremarkable. Capsule, cortex, and medullary definition were normal for this age patient. The right adrenal gland measured 0.74 cm at the caudal pole and 1.3 cm at the cranial pole. The left adrenal gland measured 2.18 cm x 0.73 cm at the cranial pole and 0.74 cm at the caudal pole.

Spleen

The **spleen** presented a smooth homogeneous parenchyma hyperechoic to liver and renal cortical parenchyma. The capsule was smooth without noticeable expansion or deviation from within the spleen or adjacent pathology. The splenic vasculature demonstrated normal volume without signs of congestion or thrombosis. No sonographic evidence of acute or chronic inflammatory, neoplastic, or infarctual changes were noted. Cranial folding of the spleen was noted.

Liver

The **liver** images submitted revealed subjectively normal liver size, contour, and structure. Parenchymal echogenicity was naturally coarse and hypoechoic to the spleen. Vascular and biliary tracts were of normal volume with no evidence of congestion. The gallbladder presented acceptably thin walls with primarily anechoic content. The cystic and common bile ducts were normal. No pathological hepatic lymphadenopathy was evident. No overt structural evidence of inflammatory, infiltrative or regenerative pathology was evident.

Gastrointestinal

The **stomach** was significantly thickened in this patient with wall thickness up to 2.0 cm. Some loss of mural detail was noted. Gastric fundic fluid was noted. The small intestine and colon were unremarkable. Reactive mesentery was noted around the stomach.



PATIENT

Pancreas

Cooper Papcun

The base and limbs of the **pancreas** were observed to be largely isoechoic to surrounding omental fat. Pancreatic duct and capsular contour were acceptably normal and parenchyma respected normal curvilinear patterns. No overt evidence of active inflammatory or neoplastic disease was noted.

SPECIES

Canine

ULTRASONOGRAPHIC FINDINGS

- Gastritis pattern with potential emerging gastric neoplasia
- Unremarkable abdomen otherwise

BREED

GSP

INTERPRETATION OF THE FINDINGS & FURTHER RECOMMENDATIONS

SEX

Gastroscopy is warranted to obtain mucosal biopsies or full thickness gastric biopsies. Prognosis is guarded depending upon histopathology results.

Neutered Male

AGE

11

WEIGHT

50

INTERPRETED BY

Eric Lindquist, DMV
DABVP, Cert. IVUSS

IMAGING PERFORMED BY

Torch River VMS

HOSPITAL NAME

TLVC

REFERRING VET

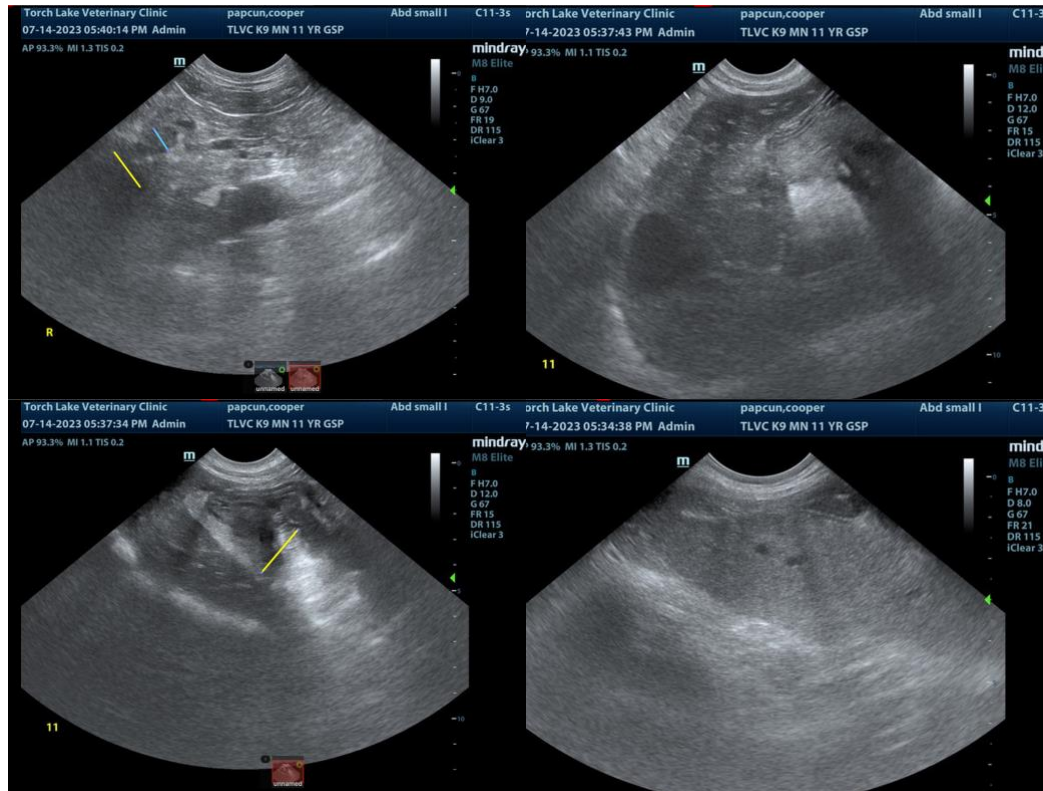
Dr. Waffle

INVOICE

23384

DATE

7/14/23





PATIENT

Cooper Papcun

SPECIES

Canine

BREED

GSP

SEX

Neutered Male

AGE

11

WEIGHT

50

INTERPRETED BY

Eric Lindquist, DMV
DABVP, Cert. IVUSS

IMAGING PERFORMED BY

Torch River VMS

HOSPITAL NAME

TLVC

REFERRING VET

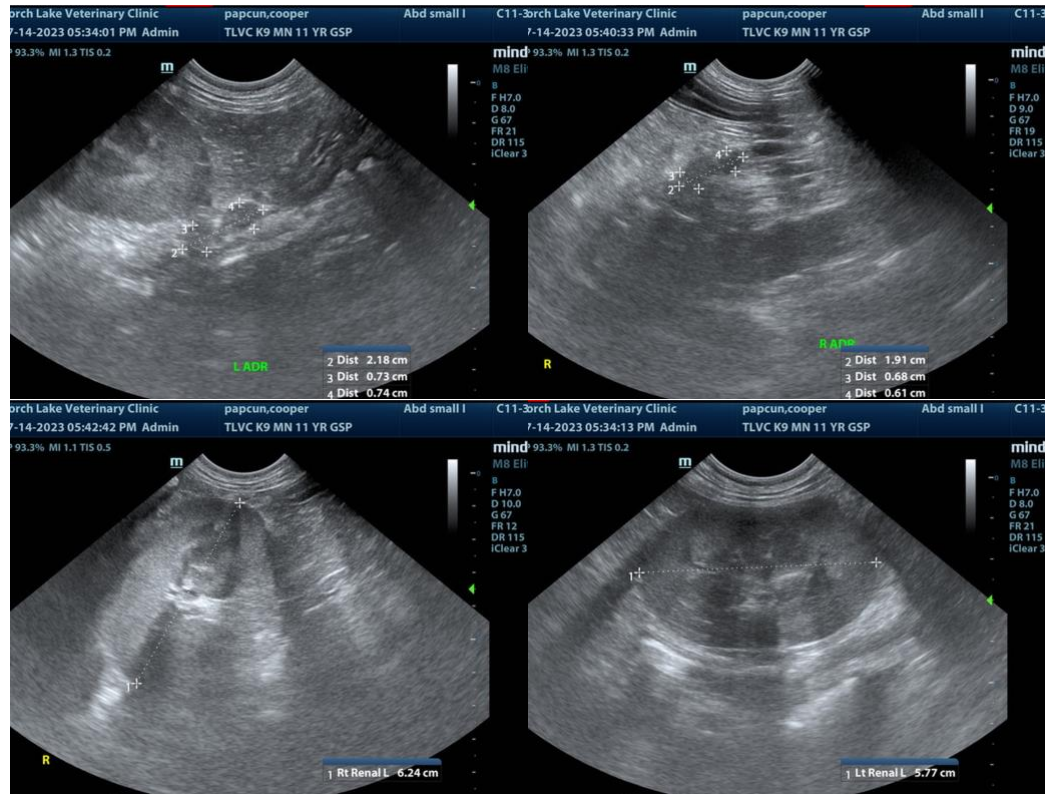
Dr. Waffle

INVOICE

23384

DATE

7/14/23



The information and recommendations provided are based on the images presented by the referring veterinarian. No evaluation can be communicated regarding pathology that was not visible in the image/video clips provided.

Thank you for this referral. If the clinical or image interpretation does not parallel your findings or if I can be of any further assistance please contact me.

Eric Lindquist, DMV, DABVP, Cert. IVUSS, CEO of SonoPath.com
info@SonoPath.com