



PATIENT

Sgt. Pepper Renaud

SPECIES

Canine

BREED

Chihuahua

SEX

Neutered male

AGE

11 years

WEIGHT

11.1 lbs

INTERPRETED BY

Eric Lindquist, DMV
DABVP, Cert. IVUSS

IMAGING PERFORMED BY

Dr. Bailes

HOSPITAL NAME

All Creatures Great
and Small

REFERRING VET

Dr. Bailes

PRESENTING CLINICAL SIGNS

Hx of stage B1 valvular disease; currently receiving vetmedin and enalapril. recently patient has started coughing but improved w/ doxycycline. SRR has been WNL in the 20's.

Abnormal PE/Chem/CBC/UA Results: grade 3-4/6 systolic murmur, obese, otherwise NSF on PE
Blood pressure today: 110 systolic.

ULTRASONOGRAPHIC EXAMINATION OF THE HEART

The echocardiogram in this patient demonstrated normal **left atrial** size based on 3 separate methods of LA evaluation. **Mitral** valve insufficiency was noted on pulse wave and color flow Doppler. The **left ventricle** presented thicknesses with linear contour and was not dilated nor restricted. The **myocardium** presented normal echogenicity without subjective evidence of significant fibrotic or ischemic disease. **Contractility** of the ventricular walls was adequate and in normal range for this patient evidenced by the fractional shortening measurement and subjective evaluation of the different regions of the myocardium. The **left ventricular outflow** tract demonstrated normal laminar flow and subjective structural integrity. The **right atrium** and auricle revealed normal size, structure and content. No evidence of masses was noted. **Tricuspid** insufficiency was noted. The **right ventricle** was of normal size (1/3 diameter of LV), chordae structure, myocardial echogenicity and thickness. **Pulmonary outflow** tract assessment revealed normal valve structure, laminar flow, and diameter (approx. 1:1 pa/ao ratio). No visible **pericardial** or free pleura fluid was noted. The cranial **mediastinum and pericardial and extra-cardiac regions** were free of masses in the visible window.

CANINE CARDIAC PARAMETERS	MR VMAX (m/s)	TR VMAX (m/s)	LA/AO (Boon method)	LA/AO (Heart Base; Swe)	FS (%)	EF (%)	EPSS (cm)
NORMAL PARAMETER	4.5-5.5	<2.7	1.3	<1.6	28-40	40-100	<0.6
PATIENT		2.59	1.2	1.7	53	86	0.1
CANINE CARDIAC PARAMETERS	HR (BPM)	AV VMAX (m/s)	PV MAX (m/s)	BODY WEIGHT	LA 2D short axis Base view (cm)	LVIDd Avg; 2D and m- mode short axis (cm)	LVIDs Avg; 2D and m- mode short axis (cm)
NORMAL PARAMETER	50-100	0.7-1.7	0.7-1.6	BELOW	BELOW	BELOW	BELOW
PATIENT		1.5	0.74	11.1	2.3	2.48	

INVOICE

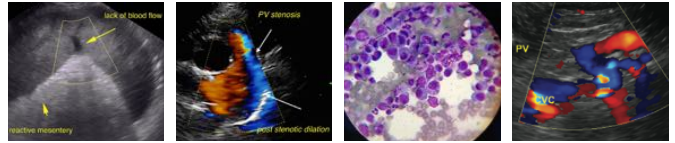
31689

DATE

7/14/22

ULTRASONOGRAPHIC FINDINGS

Compensated mitral insufficiency.



PATIENT

Sgt. Pepper Renaud

SPECIES

Canine

BREED

Chihuahua

SEX

Neutered male

AGE

11 years

WEIGHT

11.1 lbs

INTERPRETED BY

Eric Lindquist, DMV
DABVP, Cert. IVUSS

IMAGING PERFORMED BY

Dr. Bailes

HOSPITAL NAME

All Creatures Great and Small

REFERRING VET

Dr. Bailes

INVOICE

31689

DATE

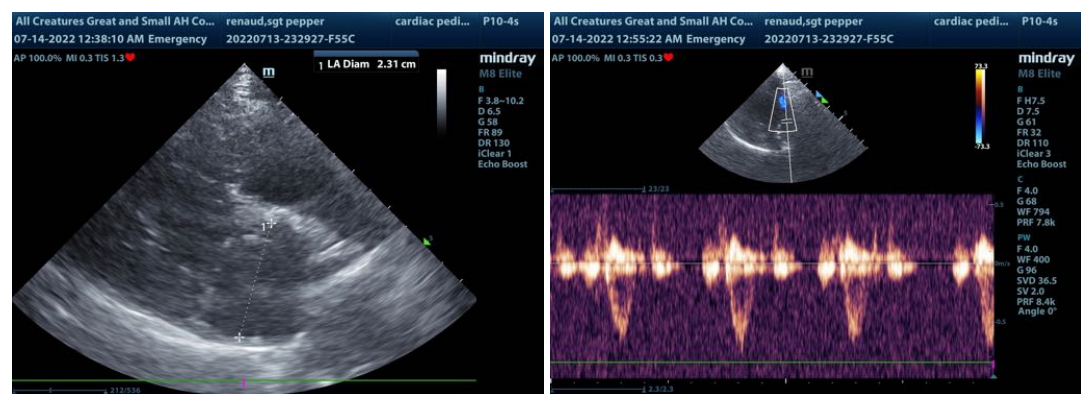
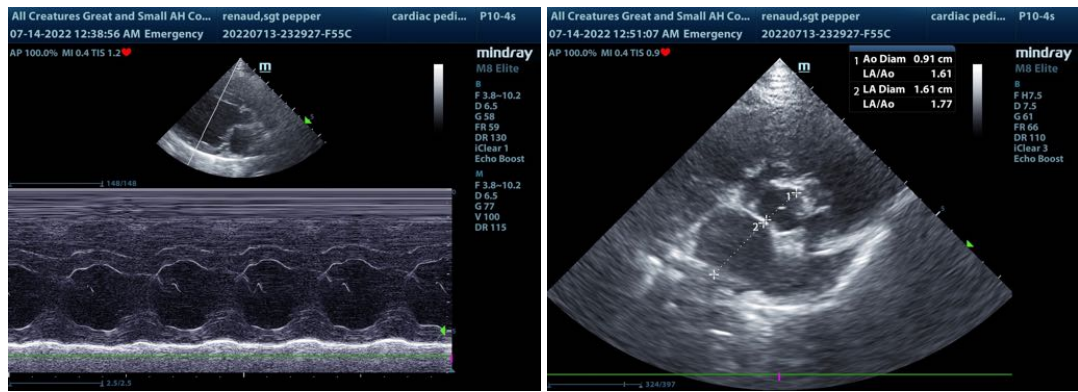
7/14/22

INTERPRETATION OF THE FINDINGS & FURTHER RECOMMENDATIONS

There was no significant progression from the prior sonogram. The cough is non-cardiogenic. Unless left atrial enlargement has been established, then there is no indication of Vetmedin at this time. Enalapril can be utilized if history of elevated systolic pressure was present. However, there was no volume overload at this time.

The heart is stable without clinical disease. No overt contraindication for anesthesia of brief to moderate duration. I suggest Torbutrol premed, Propofol induction, Isoflor maintenance or similar protocol if anesthesia is desired. Blood pressure recommended if not already performed and target white coat negative systolic pressure of < 160 mmHg. If higher than this ACE-inhibitor is suggested to reach this level. Recheck echocardiogram is recommended in 6 months, earlier if murmur grade increases or clinical signs initiate.

***In the future please send in DICOM format.





PATIENT

Sgt. Pepper Renaud

SPECIES

Canine

BREED

Chihuahua

SEX

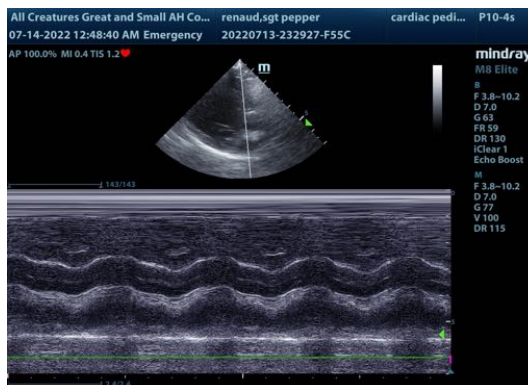
Neutered male

AGE

11 years

WEIGHT

11.1 lbs



The information and recommendations provided are based on the images presented by the referring veterinarian/sonographer. No evaluation can be communicated regarding pathology that was not visible in the image/video clips provided.

Thank you for this referral. If the clinical or image interpretation does not parallel your findings or if I can be of any further assistance please contact me.

Eric Lindquist, DMV, DABVP, Cert. IVUSS, CEO of SonoPath.com
info@SonoPath.com

INTERPRETED BY

Eric Lindquist, DMV
DABVP, Cert. IVUSS

IMAGING PERFORMED BY

Dr. Bailes

HOSPITAL NAME

All Creatures Great
and Small

REFERRING VET

Dr. Bailes

INVOICE

31689

DATE

7/14/22