



PATIENT

Captain Baston

SPECIES

Canine

BREED

Pomeranian

SEX

Male

AGE

6 years

WEIGHT

2.85 lbs

INTERPRETED BY

Eric Lindquist, DMV
DABVP, Cert. IVUSS

IMAGING PERFORMED BY

Dr. Bell

HOSPITAL NAME

Cedarview AH

REFERRING VET

Dr. Bell

INVOICE

31691

DATE

7/14/22

PRESENTING CLINICAL SIGNS

History: Chronic intermittent bleeding from penis. Recently finished a course of baytril, no previous imaging. Seems to have improved since course of antibiotics. Irritation at tip of penis, possibly tiny prolapse?

Abnormal PE/Chem/CBC/UA Results: Urinalysis was done at rDVM prior to abx use. NSF urine.

ULTRASONOGRAPHIC EXAMINATION OF THE ABDOMEN

Urinary System

The **urinary bladder**, trigone, and pelvic urethra presented normal thicknesses and normal tone. The ureters were not visible which is normal. No uroliths or sediment were visualized and anechoic urine was present. No evidence of inflammatory or neoplastic changes was noted. Ureteral papillae were normal.

The prostate was mildly heterogenous and measured 2.0 cm. The prostate had coarse architecture and minor deviation of the descending colon. The testicles were imaged and found to be fairly uniform with minor heterogenous changes.

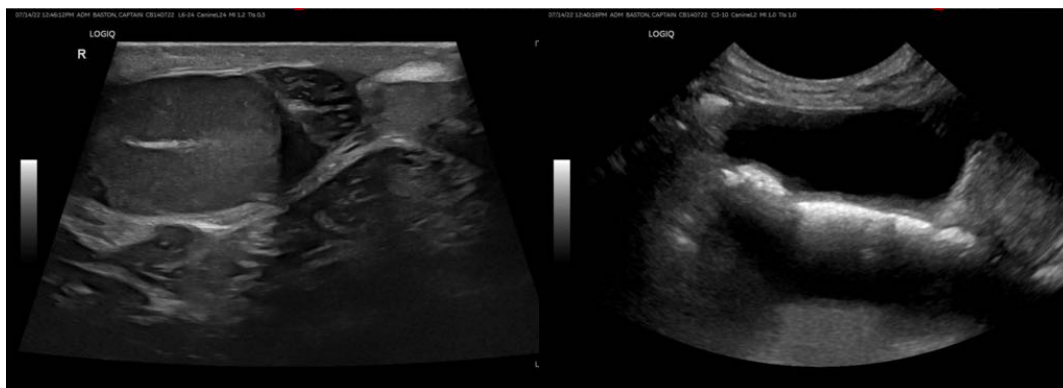
ULTRASONOGRAPHIC FINDINGS

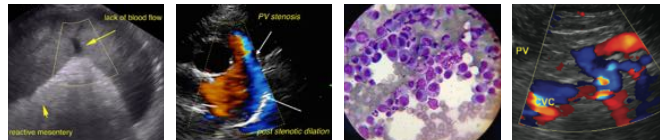
Chronic prostatitis pattern.

INTERPRETATION OF THE FINDINGS & FURTHER RECOMMENDATIONS

FNA of the prostate, culture and cytology is warranted. I recommend neutering with treatment for prostatitis should prove effective. Otherwise, alternative protocol such as the following can be considered if neutering is not an option.

Finasteride at 1 mg/kg/day can be utilized as an off-label approach to reducing prostatic size in BPH cases. Coverage for prostatitis would also likely be appropriate with Fluoroquinolone/Baytril or similar. A recheck sonogram is recommended in 3-4 weeks with reassessment of the urinalysis and evaluation of any inflammatory sediment.





PATIENT

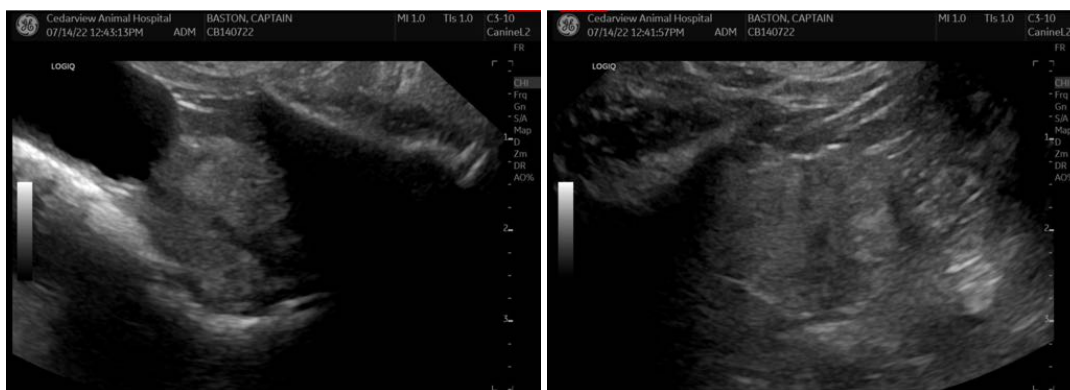Captain Baston

SPECIES

Canine

BREED

Pomeranian



SEX

Male

AGE

6 years

WEIGHT

2.85 lbs

The information and recommendations provided are based on the images presented by the referring veterinarian/sonographer. No evaluation can be communicated regarding pathology that was not visible in the image/video clips provided.

Thank you for this referral. If the clinical or image interpretation does not parallel your findings or if I can be of any further assistance please contact me.

Eric Lindquist, DMV, DABVP, Cert. IVUSS, CEO of SonoPath.com
info@SonoPath.com

INTERPRETED BY

Eric Lindquist, DMV
DABVP, Cert. IVUSS

IMAGING PERFORMED BY

Dr. Bell

HOSPITAL NAME

Cedarview AH

REFERRING VET

Dr. Bell

INVOICE

31691

DATE

7/14/22