



PATIENT

Spyra Dotson

SPECIES

Reptile

BREED

Bearded Dragon

SEX

Femal

AGE

4 Years

WEIGHT

539 g

INTERPRETED BY

Eric Lindquist, DMV

DABVP, Cert. IVUSS

IMAGING PERFORMED BY

Dr. J Jill Heatley

HOSPITAL NAME

All Pets Medical Center

REFERRING VET

Dr. J Jill Heatley

INVOICE

43847

DATE

7/13/23

PRESENTING CLINICAL SIGNS

Cloacal prolapse, Inflamed vent, good appetite but persistent constipation/ poor fecal production. CBC: leukocytosis 23,000 K heterophilia with toxic change; Chemistry abnormalities limited to increased Ca > 18.2 mg/dL. And low uric acid/ albumin. Radiographs are without abnormalities of the lungs or MS systems. DDX: Preovulatory oostasis, ovarian neoplasia, Liver neoplasia or metabolic disease

ULTRASONOGRAPHIC EXAMINATION OF THE ABDOMEN

Kidneys

The **kidneys** were uniform, no evident pathology.

Liver

The **liver** was normal in size and contour. Parenchyma was uniform. The gallbladder and common bile duct were unremarkable. Normal hepatic vein volume.

Gastrointestinal

The **gastrointestinal tract** revealed chronic small intestinal mucosal changes consistent with remodeling. Chronic inflammatory disease likely. The pylorus was free of evident pathology. Colorectal tissue was slightly thickened, similar to the pattern in the remainder of the small intestine.

Other

Trace amounts of free fluid noted, yet not evidence of pathology.

Heart

The heart was imaged in this patient with normal contractility and volumes. No evidence of disease. Normal A-lines noted in the extra cardiac space. No evidence of extracardiac disease. Trace free fluid noted, matching that of the abdomen.

ULTRASONOGRAPHIC FINDINGS

- Chronic mucosal intestinal remodeling – chronic inflammatory disease likely.
- Free fluid – possibly owing to wasting.

INTERPRETATION OF THE FINDINGS & FURTHER RECOMMENDATIONS

No neoplasia criteria present in any of the organ systems. No evidence of obstructive disease.



PATIENT

Spyra Dotson

SPECIES

Reptile

BREED

Bearded Dragon

SEX

Femal

AGE

4 Years

WEIGHT

539 g

INTERPRETED BY

Eric Lindquist, DMV
DABVP, Cert. IVUSS

IMAGING PERFORMED BY

Dr. J Jill Heatley

HOSPITAL NAME

All Pets Medical Center

REFERRING VET

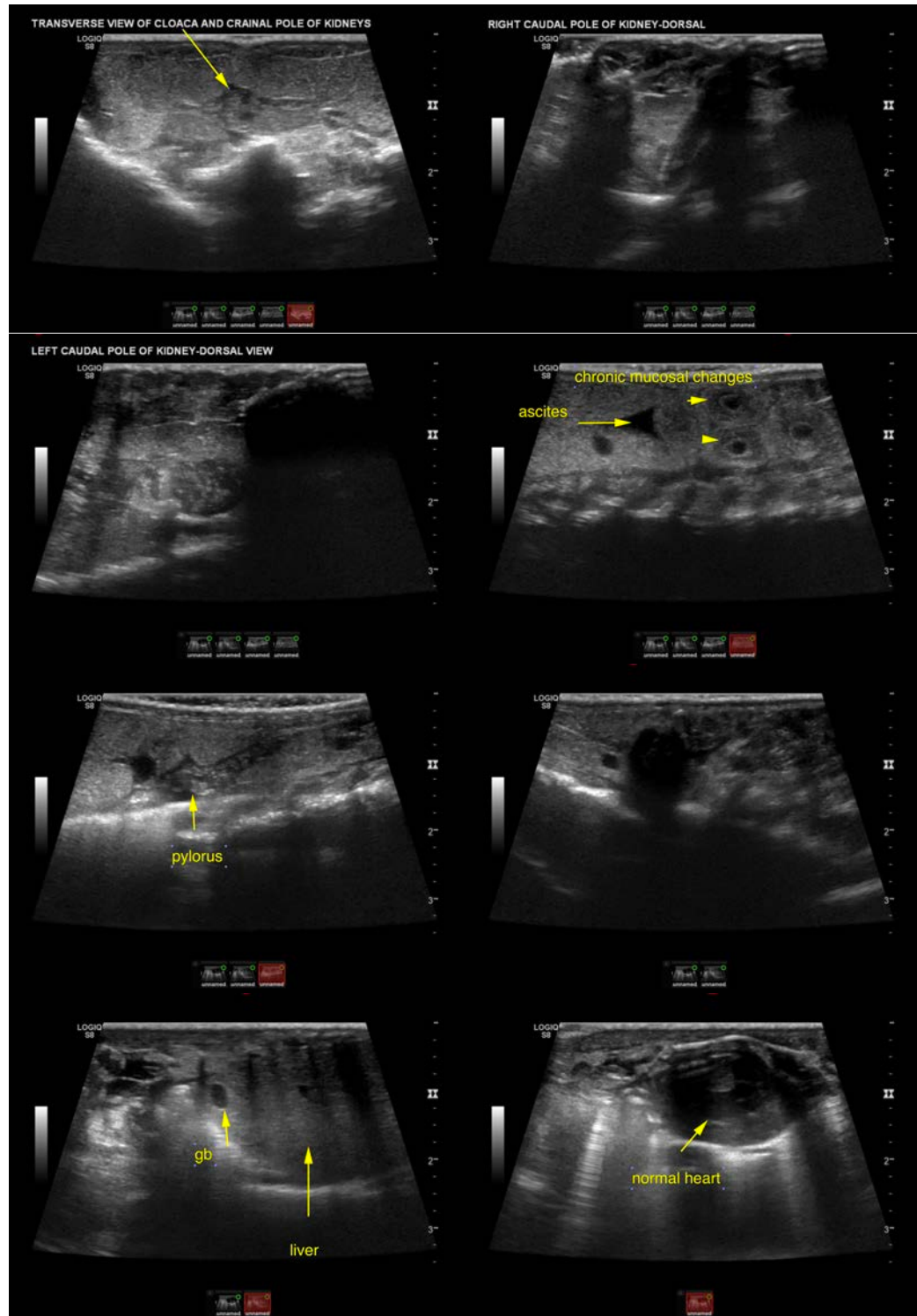
Dr. J Jill Heatley

INVOICE

43847

DATE

7/13/23





PATIENT

Spyra Dotson

The information and recommendations provided are based on the images presented by the referring veterinarian/sonographer. No evaluation can be communicated regarding pathology that was not visible in the image/video clips provided.

SPECIES

Reptile

Thank you for this referral. If the clinical or image interpretation does not parallel your findings or if I can be of any further assistance please contact me.

BREED

Bearded Dragon

Eric Lindquist, DMV, DABVP, Cert. IVUSS, CEO of SonoPath.com

info@SonoPath.com

SEX

Femal

AGE

4 Years

WEIGHT

539 g

INTERPRETED BY

Eric Lindquist, DMV

DABVP, Cert. IVUSS

IMAGING PERFORMED BY

Dr. J Jill Heatley

HOSPITAL NAME

All Pets Medical Center

REFERRING VET

Dr. J Jill Heatley

INVOICE

43847

DATE

7/13/23