

PATIENT

Noel Burnell

PRESENTING CLINICAL SIGNS

History: Lethargic. Will only eat after given famotidine. Chronic kidney disease Current Medications Famotidine, Methimazole TDG

SPECIES

Feline

ULTRASONOGRAPHIC EXAMINATION OF THE ABDOMEN

Urinary System

BREED

DSH

The **urinary bladder** revealed a 1.0 cm mineralizing mass deriving from the trigone of the bladder. The mineralizing mass in the bladder was concentric and nonresectable. Multifocal areas of mineralization were noted, strongly suggestive for carcinoma, The mass appeared to enter into the pelvic urethra. Concurrent bladder calculi were also noted.

SEX

Spayed Female

Moderate hydronephrosis (1.5 cm) was noted in the **left kidney**. The left kidney measured 3.35 cm. Moderate chronic degenerative changes were noted. Left ureteral dilation was noted up to 5.0 mm, owing to the bladder mass obstructive nature. Dilated pelvis was also noted in the **right kidney** with cortical medullary calculi.

AGE

15 Years

Adrenal Glands

The **adrenal glands** were uniform, yet bilaterally swollen and hypoechoic. This is most consistent with stress-induced hyperplasia. The left adrenal gland measured 1.1 cm x 0.58 cm. The right adrenal gland measured 0.59 cm.

WEIGHT

5.8 Pounds

Spleen

The **spleen** presented a smooth homogeneous parenchyma hyperechoic to liver and renal cortical parenchyma. The capsule was smooth without noticeable expansion or deviation from within the spleen or adjacent pathology. The splenic vasculature demonstrated normal volume without signs of congestion or thrombosis. No sonographic evidence of acute or chronic inflammatory, neoplastic, or infarctual changes were noted.

INTERPRETED BY

Eric Lindquist, DMV, DABVP, Cert. IVUSS

Liver

A cystadenomatous expansive 3.6 cm mass was noted, occupying the left medial **liver**. The gallbladder and common bile duct were unremarkable.

HOSPITAL NAME

West Salem AC

Gastrointestinal

The **gastrointestinal** presentation revealed mild uniform prominence of the gastric mucosa as well as areas of "ropey" small intestinal wall with slight disruption of the normal 1:3 muscularis/mucosal ratio. The intestinal submucosa was slightly irregular, thickened and hyperechoic suggestive of low grade, chronic disease. No concerning lymphadenopathy was visible. No evidence of obstruction was present. Chronic inflammatory bowel disease is likely with a low possibility of an early neoplastic event such as lymphoma. Full thickness tissue biopsies via open laparotomy, ideally guided by intraoperative ultrasound in order to obtain the most representative mural sample, would be necessary to rule out this possibility. Intestinal wall thickness measured up to 2.0 cm.

REFERRING VET

Dr. Sirianni

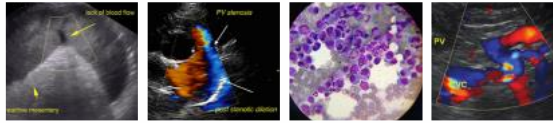
INVOICE NUMBER

23342

Pancreas

DATE

7/13/23



PATIENT Noel Burnell
The base and limbs of the **pancreas** were observed to be largely isoechoic to surrounding omental fat. Pancreatic duct and capsular contour were acceptably normal and parenchyma respected normal curvilinear patterns. No overt evidence of active inflammatory or neoplastic disease was noted.

SPECIES **ULTRASONOGRAPHIC FINDINGS**

- Feline
- Hydronephrotic left kidney owing to obstructive concentric bladder mass.
 - Moderate degenerative renal changes
 - Age-related hepatic changes with cystadenomatous type lesion
- BREED**
- IBD GI pattern

DSH **INTERPRETATION OF THE FINDINGS & FURTHER RECOMMENDATIONS**

SEX Spayed Female
Referral for potential ureteral/renal stent placement or SUB device. Prognosis is guarded to poor depending upon the ability for palliative interventional procedures.

AGE 15 Years

WEIGHT 5.8 Pounds

INTERPRETED BY

Eric Lindquist, DMV, DABVP, Cert. IVUSS

HOSPITAL NAME

West Salem AC

REFERRING VET

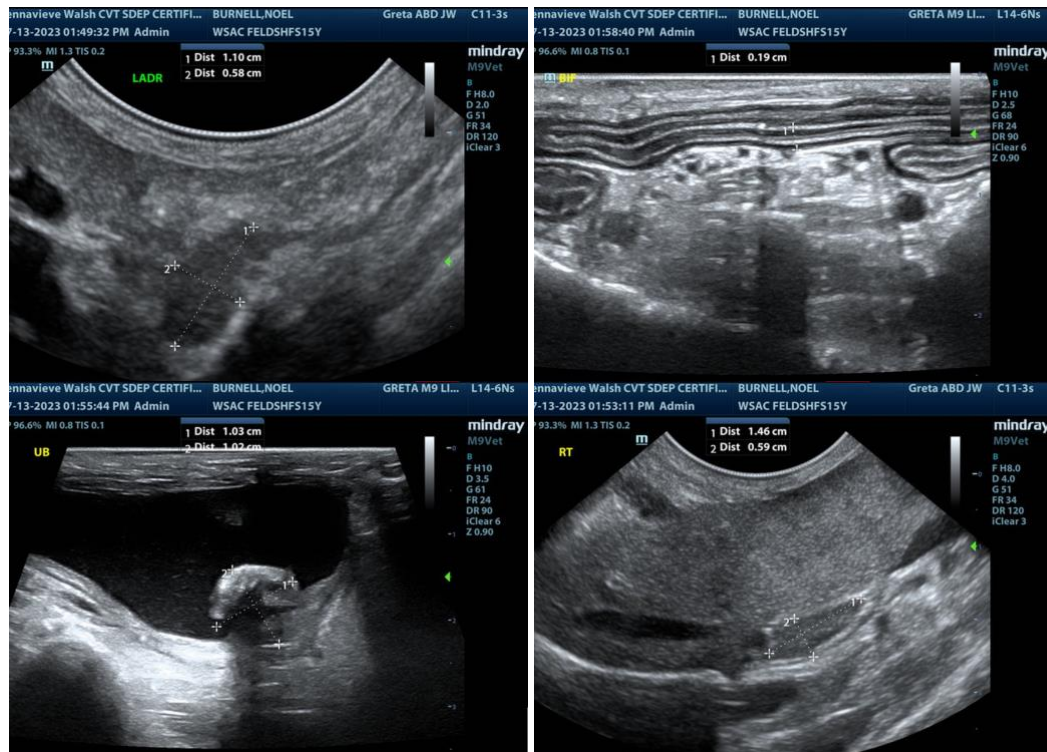
Dr. Sirianni

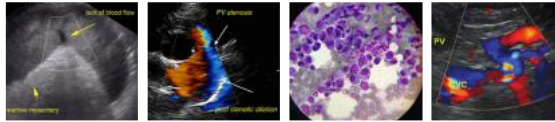
INVOICE NUMBER

23342

DATE

7/13/23





PATIENT

Noel Burnell

SPECIES

Feline

BREED

DSH

SEX

Spayed Female

AGE

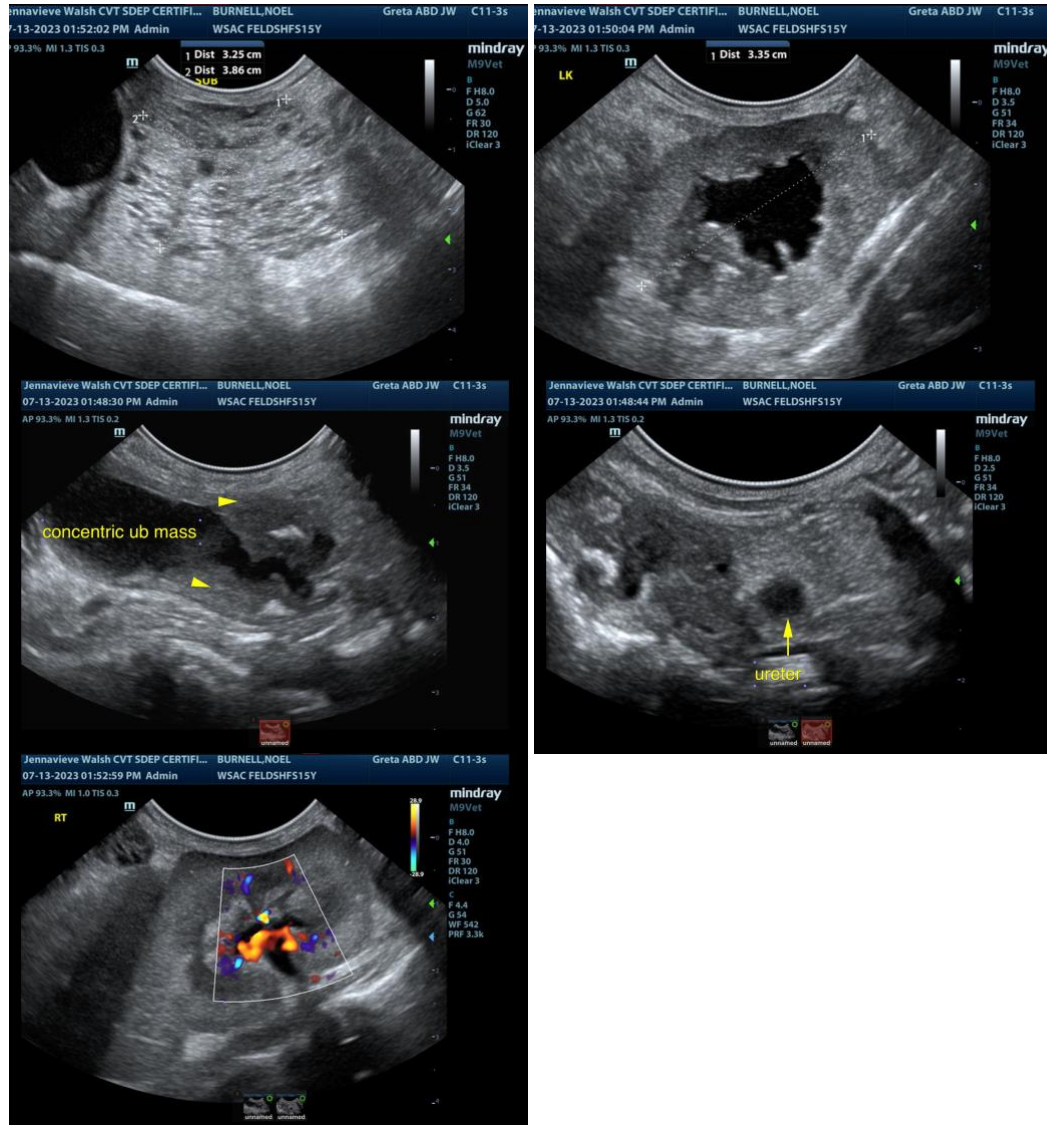
15 Years

WEIGHT

5.8 Pounds

INTERPRETED BY

Eric Lindquist, DMV,
DABVP, Cert. IVUSS



HOSPITAL NAME

West Salem AC

REFERRING VET

Dr. Sirianni

The information and recommendations provided are based on the images presented by the referring veterinarian. No evaluation can be communicated regarding pathology that was not visible in the image/video clips provided.

Thank you for this referral. If the clinical or image interpretation does not parallel your findings or if I can be of any further assistance please contact me.

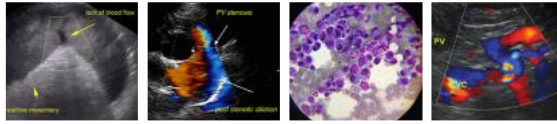
Eric Lindquist, DMV, DABVP, Cert. IVUSS, CEO of SonoPath.com
info@SonoPath.com

INVOICE NUMBER

23342

DATE

7/13/23



PATIENT

Noel Burnell

SPECIES

Feline

BREED

DSH

SEX

Spayed Female

AGE

15 Years

WEIGHT

5.8 Pounds

INTERPRETED BY

Eric Lindquist, DMV,
DABVP, Cert. IVUSS

HOSPITAL NAME

West Salem AC

REFERRING VET

Dr. Sirianni

INVOICE NUMBER

23342

DATE

7/13/23