

PATIENT

Marley Johnson

SPECIES

Canine

BREED

Boston Terrier

SEX

Spayed Female

AGE

6 Years

WEIGHT

19 Pounds

INTERPRETED BY

Eric Lindquist, DMV,
DABVP, Cert. IVUSS

HOSPITAL NAME

West Eugene AH

REFERRING VET

Dr. Sundholm

INVOICE NUMBER

23339

DATE

7/13/23

PRESENTING CLINICAL SIGNS

Marley presented on 7/7/23 for a routine wellness visit. Her physical exam was unremarkable. She has been on prednisone 3 times weekly (M/W/F) long term for IBD. The prednisone was started about 1 year ago. Her IBD symptoms seem well-controlled. Screening wellness bloodwork found changes in liver values. She has a history of seizures that are well controlled on levetiracetam.

Abnormal PE/Chem/CBC/UA Results: ABNORMAL Laboratory Findings ALT (1798); ALP (186); TBIL (0.4); Previous BW done June 2022 had normal liver values. Current Medications prednisone, levetiracetam; denamarin started 7/11/23 Radiographic Findings none taken

ULTRASONOGRAPHIC EXAMINATION OF THE ABDOMEN

Urinary System

The **urinary bladder**, trigone, and pelvic urethra presented normal thicknesses and normal tone. The ureters were not visible which is normal. No uroliths or sediment were visualized and anechoic urine was present. No evidence of inflammatory or neoplastic changes were noted. Ureteral papillae were normal. The pelvic urethra was imaged 2.0 cm beyond the cystourethral junction.

The **kidneys** revealed largely normal size and structure, corticomedullary definition and ratio (cortex 1/3 of medulla) were essentially maintained with some mild age-related loss of curvilinear patterns regarding the capsule and C/M junction. The cortices presented largely uniform texture with some increased echogenicity expected for his age patient. Medullary structure differed distinctly from that of the cortex and no evidence of pelvic dilation was present. Mineralization was present in the kidneys. The right kidney measured 4.06 cm. The left kidney measured 4.2 cm.

Adrenal Glands

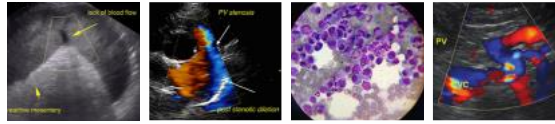
Both **adrenal glands** were visualized and recognized as having normal shape, size, position and echogenicity for this breed. The phrenic vasculature, glandular echogenicity and detail were unremarkable. Capsule, cortex, and medullary definition were normal for this age patient. The left adrenal gland measured 1.91 cm x 0.44 cm at the caudal pole and 0.43 cm at the cranial pole. The right adrenal gland measured 2.0 cm x 1.0 cm at the cranial pole and 0.44 cm at the caudal pole.

Spleen

The **spleen** presented a smooth homogeneous parenchyma hyperechoic to liver and renal cortical parenchyma. The capsule was smooth without noticeable expansion or deviation from within the spleen or adjacent pathology. The splenic vasculature demonstrated normal volume without signs of congestion or thrombosis. No sonographic evidence of acute or chronic inflammatory, neoplastic, or infarctual changes were noted.

Liver

The **liver** was mildly subnormal in size with slight coarse architecture. The gallbladder and common bile duct were unremarkable. No evidence of posthepatic obstruction. Portal vein to vena cava ratio was 1:1 (0.7 cm each).



PATIENT

Marley Johnson

SPECIES

Canine

BREED

Boston Terrier

SEX

Spayed Female

AGE

6 Years

WEIGHT

19 Pounds

Gastrointestinal

There was some residual chyme and gas noted in the **stomach**, yet not pathological. This is consistent with end post prandial presentation. Transit of chyme into the small intestine was normal. Curvilinear patterns were maintained throughout the GI tract. No evidence of pathology. Small and large intestine demonstrated normal luminal chyme and stool consistency respectively. No obstructive or overt infiltrative disease was noted. No associated abnormal lymphatic activity was noted.

Pancreas

The base and limbs of the **pancreas** were observed to be largely isoechoic to surrounding omental fat. Pancreatic duct and capsular contour were acceptably normal and parenchyma respected normal curvilinear patterns. No overt evidence of active inflammatory or neoplastic disease was noted.

ULTRASONOGRAPHIC FINDINGS

- Age-related nonspecific hepatic changes
- Age-related renal changes with mineralization
- Partially full stomach

INTERPRETATION OF THE FINDINGS & FURTHER RECOMMENDATIONS

No evidence of significant disease. Acute insult is suspected, given that no significant chronic changes are noted. Leptospirosis titers is warranted. Ultrasound guided FNA of the liver is indicated to define inflammatory cell type. Nutraceuticals indicated, and reassessment of the liver is warranted if liver enzymes are not resolved over the next 3-4 weeks. No evidence of neoplasia or surgical disease.

INTERPRETED BY

Eric Lindquist, DMV,
DABVP, Cert. IVUSS

HOSPITAL NAME

West Eugene AH

REFERRING VET

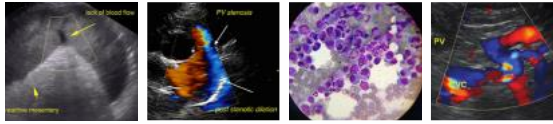
Dr. Sundholm

INVOICE NUMBER

23339

DATE

7/13/23



PATIENT

Marley Johnson

SPECIES

Canine

BREED

Boston Terrier

SEX

Spayed Female

AGE

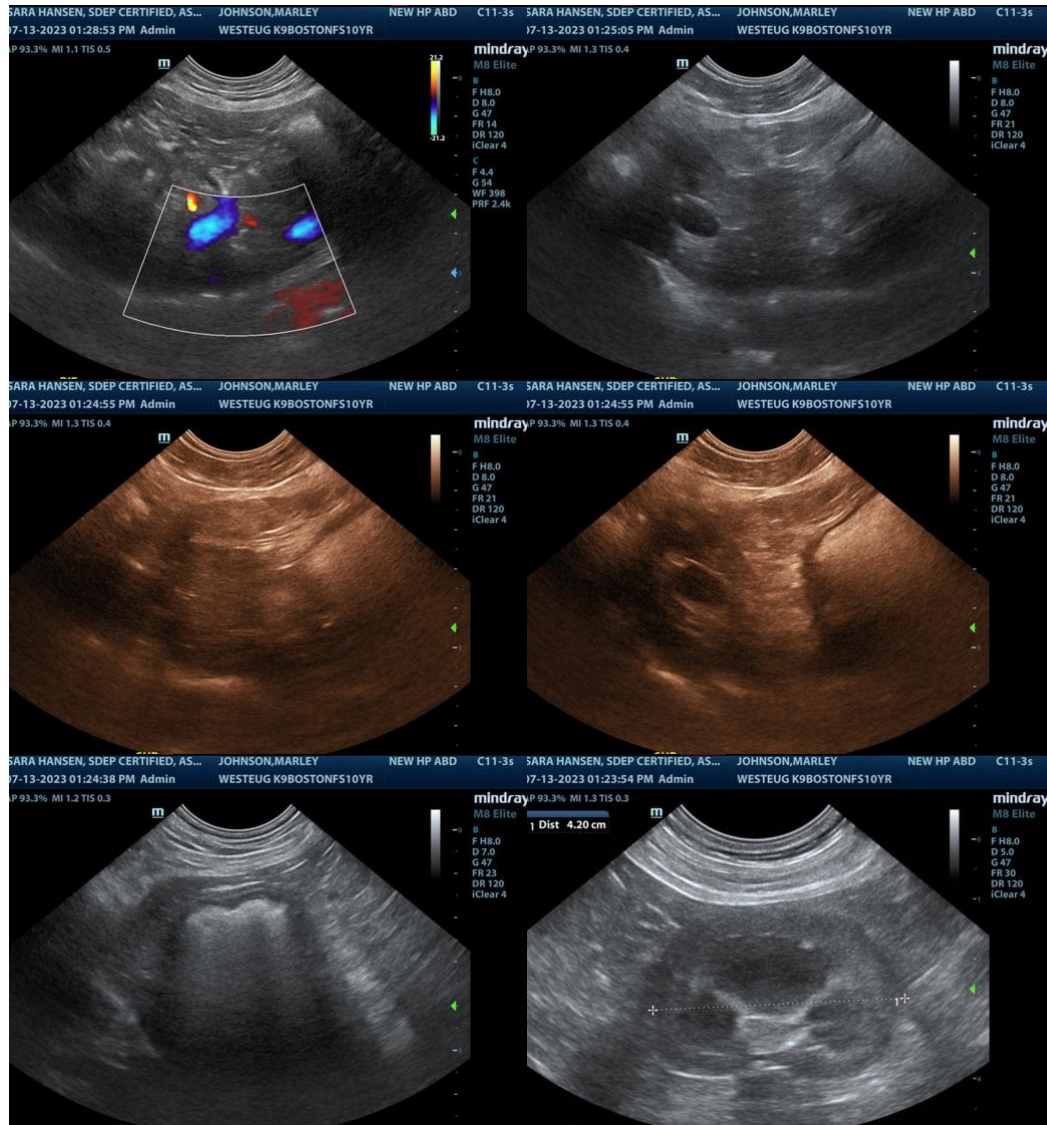
6 Years

WEIGHT

19 Pounds

INTERPRETED BY

Eric Lindquist, DMV,
DABVP, Cert. IVUSS



HOSPITAL NAME

West Eugene AH

REFERRING VET

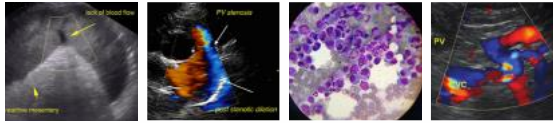
Dr. Sundholm

INVOICE NUMBER

23339

DATE

7/13/23



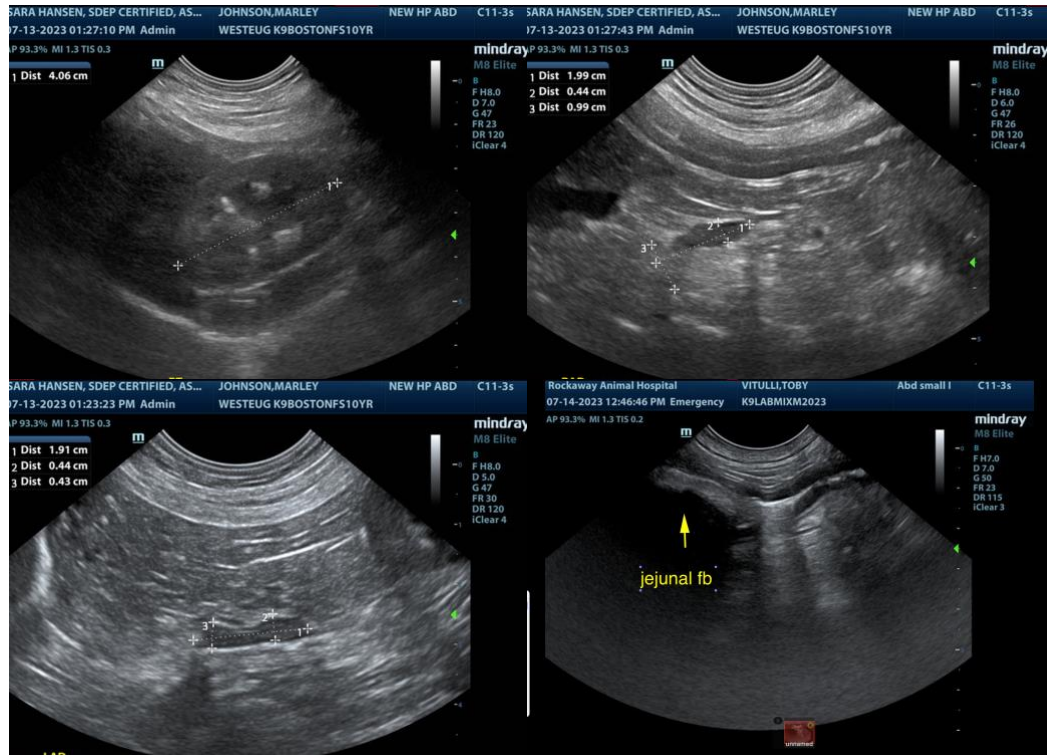
PATIENT
Marley Johnson

SPECIES
Canine

BREED
Boston Terrier

SEX
Spayed Female

AGE
6 Years



WEIGHT
19 Pounds

The information and recommendations provided are based on the images presented by the referring veterinarian. No evaluation can be communicated regarding pathology that was not visible in the image/video clips provided.

Thank you for this referral. If the clinical or image interpretation does not parallel your findings or if I can be of any further assistance please contact me.

INTERPRETED BY

Eric Lindquist, DMV, DABVP, Cert. IVUSS

Eric Lindquist, DMV, DABVP, Cert. IVUSS, CEO of SonoPath.com
info@SonoPath.com

HOSPITAL NAME

West Eugene AH

REFERRING VET

Dr. Sundholm

INVOICE NUMBER

23339

DATE

7/13/23