



PATIENT

Leo Scancarella

SPECIES

Feline

BREED

DSH

SEX

Neutered Male

AGE

11 Years

WEIGHT

11.9 Pounds

INTERPRETED BY

Eric Lindquist, DMV
DABVP, Cert. IVUSS

IMAGING PERFORMED BY

Kelly Vazquez

HOSPITAL NAME

Englewood Cliffs VH

REFERRING VET

Dr. Rachel Park

INVOICE

23343

DATE

7/13/23

PRESENTING CLINICAL SIGNS

History: 5/19/23 diagnosed with diabetes and pancreatitis. D.M. controlled with Bexacat 15mgs SID. Repeat Spec. fpl (5/19 12.8) on 6/30 is 32.3 ug/L. Current med: Bexacat 15 mgs SID.

Abnormal PE/Chem/CBC/UA Results: Elevated spec fpl.

ULTRASONOGRAPHIC EXAMINATION OF THE ABDOMEN

Urinary System

The **urinary bladder**, trigone, and pelvic urethra presented normal thicknesses and normal tone. The ureters were not visible which is normal. No uroliths or sediment were visualized and anechoic urine was present. No evidence of inflammatory or neoplastic changes were noted. Ureteral papillae were normal.

The **kidneys** revealed normal size and structure, corticomedullary definition and ratio for this age. The cortices presented largely uniform texture with normal echogenic relationship to liver and spleen. Medullary structure differed distinctly from the cortex and no evidence of pelvic dilation was present. The capsules were acceptably uniform without significant irregularities. The left kidney measured 4.5 cm.

Adrenal Glands

Both **adrenal glands** were visualized and recognized as having normal shape, size, position and echogenicity for this breed. The phrenic vasculature, glandular echogenicity and detail were unremarkable. Capsule, cortex, and medullary definition were normal for this age patient. The left adrenal gland measured 0.36 cm. The right adrenal gland measured 0.38 cm.

Spleen

The **spleen** presented a smooth homogeneous parenchyma hyperechoic to liver and renal cortical parenchyma. The capsule was smooth without noticeable expansion or deviation from within the spleen or adjacent pathology. The splenic vasculature demonstrated normal volume without signs of congestion or thrombosis. No sonographic evidence of acute or chronic inflammatory, neoplastic, or infarctual changes were noted. The spleen measured 1.0 cm.

Liver

The **liver** images submitted revealed subjectively normal liver size, contour, and structure. Parenchymal echogenicity was naturally coarse and hypoechoic to the spleen. Vascular and biliary tracts were of normal volume with no evidence of congestion. The gallbladder presented acceptably thin walls with primarily anechoic content. The cystic and common bile ducts were normal. No pathological hepatic lymphadenopathy was evident. No overt structural evidence of inflammatory, infiltrative or regenerative pathology was evident.

Gastrointestinal

Examination of the **gastrointestinal tract** revealed a stomach and intestine free of stasis, of normal wall thickness, acceptable curvilinear mural detail, and peristaltic activity. Small and large intestine demonstrated normal luminal chyme and stool consistency respectively. No obstructive or overt infiltrative disease was noted. No associated abnormal lymphatic activity was noted.

Pancreas



PATIENT

Leo Scancarella

The **pancreas** was heterogenous and irregular with hypoechoic nodules consistent with hyperplasia. A history of pancreatitis is likely playing a role in this patient. The left limb measured 0.79 cm and 0.72 cm on the right limb.

SPECIES

Feline

ULTRASONOGRAPHIC FINDINGS

- Pancreatic remodeling, potential low-grade inflammation.
- Unremarkable abdomen otherwise.

BREED

DSH

INTERPRETATION OF THE FINDINGS & FURTHER RECOMMENDATIONS

Left subxiphoid palpation and palpation cranial to the left kidney is warranted to assess for any discomfort. Diet change to hydrolyzed diabetic friendly diet may prove effective in this patient theoretically, as reactive pancreatic pathology may be an issue.

SEX

Neutered Male

Potential Causes of Diabetic Dysregulation

This is a suggestive checkoff list when faced with an unregulated diabetic patient:

AGE

11 Years

UTI

WEIGHT

11.9 Pounds

Dietary indiscretion/intolerance

Pancreatitis

Hyperthyroidism/hypothyroidism

Exogenous steroids (including topical eye meds)

INTERPRETED BY

Eric Lindquist, DMV
DABVP, Cert. IVUSS

Cushing's

Acromegaly

Owner compliance

IMAGING

PERFORMED BY

Kelly Vazquez

Insulin quality issues

Antibodies to insulin

Underlying Neoplasia

HOSPITAL NAME

Englewood Cliffs VH

REFERRING VET

Dr. Rachel Park

INVOICE

23343

DATE

7/13/23



PATIENT

Leo Scancarella

SPECIES

Feline

BREED

DSH

SEX

Neutered Male

AGE

11 Years

WEIGHT

11.9 Pounds

INTERPRETED BY

Eric Lindquist, DMV
DABVP, Cert. IVUSS

IMAGING PERFORMED BY

Kelly Vazquez

HOSPITAL NAME

Englewood Cliffs VH

REFERRING VET

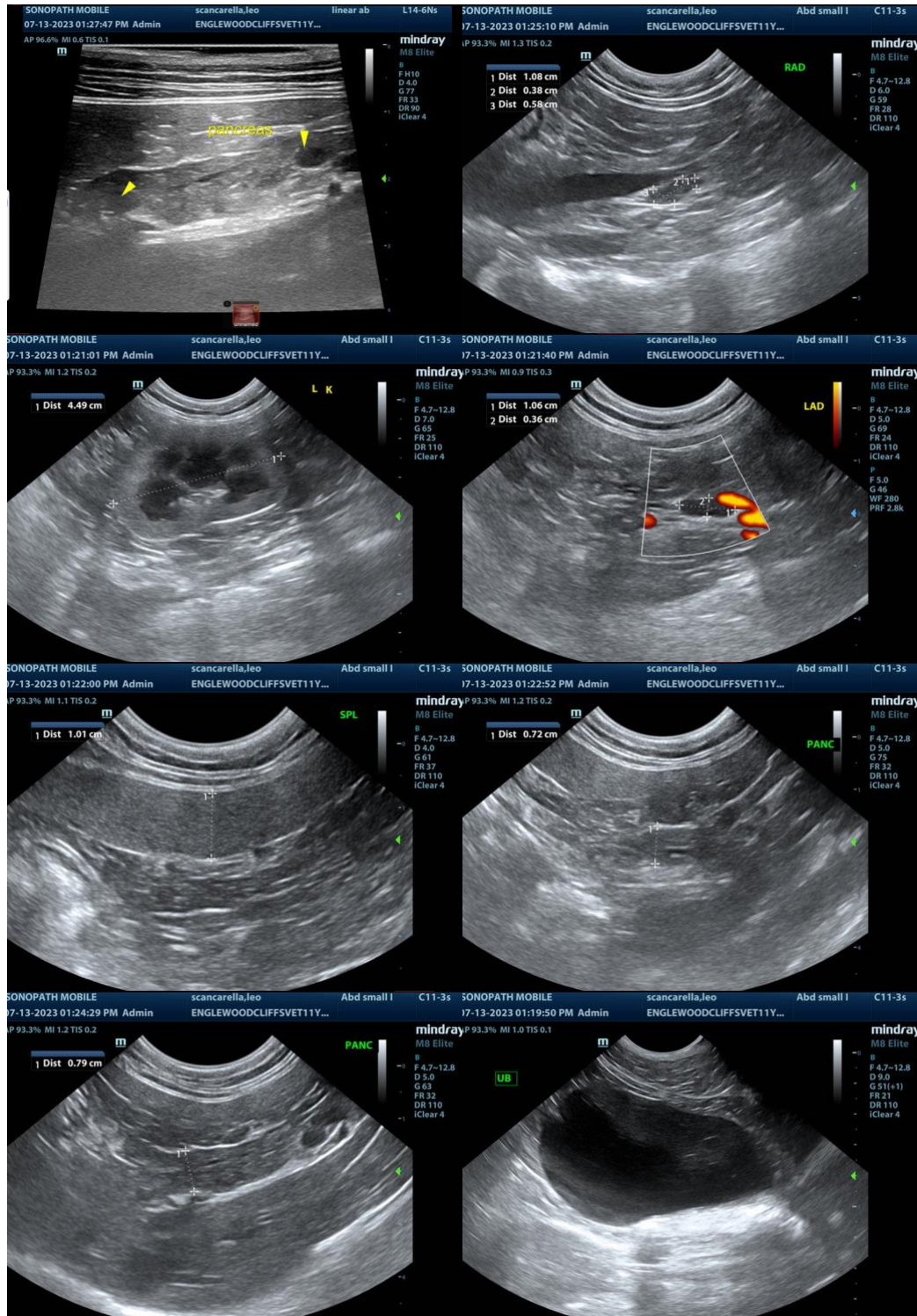
Dr. Rachel Park

INVOICE

23343

DATE

7/13/23



The information and recommendations provided are based on the images presented by the referring veterinarian. No evaluation can be communicated regarding pathology that was not visible in the image/video clips provided.



PATIENT

Leo Scancarella

Thank you for this referral. If the clinical or image interpretation does not parallel your findings or if I can be of any further assistance please contact me.

SPECIES

Feline

Eric Lindquist, DMV, DABVP, Cert. IVUSS, CEO of SonoPath.com
info@SonoPath.com

BREED

DSH

SEX

Neutered Male

AGE

11 Years

WEIGHT

11.9 Pounds

INTERPRETED BY

Eric Lindquist, DMV
DABVP, Cert. IVUSS

**IMAGING
PERFORMED BY**

Kelly Vazquez

HOSPITAL NAME

Englewood Cliffs VH

REFERRING VET

Dr. Rachel Park

INVOICE

23343

DATE

7/13/23